



## PATIENT

Prince Hansen

## SPECIES

Canine

## BREED

Chihuahua

## SEX

Neutered Male

## AGE

12 years 3 mos

## WEIGHT

10 lbs

## INTERPRETED BY

Alicia Angosto  
Guerrero, DMV,  
PgDip, MSc.

## IMAGING PERFORMED BY

Melissa Rosen

## HOSPITAL NAME

South Bellmore  
Vet Group

## REFERRING VET

Melissa Rosen

## INVOICE

22911

## DATE

4-23-26

## PRESENTING CLINICAL SIGNS

History: presented on 4/20: last 3 Sundays starting Easter Sunday patient has been off with eating vomiting bile, had a little smear of red the first time, had a small amount of gelatinous reddish material yesterday (5-6mm). Not wanting to eat until later in the day. This past weekend he had the dog walker come and she might have given him more treats than normal, but that doesn't explain the other two days. No recent changes in food or anything else. No c/s, stool normal at this time. Labs stable from last time, mild ALP elevation. Gave Cerenia In-Hosp. Went Home With Sucralfate X 3 Days And Omeprazole

Presented again today: diarrhea, no blood, ate last yesterday morning, hasn't vomited since being seen the other day

Abnormal PE/Chem/CBC/UA Results: hx mmvd stage b1, last echo 9/2025 ALP 223 om 4/20 ALP normal today mild dehydration chest rads pending

## ULTRASONOGRAPHIC EXAMINATION OF THE ABDOMEN

### Urinary System

The urinary bladder is adequately distended. The bladder wall is thin and smooth. The luminal contents are anechoic. The bladder neck and proximal urethra have a normal appearance. No uroliths or ultrasonographic evidence of inflammatory or proliferative/neoplastic changes are identified.

The left kidney measures 3.49×1.89 cm, with a cortical thickness of 0.35 cm in the sagittal plane. The right kidney measures 3.34×2.10 cm, with a cortical thickness of 0.37 cm in the sagittal plane. Both kidneys are normal in shape and size for a dog of this size (typical length ~3.0–4.5 cm). The cortex is isoechoic relative to the liver. The corticomedullary ratio is within normal limits, and corticomedullary definition is preserved. No pyelectasia, nephrolithiasis, or hydronephrosis is identified. Color Doppler demonstrates a normal vascular pattern.

### Prostate

The prostate measures 1.06×0.81 cm, is hypoechoic and homogeneous, compatible with prostatic atrophy secondary to castration.

### Adrenal Glands

Both adrenal glands show normal shape and echogenicity. Dorsoventral diameters measured in the sagittal plane: The left adrenal gland measures 0.42 cm at the cranial pole and 0.50 cm at the caudal pole. The right adrenal gland measures 0.55 cm at the cranial pole and 0.45 cm at the caudal pole.

### Spleen

Splenic thickness is 0.98 cm. The parenchyma demonstrates normal echogenicity and fine homogeneous echotexture without focal parenchymal abnormalities. The splenic capsule is smooth and regular.

### Liver

The liver is subjectively normal in size, with sharp edges and a regular contour. The liver parenchyma looks uniform and isoechoic compared to the falciform fat, with a normal echotexture. No hepatic lymphadenopathy is observed.

### Gallbladder

The gallbladder lumen is normally distended. The wall is thin and the contents are primarily anechoic with a small amount of biliary sludge. No evident dilation of the cystic duct or common bile duct is observed.



## PATIENT

Prince Hansen

## SPECIES

Canine

## BREED

Chihuahua

## SEX

Neutered Male

## AGE

12 years 3 mos

## WEIGHT

10 lbs

## INTERPRETED BY

Alicia Angosto  
Guerrero, DMV,  
PgDip, MSc.

## IMAGING PERFORMED BY

Melissa Rosen

## HOSPITAL NAME

South Bellmore  
Vet Group

## REFERRING VET

Melissa Rosen

## INVOICE

22911

## DATE

4-23-26

### Gastrointestinal

The stomach is empty with a predominantly fluid pattern. Gastric wall thickness is increased at 5.45 mm, with preserved wall layering (mucosa 1.88 mm, submucosa 0.60 mm, muscularis 0.99 mm). The pylorus measures 7.09 mm. Within the pyloric region, multiple small, cuboid intraluminal structures consistent with food material or treats are observed; these are mobile and do not cause pyloric obstruction.

Duodenum: 3.41 mm, within normal limits, with normal layering and no evidence of mucosal abnormalities or lacteal dilation.

Jejunum: 3.30 mm total thickness (mucosa 2.24 mm, submucosa 0.56 mm, muscularis 0.27 mm), within normal limits with preserved layering.

Colon wall thickness is 1.34 mm, within normal limits; the lumen is largely empty and collapsed.

### Pancreas

The evaluated pancreatic areas do not show evidence of overt inflammation or neoplastic disease.

### Free Abdomen

No sonographic evidence of abdominal effusion, peritonitis, or lymphadenomegaly is identified. The iliac trifurcation is normal.

## PRIMARY FINDINGS

- Diffuse gastric wall thickening with preserved layering.

## INTERPRETATION OF THE FINDINGS & FURTHER RECOMMENDATIONS

The primary finding is moderate, diffuse gastric wall thickening (5.45 mm) with preserved wall layering. In dogs, normal gastric wall thickness is generally  $\leq 3-5$  mm depending on distension, therefore this degree of thickening is mildly to moderately increased and clinically relevant.

The preserved layering and lack of focal mass lesions make infiltrative neoplasia unlikely; however, the findings are not specific and may be seen with a range of conditions including acute gastritis (dietary indiscretion), chronic inflammatory disease (including lymphoplasmacytic gastritis) or less commonly infectious etiologies (*Helicobacter* spp.). The presence of luminal fluid and recent ingesta further supports active gastric irritation.

The remainder of the gastrointestinal tract is within normal limits, and there are no ultrasonographic changes to support pancreatitis, although mild pancreatic disease cannot be completely excluded based on ultrasound alone.

Overall, this is most consistent with clinically significant gastric disease, likely inflammatory, with acute and chronic etiologies remaining differentials depending on clinical progression.

### Recommendations

- Supportive therapy.
- If clinical signs persist or recur, further evaluation of the stomach is warranted, including endoscopy with biopsies to characterize potential chronic or inflammatory gastric disease.
- Assessment with canine pancreatic lipase (cPLI) may be considered if there is ongoing concern for pancreatic involvement despite unremarkable ultrasonographic findings.

Final diagnostic and therapeutic decisions should be made by the attending veterinarian, who can best integrate these findings with the patient's clinical status.



### PATIENT

Prince Hansen

### SPECIES

Canine

### BREED

Chihuahua

### SEX

Neutered Male

### AGE

12 years 3 mos

### WEIGHT

10 lbs

### INTERPRETED BY

Alicia Angosto  
Guerrero, DMV,  
PgDip, MSc.

### IMAGING PERFORMED BY

Melissa Rosen

### HOSPITAL NAME

South Bellmore  
Vet Group

### REFERRING VET

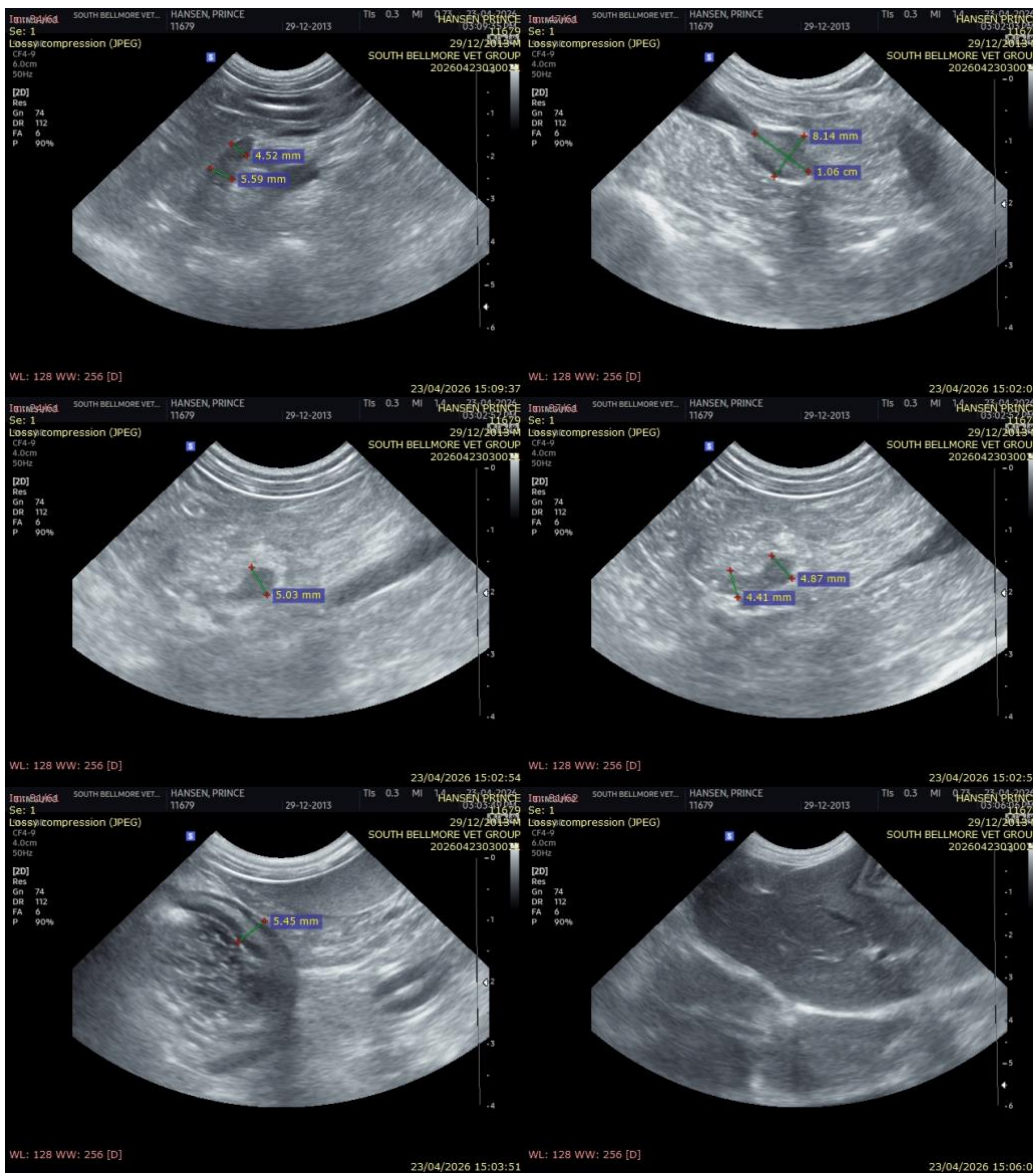
Melissa Rosen

### INVOICE

22911

### DATE

4-23-26





**PATIENT**

Prince Hansen

**SPECIES**

Canine

**BREED**

Chihuahua

**SEX**

Neutered Male

**AGE**

12 years 3 mos

**WEIGHT**

10 lbs

**INTERPRETED BY**

Alicia Angosto Guerrero, DMV, PgDip, MSc.

**IMAGING PERFORMED BY**

Melissa Rosen

**HOSPITAL NAME**

South Bellmore Vet Group

**REFERRING VET**

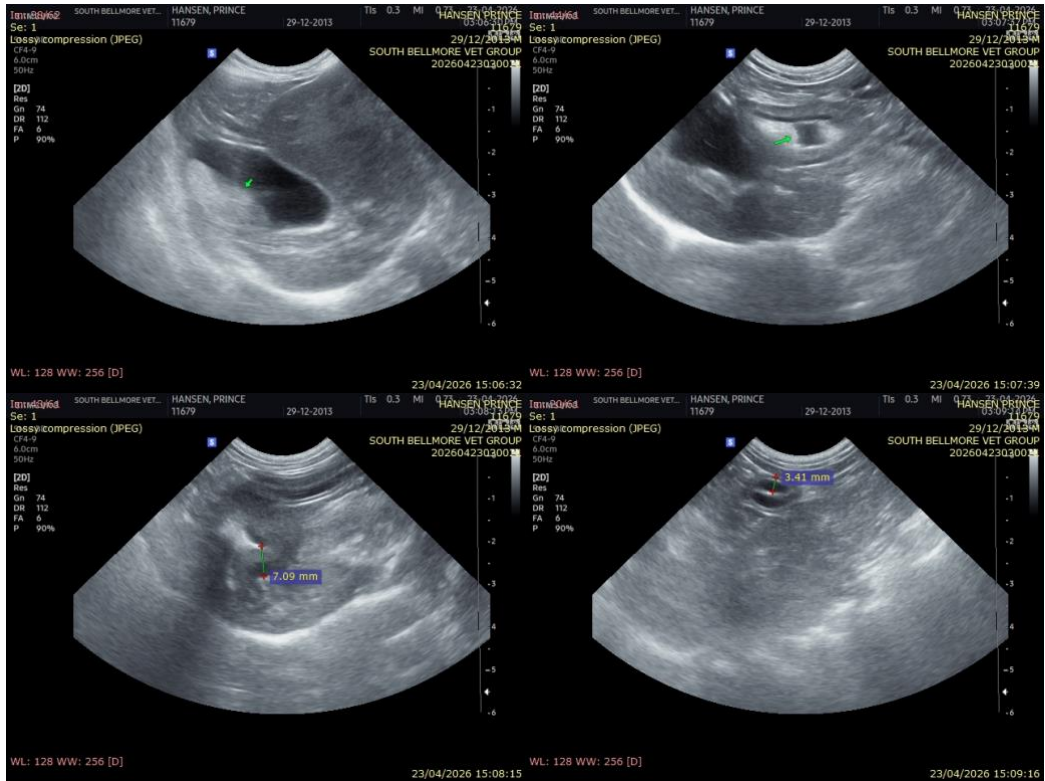
Melissa Rosen

**INVOICE**

22911

**DATE**

4-23-26



The information and recommendations provided are based on the images presented by the referring veterinarian/sonographer. No evaluation can be communicated regarding pathology that was not visible in the image/video clips provided.

Thank you for this referral. If the clinical or image interpretation does not parallel your findings or if I can be of any further assistance please contact me.

Alicia Angosto Guerrero, DMV, PgDip, MSc.  
[info@SonoPath.com](mailto:info@SonoPath.com)