



PATIENT

Harlem Halloran

SPECIES

Feline

BREED

Domestic Longhair

SEX

Spayed female

AGE

16 years

WEIGHT

9.37 lbs

INTERPRETED BY

Alicia Angosto
Guerrero, DMV,
PgDip, MSc.

IMAGING PERFORMED BY

Arielle Roldan, CVT

HOSPITAL NAME

Milford AH

REFERRING VET

Dr. Ascione

INVOICE

74755

DATE

4/22/26

PRESENTING CLINICAL SIGNS

History: Pt had echo last month - normal, started on hyperthyroid medications. Owner came in yesterday for t4 recheck, still high and patient is jaundiced. Recommended abd u/s and liver FNA - sent to pathology today pending results.

Abnormal PE/Chem/CBC/UA Results: TB 6.1 0.0 - 0.9 mg/dL HIGH ALP 137 14 - 111 U/L HIGH TC 357.96 64.68 - 223.68 mg/dL HIGH T4 7.10 0.5 - 8 ug/dL High (hyperthyroidism) SDMA 23.0 10 - 100 ug/dL Abnormal

ULTRASONOGRAPHIC EXAMINATION OF THE ABDOMEN

Urinary System

The urinary bladder is adequately distended. The wall is thin and smooth. The urine is anechoic. The bladder neck and proximal urethra appear normal. No uroliths are identified, and there is no ultrasonographic evidence of inflammatory or neoplastic disease.

The left kidney is normal in shape and size, measuring 3.12×1.87 cm, with a cortical thickness of 0.23 cm in the sagittal plane. The cortex is isoechoic relative to the hepatic parenchyma. The corticomedullary ratio is normal and corticomedullary distinction is preserved. Small punctate hyperechoic foci are noted within the medulla, compatible with mild medullary mineralization (nephrocalcinosis), which may be age-related. There is no evidence of pyelectasia, nephrolithiasis, or hydronephrosis.

The right kidney is normal in shape and size, measuring 3.73×2.20 cm, with a cortical thickness of 0.25 cm in the sagittal plane. The cortex is mildly hyperechoic relative to the liver. The corticomedullary ratio is normal and corticomedullary distinction is preserved. There is no evidence of pyelectasia, nephrolithiasis, or hydronephrosis.

Adrenal Glands

No confidently visualized.

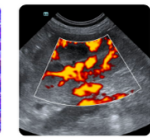
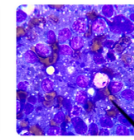
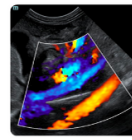
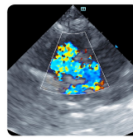
Spleen

Splenic thickness is 0.79 cm. The parenchyma demonstrates normal echogenicity and fine homogeneous echotexture without focal parenchymal abnormalities. The splenic capsule is smooth and regular.

Liver

The liver is subjectively normal in size, with sharp edges and a regular contour. The liver parenchyma looks uniform and isoechoic compared to the falciform fat, with a normal echotexture. No hepatic lymphadenopathy is observed.

The gallbladder is adequately distended. The wall is thin and regular. The contents are anechoic. The common bile duct measures 2.55 mm, which is within normal limits for a feline patient (typically ≤3 mm).



PATIENT

Harlem Halloran

SPECIES

Feline

BREED

Domestic Longhair

SEX

Spayed female

AGE

16 years

WEIGHT

9.37 lbs

INTERPRETED BY

Alicia Angosto
Guerrero, DMV,
PgDip, MSc.

IMAGING PERFORMED BY

Arielle Roldan, CVT

HOSPITAL NAME

Milford AH

REFERRING VET

Dr. Ascione

INVOICE

74755

DATE

4/22/26

Gastrointestinal

The stomach is empty and folded, with mural thickness of 1.96 mm and preserved wall layering, within normal limits for a feline patient. The pylorus measures 3.12 mm. The duodenum measures 1.52 mm. The jejunum measures 2.41 mm, with mucosa 1.20 mm, submucosa 0.59 mm, and muscularis propria 0.44 mm. The ileum measures 1.65 mm, with mucosa 0.58 mm, submucosa 0.55 mm, and muscularis propria 0.49 mm. Wall layering is preserved throughout all segments. The ileocecal junction was not visualized. Colon: the transverse colon measures 0.74 mm, with formed fecal material present; the descending colon measures 1.32 mm with small amounts of formed feces in the lumen.

Pancreas

The evaluated pancreatic areas do not show evidence of overt inflammation or neoplastic disease.

Free Abdomen

No sonographic evidence of abdominal effusion, peritonitis, or lymphadenomegaly is identified. The iliac trifurcation is normal.

PRIMARY FINDINGS

- Mild renal cortical hyperechogenicity (right kidney)
- Mild medullary mineralization (left kidney)

INTERPRETATION OF THE FINDINGS & FURTHER RECOMMENDATIONS

Abdominal ultrasound is within normal limits and does not identify a structural cause for the patient's hyperbilirubinemia or icterus.

The liver parenchyma and biliary system appear unremarkable, with a normal common bile duct diameter (2.55 mm), and no ultrasonographic evidence of biliary obstruction or significant hepatobiliary structural disease.

In this context, marked hyperbilirubinemia with minimal ultrasonographic abnormalities suggests a functional or microscopic hepatobiliary disorder, which may include inflammatory hepatobiliary disease (cholangitis) or, less commonly, drug-associated hepatopathy. These processes may not produce detectable changes on ultrasound, particularly in early or diffuse disease.

Hyperthyroidism may contribute to mild hepatocellular enzyme elevations but does not adequately explain the degree of hyperbilirubinemia observed, supporting the presence of concurrent hepatobiliary disease.

Incidental renal changes (mild cortical hyperechogenicity and medullary mineralization) are noted and may be age-related or associated with early chronic renal change, correlating with the elevated SDMA.



PATIENT

Harlem Halloran

SPECIES

Feline

BREED

Domestic Longhair

SEX

Spayed female

AGE

16 years

WEIGHT

9.37 lbs

INTERPRETED BY

Alicia Angosto
Guerrero, DMV,
PgDip, MSc.

IMAGING PERFORMED BY

Arielle Roldan, CVT

HOSPITAL NAME

Milford AH

REFERRING VET

Dr. Ascione

INVOICE

74755

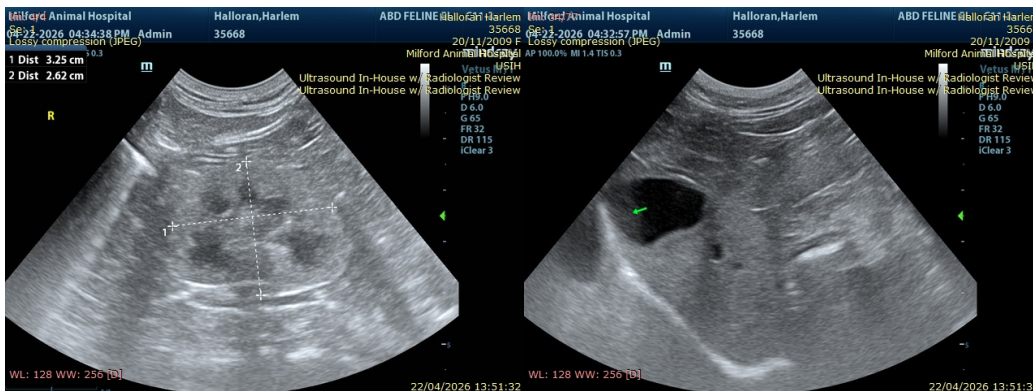
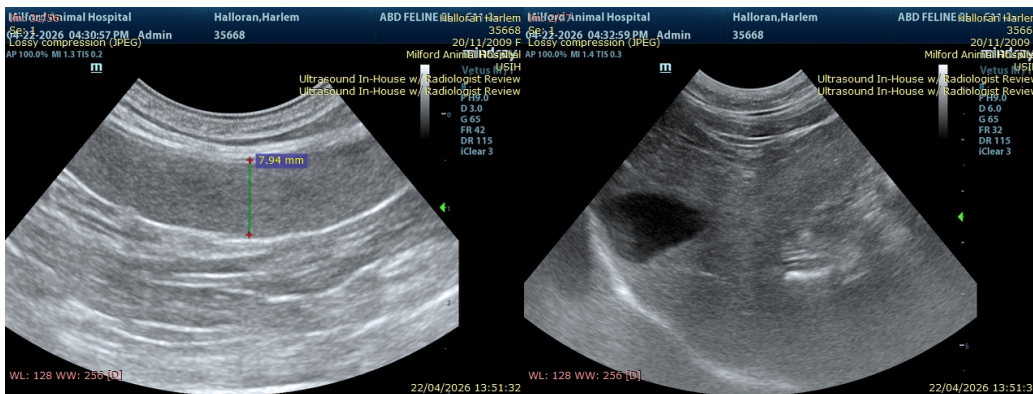
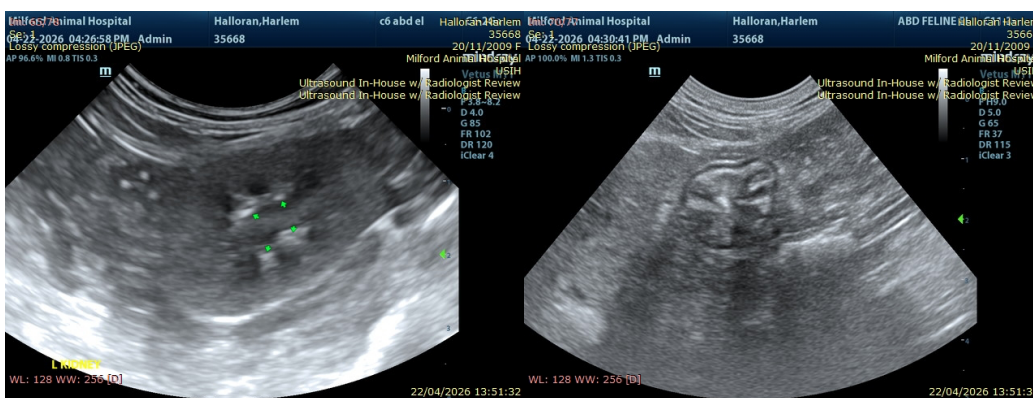DATE

4/22/26

Recommendations

- Correlate with pending liver cytology for further characterization of hepatobiliary disease.
- Consider empirical treatment for inflammatory hepatobiliary disease if cytology is inconclusive.
- Review current anti-thyroid medication as a potential contributing factor to hepatopathy.
- Monitor bilirubin and liver enzymes to assess progression or response to therapy.

Final diagnostic and therapeutic decisions should be made by the attending veterinarian, who can best integrate these findings with the patient's clinical status.





PATIENT

Harlem Halloran

SPECIES

Feline

BREED

Domestic Longhair

SEX

Spayed female

AGE

16 years

WEIGHT

9.37 lbs

INTERPRETED BY

Alicia Angosto Guerrero, DMV,
PgDip, MSc.

IMAGING PERFORMED BY

Arielle Roldan, CVT

HOSPITAL NAME

Milford AH

REFERRING VET

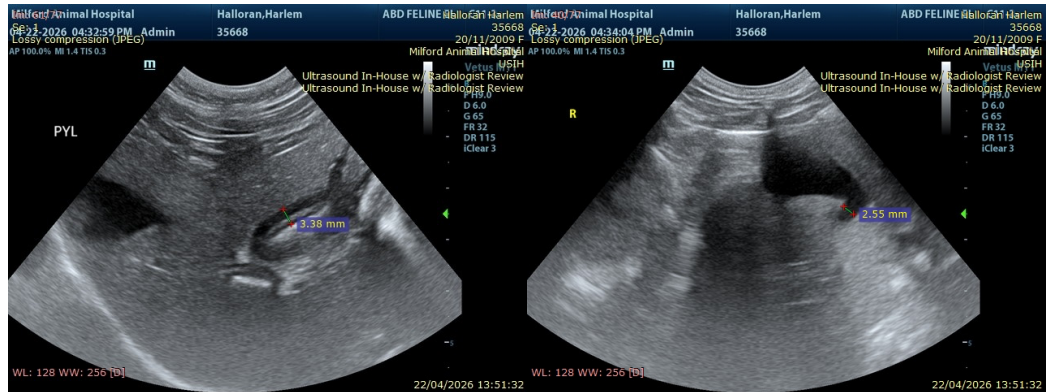
Dr. Ascione

INVOICE

74755

DATE

4/22/26



The information and recommendations provided are based on the images presented by the referring veterinarian/sonographer. No evaluation can be communicated regarding pathology that was not visible in the image/video clips provided.

Thank you for this referral. If the clinical or image interpretation does not parallel your findings or if I can be of any further assistance please contact me.

Alicia Angosto Guerrero, DMV, PgDip, MSc.

info@SonoPath.com