



PATIENT

Roxie Burt

SPECIES

Canine

BREED

Chihuahua Mix

SEX

Spayed female

AGE

7 years

WEIGHT

17.6 lbs

INTERPRETED BY

Alicia Angosto
Guerrero, DMV,
PgDip, MSc.

IMAGING PERFORMED BY

Desen Ertunc, DVM

HOSPITAL NAME

Humboldt Veterinary
Medical Group

REFERRING VET

Dr. Renner

INVOICE

74689

DATE

4/21/26

PRESENTING CLINICAL SIGNS

History of IVDD. Elevated liver values found on lab work; persistently elevated when rechecked.
Abnormal PE/Chem/CBC/UA Results: *Abnormal PE: Periodontal disease, medial luxating patella.
*Abnormal CBC/Chem/UA/rads (& date obtained): 2/10/26 - CBC/CHEM: CI 127 (109-122), ALT 223 (10-125) 4/3/26 - CHEM: Alb 4.1 (2.3-4.0), ALT 289 (10-125), ALP 216 (23-212) JR

ULTRASONOGRAPHIC EXAMINATION OF THE ABDOMEN

Urinary System

The urinary bladder lumen is moderately distended, and the wall appears thin and smooth. The urine is anechoic. The bladder neck and proximal urethra have a normal appearance. No calculi or evidence of inflammatory or neoplastic changes are identified.

The left kidney is normal in shape and size, measuring 3.98×2.20 cm, with a cortical thickness of 0.38 cm in the sagittal plane.

The right kidney is normal in shape and size, measuring 4.03×2.00 cm, with a cortical thickness of 0.28 cm in the sagittal plane.

Both kidneys: The cortex is isoechoic relative to the hepatic parenchyma. The corticomedullary ratio is normal, and corticomedullary definition is preserved. There is no evidence of pyelectasia, nephrolithiasis, or hydronephrosis.

Adrenal Glands

Dorsoventral diameters measured in the sagittal plane: The left adrenal gland measures 0.66 cm at the cranial pole and 0.62 cm at the caudal pole. The right adrenal gland measures 0.52 cm at the cranial pole and 0.40 cm at the caudal pole.

Spleen

Splenic thickness is 1.41 cm. The splenic parenchyma demonstrates normal echogenicity and a fine homogeneous echotexture. A few small hyperechoic nodules are present, the largest measuring 4.64×7.25 mm, consistent with benign changes such as myelolipomas. The splenic capsule is smooth and regular. Splenic vasculature appears normal.

Liver

The liver is subjectively normal in size, with sharp edges and a regular contour. The liver parenchyma looks uniform and isoechoic compared to the falciform fat, with a normal echotexture. No hepatic lymphadenopathy is observed.



PATIENT

Roxie Burt

SPECIES

Canine

BREED

Chihuahua Mix

SEX

Spayed female

AGE

7 years

WEIGHT

17.6 lbs

INTERPRETED BY

Alicia Angosto
Guerrero, DMV,
PgDip, MSc.

IMAGING PERFORMED BY

Desen Ertunc, DVM

HOSPITAL NAME

Humboldt Veterinary
Medical Group

REFERRING VET

Dr. Renner

INVOICE

74689

DATE

4/21/26

The gallbladder is moderately distended. The wall shows changes consistent with mucosal (mucinous gland) hyperplasia. The lumen contains a moderate amount of organized biliary sludge with a few hyperechoic striations. No dilation of the cystic duct or common bile duct is observed.

Gastrointestinal

The stomach is empty and folded, with a mural thickness of 1.74 mm and preserved wall layering. The pylorus measures 3.94 mm. The duodenum measures 2.96 mm, and the jejunum measures 3.19 mm, both within normal limits (<5 mm), with preserved wall layering. No signs of inflammation, ileus, or foreign material are identified.

Pancreas

The evaluated pancreatic areas do not show evidence of overt inflammation or neoplastic disease.

Free Abdomen

No sonographic evidence of abdominal effusion, peritonitis, or lymphadenomegaly is identified. The iliac trifurcation is normal.

PRIMARY FINDINGS

- Gallbladder mucosal hyperplasia with moderate organized biliary sludge
- Mild left adrenal rounding (globose shape)

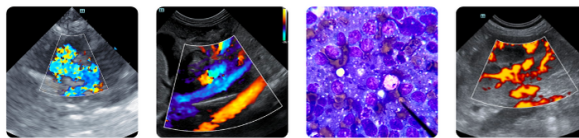
SECONDARY FINDINGS

- Small splenic myelolipomas (incidental)

INTERPRETATION OF THE FINDINGS & FURTHER RECOMMENDATIONS

The gallbladder wall changes are consistent with mucosal hyperplasia accompanied by organized biliary sludge. This pattern may be associated with chronic biliary stasis and could represent early gallbladder mucocele formation (grade II), although there is no evidence of biliary obstruction at this time. The liver appears structurally normal on ultrasound, with no evidence of diffuse parenchymal disease, nodularity, or mass lesions. These findings suggest that the mild to moderate ALT elevation is not associated with overt structural hepatic abnormalities. This may reflect a functional or early hepatocellular process, which can occur in the absence of detectable ultrasonographic changes. Clinical correlation, including medication history and laboratory trends, is recommended.

The left adrenal gland is mildly rounded and at the upper limits of normal size. This is a nonspecific finding and may represent normal variation or mild hyperplasia; however, there is no clear ultrasonographic evidence to support clinically significant adrenal disease. It should be noted that ultrasound cannot assess adrenal function.



PATIENT

Roxie Burt

SPECIES

Canine

BREED

Chihuahua Mix

SEX

Spayed female

AGE

7 years

WEIGHT

17.6 lbs

INTERPRETED BY

Alicia Angosto
Guerrero, DMV,
PgDip, MSc.

IMAGING PERFORMED BY

Desen Ertunc, DVM

HOSPITAL NAME

Humboldt Veterinary
Medical Group

REFERRING VET

Dr. Renner

INVOICE

74689

DATE

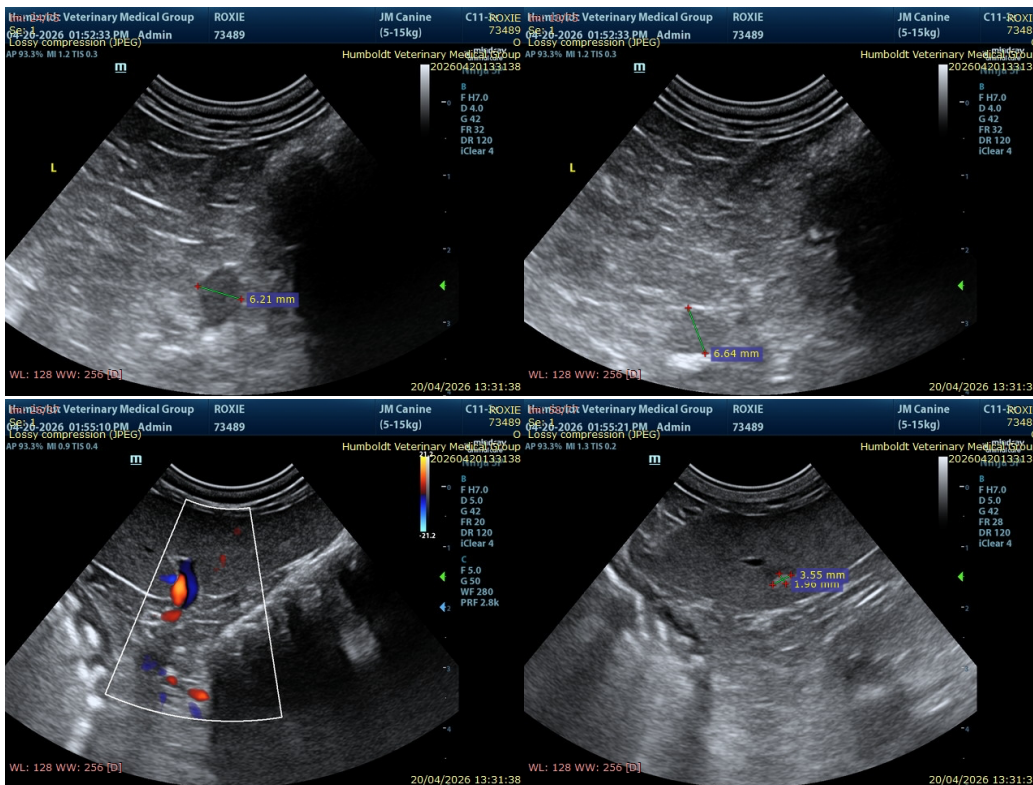
4/21/26

Splenic nodules are small and hyperechoic, most consistent with benign incidental lesions such as myelolipomas, which are common in dogs and are not considered clinically significant in this context.

Recommendations

- Consider serial monitoring of liver enzymes to assess progression or stability.
- Supportive management (hepatoprotectants) may be reasonable, although identifying an underlying cause remains important.
- Given the presence of biliary sludge and gallbladder wall changes consistent with mucosal hyperplasia, the use of a choleric agent such as ursodeoxycholic acid may be considered to support bile flow, provided there is no evidence of biliary obstruction.
- If liver enzyme elevations persist or worsen, further diagnostic investigation (including bile acids testing and/or liver biopsy) should be considered, as ultrasound may not detect early or diffuse hepatocellular disease
- Periodic ultrasound re-evaluation of the gallbladder may be considered to monitor for progression toward mucocele formation.

Final diagnostic and therapeutic decisions should be made by the attending veterinarian, who can best integrate these findings with the patient's clinical status.





PATIENT

Roxie Burt

SPECIES

Canine

BREED

Chihuahua Mix

SEX

Spayed female

AGE

7 years

WEIGHT

17.6 lbs

INTERPRETED BY

Alicia Angosto Guerrero, DMV, PgDip, MSc.

IMAGING PERFORMED BY

Desen Ertunc, DVM

HOSPITAL NAME

Humboldt Veterinary Medical Group

REFERRING VET

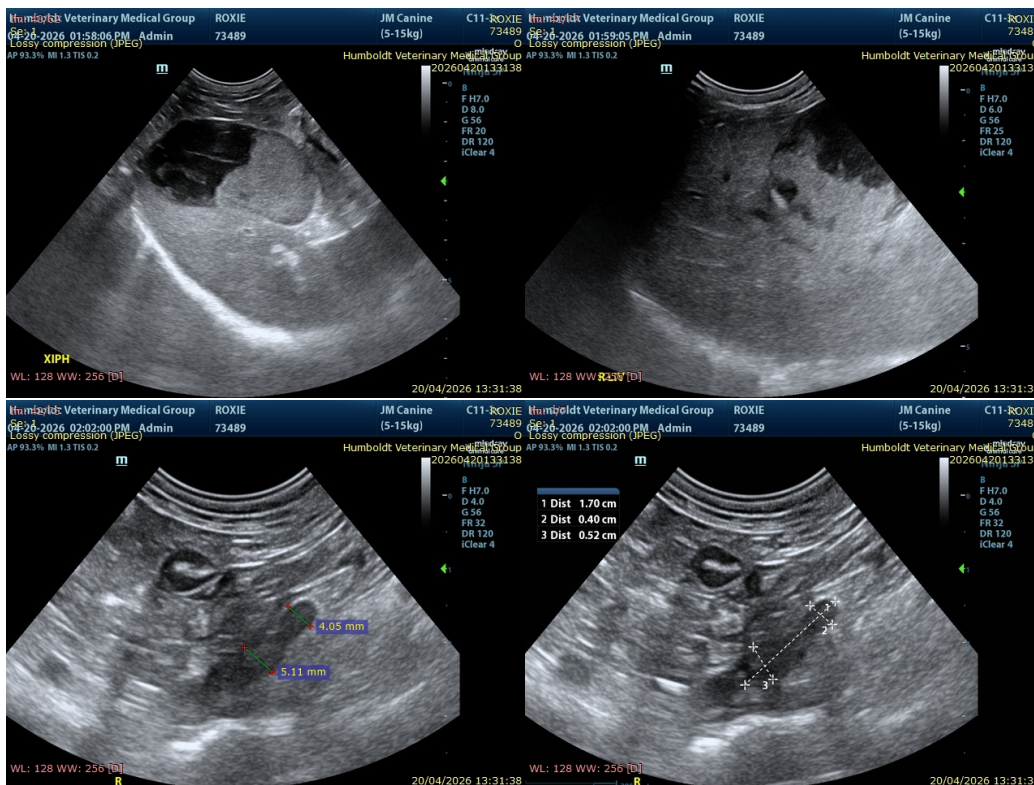
Dr. Renner

INVOICE

74689

DATE

4/21/26



The information and recommendations provided are based on the images presented by the referring veterinarian/sonographer. No evaluation can be communicated regarding pathology that was not visible in the image/video clips provided.

Thank you for this referral. If the clinical or image interpretation does not parallel your findings or if I can be of any further assistance please contact me.

Alicia Angosto Guerrero, DMV, PgDip, MSc.

info@SonoPath.com