



PATIENT

Mittens Wang

SPECIES

Feline

BREED

Domestic Shorthair

SEX

Neutered male

AGE

8 years

WEIGHT

13.1 lbs

INTERPRETED BY

Alicia Angosto
Guerrero, DMV,
PgDip, MSc.

IMAGING PERFORMED BY

Dr. Ammeraal

HOSPITAL NAME

Sova

REFERRING VET

Dr. Ammeraal

INVOICE

74622

DATE

4/20/26

PRESENTING CLINICAL SIGNS

History: Presenting for decreased appetite. Vomited about 7 days ago. None since Seemed to improve w supportive care a week ago- Cerenia/ SQ fluids/I/D food. Ate I/D for 2 days then stopped eating it.

Saturday returned- still not back to normal

Diarrhea over weekend. Was dispensed Clavacillin on Sat by other DVM

Lethargic and not interested in playing.

Abnormal PE/Chem/CBC/UA Results: BCS 7/9, WBC 35,000 /uL, Neutrophils 33,000/uL Chem normal Rads heterogenous luminal material noted in small intestine segments, could be causing gastroenteritis or passing FB

ULTRASONOGRAPHIC EXAMINATION OF THE ABDOMEN

Urinary System

The urinary bladder lumen is normally distended, and the wall appears thin and smooth. The urine is anechoic. The bladder neck and proximal urethra have a normal appearance. No calculi or evidence of inflammatory or neoplastic changes are identified.

The left kidney is normal in shape and size, measuring 4.01×2.60 cm, with a cortical thickness of 0.38 cm in the sagittal plane. The cortex is hyperechoic compared to the hepatic parenchyma. The corticomedullary ratio is normal, and corticomedullary definition is preserved. A mild medullary rim sign is present. There is no evidence of pyelectasia, nephrolithiasis, or hydronephrosis.

The right kidney is normal in shape and size, measuring 3.86×2.78 cm, with a cortical thickness of 0.54 cm in the sagittal plane. The cortex is hyperechoic compared to the hepatic parenchyma. The corticomedullary ratio is normal, and corticomedullary definition is preserved. There is no evidence of pyelectasia, nephrolithiasis, or hydronephrosis.

Adrenal Glands

Dorsoventral diameters measured in the sagittal plane: The left adrenal gland measures 0.35 cm at the cranial pole and 0.33 cm at the caudal pole. The right adrenal gland is not confidently visualized.

Spleen

Splenic thickness is 0.61 cm. The parenchyma demonstrates normal echogenicity and fine homogeneous echotexture without focal parenchymal abnormalities. The splenic capsule is smooth and regular.

Liver

The liver is subjectively normal in size, with sharp edges and a regular contour. The liver parenchyma looks uniform and isoechoic compared to the falciform fat, with a normal echotexture. No hepatic lymphadenopathy is observed.



PATIENT

Mittens Wang

SPECIES

Feline

BREED

Domestic Shorthair

SEX

Neutered male

AGE

8 years

WEIGHT

13.1 lbs

INTERPRETED BY

Alicia Angosto
Guerrero, DMV,
PgDip, MSc.

IMAGING PERFORMED BY

Dr. Ammeraal

HOSPITAL NAME

Sova

REFERRING VET

Dr. Ammeraal

INVOICE

74622

DATE

4/20/26

The gallbladder lumen is normally distended. The wall is thin and the contents are primarily anechoic with a small amount of biliary sludge. No evident dilation of the cystic duct or common bile duct is observed.

Gastrointestinal

The stomach is empty and folded, with preserved wall layering; mural thickness is not provided. The pylorus is not measured.

The duodenum measures 2.17 mm. The jejunum measures 2.31 mm, with mucosa 1.38 mm, submucosa 0.82 mm, and muscularis propria 0.53 mm; wall layering is preserved. The muscularis-to-mucosa ratio in the jejunum is approximately 0.38, which is within expected limits (<0.5–0.6 in cats).

The ileum measures 2.52 mm proximally and up to 4.72 mm distally. A focal region at the distal ileum/ileocecal junction shows marked wall thickening (5.35–5.78 mm) with loss of normal wall layering and an associated mass effect measuring 1.68 cm. The muscularis propria of the ileum is also markedly thickened (2.44 mm where measurable).

The colon: ascending colon wall thickness is increased (4.62 mm) with preserved layering. The descending colon measures 2.69 mm and contains small amounts of soft fecal material.

Pancreas

The evaluated pancreatic areas do not show evidence of overt inflammation or neoplastic disease.

Free Abdomen

Mild abdominal effusion is present. The mesenteric fat surrounding the ileocecal junction is increased in echogenicity.

No definite lymphadenomegaly is identified in the submitted images, although complete assessment is limited. The iliac trifurcation is normal.

PRIMARY FINDINGS

- Focal distal ileocecal mass (1.68 cm) with marked wall thickening (5.35–5.78 mm) and loss of wall layering.
- Marked muscularis thickening at the distal ileal region.
- Diffuse colonic wall thickening (ascending colon 4.62 mm) with preserved layering.

SECONDARY FINDINGS

- Bilateral renal cortical hyperechogenicity with mild medullary rim sign.
- Mild abdominal effusion and increased echogenicity of the mesenteric fat adjacent to the ileocecal junction.



PATIENT

Mittens Wang

SPECIES

Feline

BREED

Domestic Shorthair

SEX

Neutered male

AGE

8 years

WEIGHT

13.1 lbs

INTERPRETED BY

Alicia Angosto
Guerrero, DMV,
PgDip, MSc.

IMAGING PERFORMED BY

Dr. Ammeraal

HOSPITAL NAME

Sova

REFERRING VET

Dr. Ammeraal

INVOICE

74622

DATE

4/20/26

INTERPRETATION OF THE FINDINGS & FURTHER RECOMMENDATIONS

The dominant and clinically critical finding is a focal mass at the distal ileum/ileocecal junction, characterized by marked mural thickening, loss of normal wall layering, and regional mass effect. This ultrasonographic pattern is most consistent with infiltrative neoplasia, with intestinal lymphoma (including large cell lymphoma) being the leading differential in a cat, followed by carcinoma or less likely other neoplastic processes.

The loss of wall layering and focal nature of the lesion strongly argue against uncomplicated inflammatory bowel disease. While inflammatory conditions can cause thickening, they typically preserve layering and do not produce a discrete mass effect of this nature. The marked muscularis thickening locally further supports an infiltrative process rather than diffuse enteropathy. The jejunum shows a normal muscularis-to-mucosa ratio (~0.38), which does not support diffuse small cell lymphoma or generalized inflammatory bowel disease, indicating that the process is focal rather than diffuse.

The marked neutrophilic leukocytosis, mild abdominal effusion and increased echogenicity of the mesenteric fat adjacent to the ileocecal junction raises concern for secondary inflammation, necrosis, or early septic complication, particularly if there is mucosal compromise.

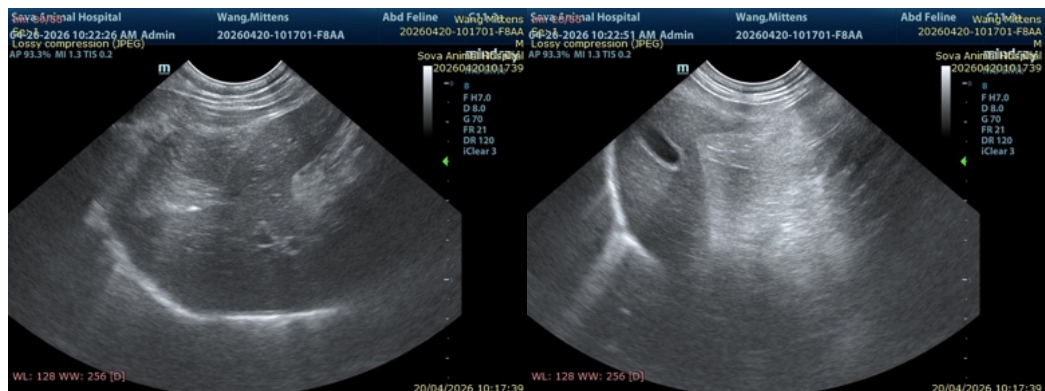
Renal changes are compatible with chronic or incidental renal change and are unlikely to be related to the current presentation.

Recommendations

Ultrasound-guided FNA of the ileocecal lesion could be considered, particularly if lymphoma is suspected. However, given the focal loss of wall layering and associated mesenteric inflammatory changes, there is concern for mural compromise. In this context, a small risk of leakage cannot be excluded.

Exploratory laparotomy with biopsy should be considered as an alternative diagnostic approach, particularly if clinical suspicion for a complicated or transmural process persists.

Final diagnostic and therapeutic decisions should be made by the attending veterinarian, who can best integrate these findings with the patient's clinical status.





PATIENT

Mittens Wang

SPECIES

Feline

BREED

Domestic Shorthair

SEX

Neutered male

AGE

8 years

WEIGHT

13.1 lbs

INTERPRETED BY

Alicia Angosto Guerrero, DMV, PgDip, MSc.

IMAGING PERFORMED BY

Dr. Ammeraal

HOSPITAL NAME

Sova

REFERRING VET

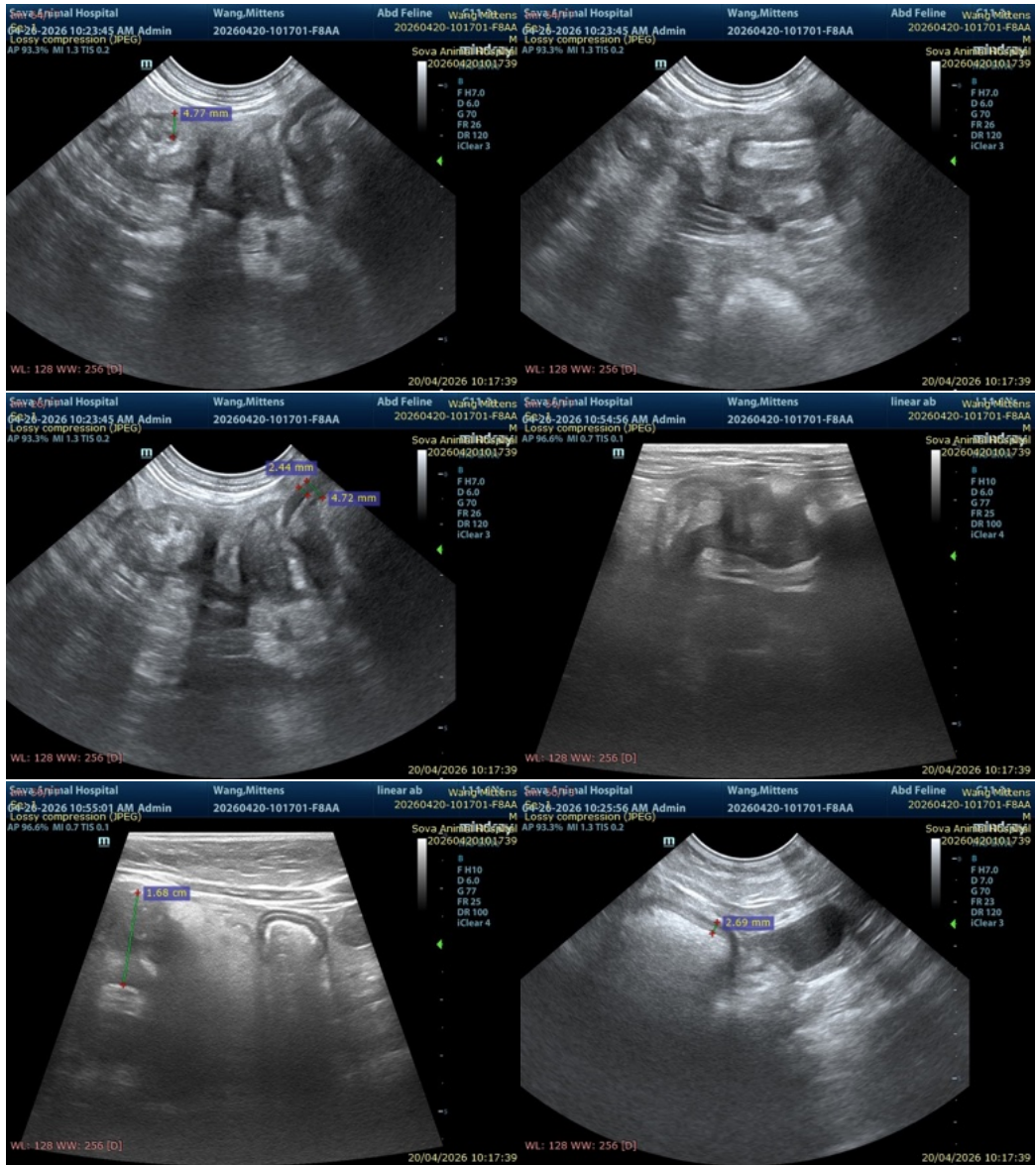
Dr. Ammeraal

INVOICE

74622

DATE

4/20/26



The information and recommendations provided are based on the images presented by the referring veterinarian/sonographer. No evaluation can be communicated regarding pathology that was not visible in the image/video clips provided.

Thank you for this referral. If the clinical or image interpretation does not parallel your findings or if I can be of any further assistance please contact me.

Alicia Angosto Guerrero, DMV, PgDip, MSc.

info@SonoPath.com