



PATIENT

Felix Haverkamp

SPECIES

Feline

BREED

Domestic Shorthair

SEX

Neutered male

AGE

13 years

WEIGHT

6.56 lbs

INTERPRETED BY

Alicia Angosto
Guerrero, DMV,
PgDip, MSc.

IMAGING PERFORMED BY

Dr. Arms

HOSPITAL NAME

Gilbertsville VH

REFERRING VET

Dr. Yiannis

INVOICE

74078

DATE

4/2/26

PRESENTING CLINICAL SIGNS

- FIV+
- Weight loss, constipation, progressive hyporexia
- anemia, neutropenia, thrombocytopenia
- hyperglobulinemia
- AXR- constipation, emaciated, LS degeneration, ileus, possible ST opacity caudal thorax (no CXR at that time) HCT 20, neut 1.9, plt 85, glob 6.4, K 3.3 CXR today after AUS - ST opacity right hemithorax

ULTRASONOGRAPHIC EXAMINATION OF THE ABDOMEN

Urinary System

The urinary bladder is normally distended. The bladder wall is thin, smooth, and regular. The luminal contents are anechoic. Normal appearance of the bladder neck and proximal urethra. No evidence of urolithiasis or inflammatory or proliferative changes is identified.

The left kidney measures 4.51×2.84 cm in the sagittal plane. Cortical thickness is 0.49 cm. The cortex is hyperechoic compared to the hepatic parenchyma. The corticomedullary ratio is within normal limits, and corticomedullary definition is preserved. There is no evidence of pyelectasia, nephrolithiasis, or hydronephrosis. Color Doppler demonstrates a normal vascular pattern.

The right kidney measures 4.70×2.25 cm in the sagittal plane. Cortical thickness is 0.46 cm. The cortex is hyperechoic compared to the hepatic parenchyma. The corticomedullary ratio is within normal limits, and corticomedullary definition is preserved. There is no evidence of pyelectasia, nephrolithiasis, or hydronephrosis. Color Doppler demonstrates a normal vascular pattern.

Adrenal Glands

Both adrenal glands show normal shape and echogenicity. Dorsoventral diameters measured in the sagittal plane: The left adrenal gland measures 0.30 cm at the cranial pole and 0.35 cm at the caudal pole. The right adrenal gland measures cm at the cranial pole and cm at the caudal pole.

Spleen

The spleen is reduced in size (splenic thickness 0.53 cm). The parenchyma is diffusely hypoechoic with a fine homogeneous echotexture and no focal lesions. The splenic capsule is smooth and regular.

Liver

The liver is subjectively normal in size, with sharp edges and a regular contour. The liver parenchyma looks uniform and isoechoic compared to the falciform fat, with a normal echotexture. No hepatic lymphadenopathy is observed.



PATIENT

Felix Haverkamp

SPECIES

Feline

BREED

Domestic Shorthair

SEX

Neutered male

AGE

13 years

WEIGHT

6.56 lbs

INTERPRETED BY

Alicia Angosto
Guerrero, DMV,
PgDip, MSc.

IMAGING PERFORMED BY

Dr. Arms

HOSPITAL NAME

Gilbertsville VH

REFERRING VET

Dr. Yiannis

INVOICE

74078

DATE

4/2/26

The gallbladder lumen is normally distended. The wall is thin and the contents are primarily anechoic with a small amount of biliary sludge. No evident dilation of the cystic duct or common bile duct is observed.

Gastrointestinal

The stomach is empty and folded, with a wall thickness of 1.35 mm and preserved layering. The pylorus measures 2.85 mm.

Duodenum: 2.42 mm. Jejunum: 2.10 mm, with mucosa 0.89 mm, submucosa 0.62 mm, and muscularis propria 0.45 mm. Ileum: 2.05 mm, with mucosa 0.46 mm, submucosa 0.75 mm, and muscularis propria 0.21 mm. Wall layering is preserved. The ileocecal junction was not visualized. No evidence of inflammation, ileus, or foreign material is identified.

Colon: contains formed feces.

Pancreas

Pancreatic thickness ranges from 5.20–5.42 mm. The parenchyma is isoechoic relative to the adjacent omental fat. The pancreatic duct is not dilated. No evidence of peripancreatic inflammation is identified.

Free Abdomen

No abdominal effusion or signs of peritonitis are present.

Cranial mesenteric lymph nodes measure 6.72 mm, with normal shape and echogenicity.

Ileocecal lymph nodes are not visualized; the surrounding region appears unremarkable.

Thoracic cavity

There is marked anechoic pleural effusion with associated severe pulmonary atelectasis. No obvious cardiomegaly is identified on the limited view.

PRIMARY FINDINGS

- Marked pleural effusion with secondary pulmonary atelectasis
- Small, diffusely hypoechoic spleen.

SECONDARY FINDINGS

- Kidneys are within the upper limits of normal size for this patient, showing bilateral renal cortical hyperechogenicity.



PATIENT

Felix Havercamp

SPECIES

Feline

BREED

Domestic Shorthair

SEX

Neutered male

AGE

13 years

WEIGHT

6.56 lbs

INTERPRETED BY

Alicia Angosto
Guerrero, DMV,
PgDip, MSc.

IMAGING PERFORMED BY

Dr. Arms

HOSPITAL NAME

Gilbertsville VH

REFERRING VET

Dr. Yiannis

INVOICE

74078

DATE

4/2/26

INTERPRETATION OF THE FINDINGS & FURTHER RECOMMENDATIONS

The abdominal ultrasound is largely unremarkable, with no evidence of mass lesions, significant lymphadenopathy, or intestinal infiltrative disease. Importantly, this does not exclude systemic or infiltrative disease, particularly in the context of FIV infection and pancytopenia.

The small, diffusely hypoechoic spleen may reflect lymphoid depletion, infiltrative disease, or systemic illness, and should be interpreted in light of the patient's cytopenias.

The presence of marked pleural effusion with secondary pulmonary atelectasis is the most critical finding in this case and likely represents the primary driver of clinical disease. In combination with FIV positivity, pancitopenia, hyperglobulinemia and weight loss, this raises strong concern for a systemic infiltrative or inflammatory process, with differentials including:

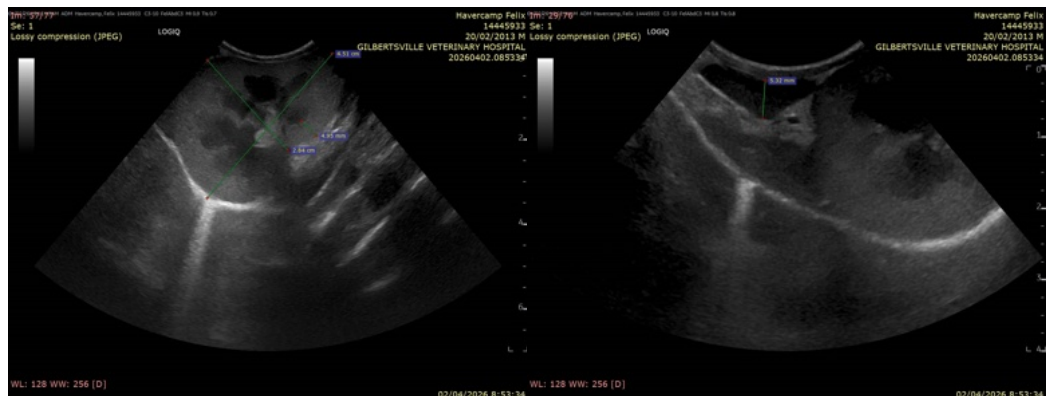
- Hematopoietic neoplasia such as leukemia, particularly given the presence of pancytopenia, (although imaging findings are not specific for this entity).
- Lymphoma (including mediastinal or multicentric forms).
- FIP, less likely but possible.

No abdominal findings definitively confirm a primary source of disease.

Recommendations

- Thoracocentesis with cytology and protein analysis.
- Consider evaluation for lymphoma (cytology).
- Bone marrow assessment: strongly recommended to evaluate for infiltrative or primary marrow disease.
- Consider infectious disease testing (FIP) as appropriate.

Final diagnostic and therapeutic decisions should be made by the attending veterinarian, who can best integrate these findings with the patient's clinical status.





PATIENT

Felix Havercamp

SPECIES

Feline

BREED

Domestic Shorthair

SEX

Neutered male

AGE

13 years

WEIGHT

6.56 lbs

INTERPRETED BY

Alicia Angosto
Guerrero, DMV,
PgDip, MSc.

IMAGING PERFORMED BY

Dr. Arms

HOSPITAL NAME

Gilbertsville VH

REFERRING VET

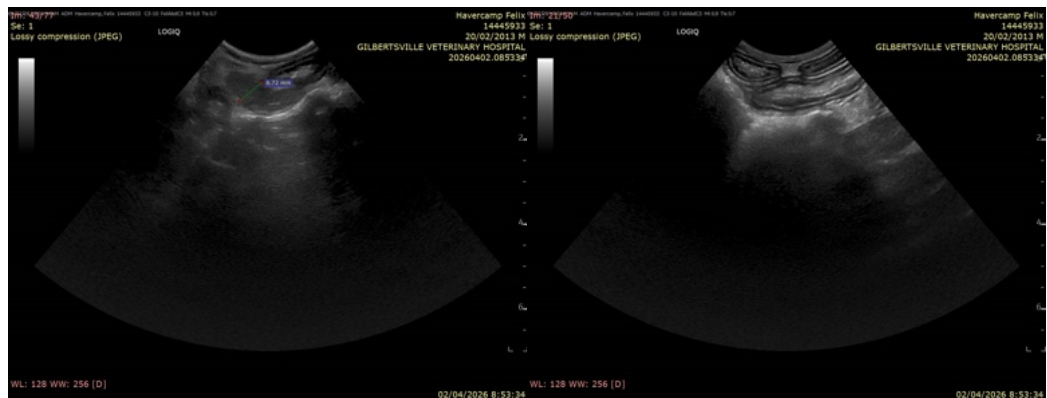
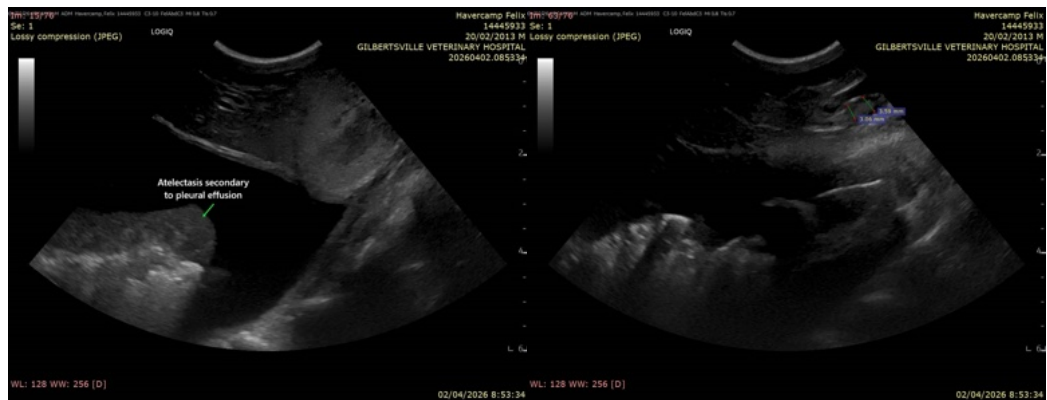
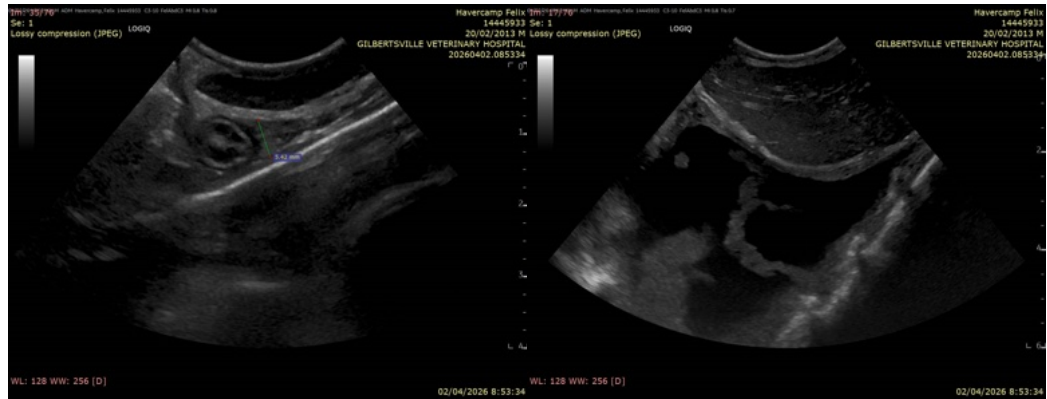
Dr. Yiannis

INVOICE

74078

DATE

4/2/26





PATIENT

Felix Havercamp

SPECIES

Feline

BREED

Domestic Shorthair

SEX

Neutered male

AGE

13 years

WEIGHT

6.56 lbs

INTERPRETED BY

Alicia Angosto
Guerrero, DMV,
PgDip, MSc.

IMAGING PERFORMED BY

Dr. Arms

HOSPITAL NAME

Gilbertsville VH

REFERRING VET

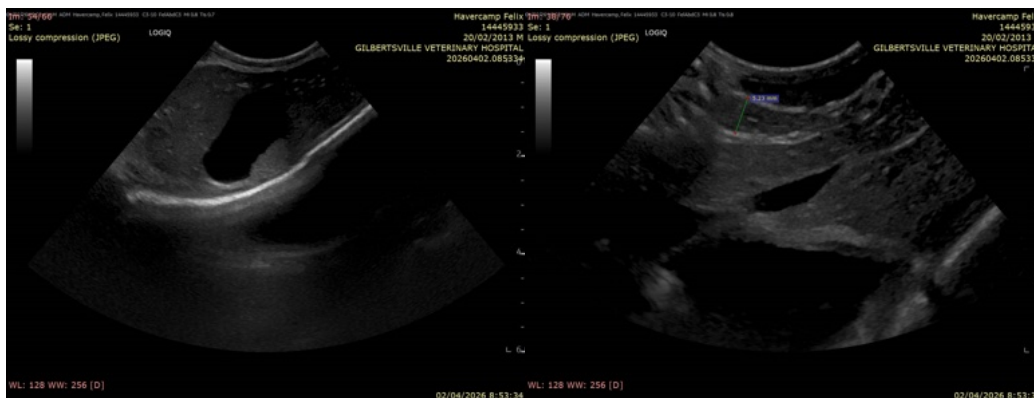
Dr. Yiannis

INVOICE

74078

DATE

4/2/26



The information and recommendations provided are based on the images presented by the referring veterinarian/sonographer. No evaluation can be communicated regarding pathology that was not visible in the image/video clips provided.

Thank you for this referral. If the clinical or image interpretation does not parallel your findings or if I can be of any further assistance please contact me.

Alicia Angosto Guerrero, DMV, PgDip, MSc.

info@SonoPath.com