



## PATIENT

Etta Animals in  
Distress

## SPECIES

Feline

## BREED

Domestic Shrothair

## SEX

Spayed female

## AGE

13 years

## WEIGHT

5.02 lbs

## INTERPRETED BY

Alicia Angosto  
Guerrero, DMV,  
PgDip, MSc.

## IMAGING PERFORMED BY

Renee Ziegler Post

## HOSPITAL NAME

For Cats Only VC

## REFERRING VET

Dr. Ziegler Post

## INVOICE

74109

## DATE

4/2/26

## PRESENTING CLINICAL SIGNS

- Chronic diarrhea

## ULTRASONOGRAPHIC EXAMINATION OF THE ABDOMEN

### *Urinary System*

The urinary bladder is normally distended. The bladder wall is thin, smooth, and regular. The luminal contents are anechoic. Normal appearance of the bladder neck and proximal urethra. No evidence of urolithiasis or inflammatory or proliferative changes is identified.

The left kidney is normal in shape and size, measuring 3.41×1.89 cm in the sagittal plane. Cortical thickness is 0.34 cm. The cortex is isoechoic compared to the hepatic parenchyma. The corticomedullary ratio is within normal limits, and corticomedullary definition is preserved. There is no evidence of pyelectasia, nephrolithiasis, or hydronephrosis. Color Doppler demonstrates a normal vascular pattern.

The right kidney is normal in shape and size, measuring 3.26×1.80 cm in the sagittal plane. Cortical thickness is 0.30 cm. The cortex is isoechoic compared to the hepatic parenchyma. The corticomedullary ratio is within normal limits, and corticomedullary definition is preserved. There is no evidence of pyelectasia, nephrolithiasis, or hydronephrosis. Color Doppler demonstrates a normal vascular pattern.

### *Adrenal Glands*

Both adrenal glands show normal shape and echogenicity. Dorsoventral diameters measured in the sagittal plane: The left adrenal gland measures 0.23 cm at the cranial pole and 0.20 cm at the caudal pole. The right adrenal gland measures 0.26 cm at the cranial pole and 0.27 cm at the caudal pole.

### *Spleen*

Splenic thickness is 0.81 cm. The parenchyma demonstrates normal echogenicity and fine homogeneous echotexture without focal parenchymal abnormalities. The splenic capsule is smooth and regular.

### *Liver*

The liver is subjectively normal in size, with sharp edges and a regular contour. The liver parenchyma looks uniform and isoechoic compared to the falciform fat, with a normal echotexture. No hepatic lymphadenopathy is observed.

The gallbladder lumen is normally distended. The wall is thin and the contents are primarily anechoic. No evident dilation of the cystic duct or common bile duct is observed.



## PATIENT

Etta Animals in  
Distress

## SPECIES

Feline

## BREED

Domestic Shrothair

## SEX

Spayed female

## AGE

13 years

## WEIGHT

5.02 lbs

## INTERPRETED BY

Alicia Angosto  
Guerrero, DMV,  
PgDip, MSc.

## IMAGING PERFORMED BY

Renee Ziegler Post

## HOSPITAL NAME

For Cats Only VC

## REFERRING VET

Dr. Ziegler Post

## INVOICE

74109

## DATE

4/2/26

## *Gastrointestinal*

The stomach is partially empty and folded, containing a small amount of ingesta, with a wall thickness of 1.71 mm and preserved layering.

The pylorus measures 3.57 mm. Duodenum: 2.15 mm. Jejunum: 2.80 mm, with mucosa 2.01 mm, submucosa 0.52 mm, and muscularis propria 0.42 mm. Ileum: 1.75 mm, with mucosa 0.54 mm, submucosa 0.76 mm, and muscularis propria 0.59 mm. Wall layering is preserved. The ileocecal junction measures 4.34 mm, with muscularis thickness of 2.50 mm.

Colon: ascending colon 1.69 mm; descending colon 3.16 mm, with preserved layering and semiliquid fecal material within the lumen.

## *Pancreas*

Pancreatic thickness ranges from 5.01–6.43 mm. Pancreatic parenchyma is mildly hypoechoic relative to the adjacent omental fat. The pancreatic duct is not dilated. No hyperechoic change in the surrounding peripancreatic fat is identified.

## *Free Abdomen*

No abdominal effusion or signs of peritonitis are present. Cranial mesenteric lymph nodes measure 4.83–5.57 mm, with normal shape and echogenicity. Ileocecal lymph nodes are not visualized, but the surrounding region appears unremarkable. The iliac trifurcation appears normal.

## PRIMARY FINDINGS

- Marked muscularis thickening at the ileocecal junction.
- Ileal muscularis thickening.
- Descending colonic wall thickening

## SECONDARY FINDINGS

- Mild pancreatic enlargement and hypoechoogenicity.

## INTERPRETATION OF THE FINDINGS & FURTHER RECOMMENDATIONS

This study demonstrates clinically relevant intestinal abnormalities in a cat with chronic diarrhea. The most important finding is marked thickening of the muscularis layer at the ileocecal junction, with additional milder ileal muscularis thickening. In the ileum, the muscularis-to-mucosa ratio results  $>1$ , which is abnormal in a feline patient. At the ileocecal junction, the muscularis measures 2.50 mm, which is markedly increased and clearly abnormal. Mild thickening of the descending colon is also present, with preserved layering and semiliquid luminal contents, supporting concurrent colonic involvement. This overall pattern supports chronic enteropathy and is compatible with both inflammatory bowel disease and low-grade lymphoma.



## PATIENT

Etta Animals in Distress

## SPECIES

Feline

## BREED

Domestic Shrothair

## SEX

Spayed female

## AGE

13 years

## WEIGHT

5.02 lbs

The remainder of the small intestine remains within expected thickness limits and preserves normal wall layering, and the cranial mesenteric lymph nodes remain within normal size limits with normal morphology. These findings do not support advanced infiltrative disease, but they do not exclude an early or localized infiltrative process, particularly in the ileocecal region.

The pancreatic changes are mild and nonspecific and may be seen with chronic or low-grade pancreatopathy in cats, even in the absence of peripancreatic fat changes.

Overall, the findings are most consistent with chronic enteropathy/IBD with colonic involvement, although low-grade lymphoma with distal small intestinal and colonic involvement remains an important overlapping differential.

## Recommendations

- GI panel with cobalamin assessment is recommended if not already performed.
- A strict dietary trial and symptomatic management are reasonable initial steps.
- If clinical signs persist, empirical immunomodulatory therapy may be considered.
- If response is poor or disease progresses, intestinal biopsy should be considered for definitive differentiation between inflammatory and infiltrative enteropathy.

Final diagnostic and therapeutic decisions should be made by the attending veterinarian, who can best integrate these findings with the patient's clinical status.

## INTERPRETED BY

Alicia Angosto Guerrero, DMV, PgDip, MSc.

## IMAGING PERFORMED BY

Renee Ziegler Post

## HOSPITAL NAME

For Cats Only VC

## REFERRING VET

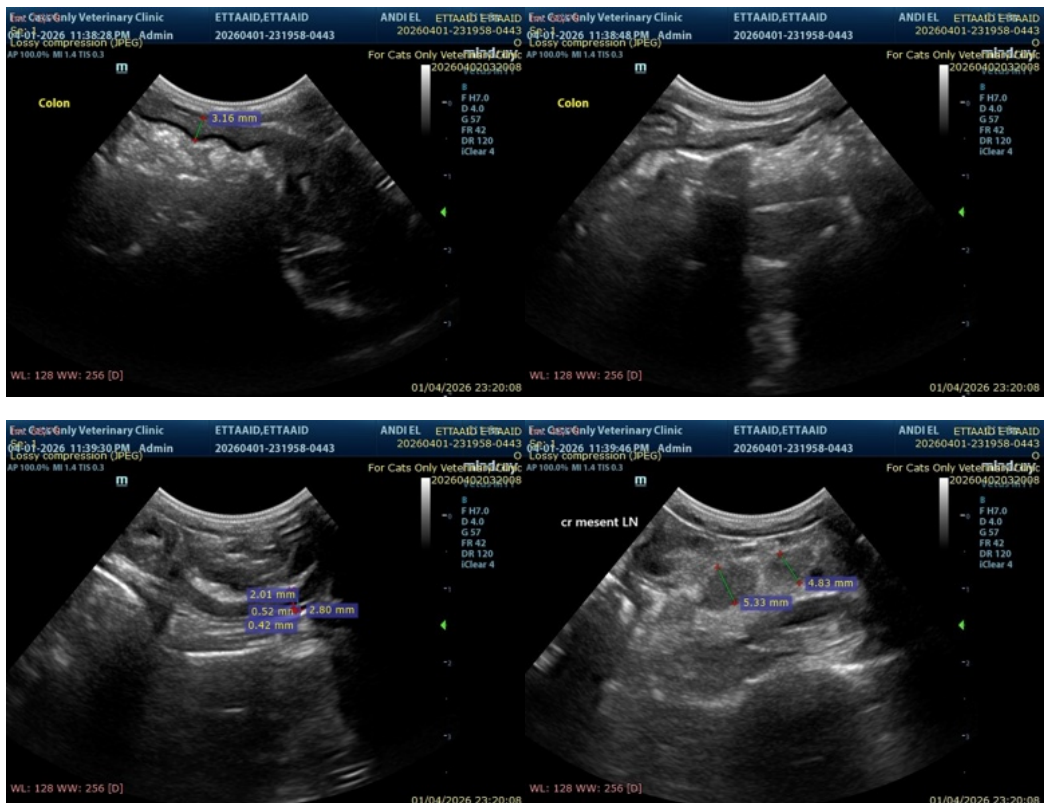
Dr. Ziegler Post

## INVOICE

74109

## DATE

4/2/26





**PATIENT**

Etta Animals in Distress

**SPECIES**

Feline

**BREED**

Domestic Shrothair

**SEX**

Spayed female

**AGE**

13 years

**WEIGHT**

5.02 lbs

**INTERPRETED BY**

Alicia Angosto Guerrero, DMV, PgDip, MSc.

**IMAGING PERFORMED BY**

Renee Ziegler Post

**HOSPITAL NAME**

For Cats Only VC

**REFERRING VET**

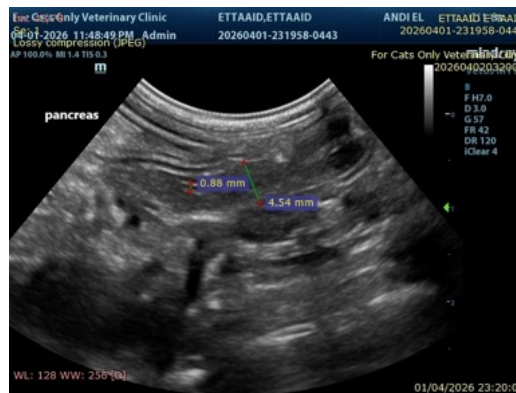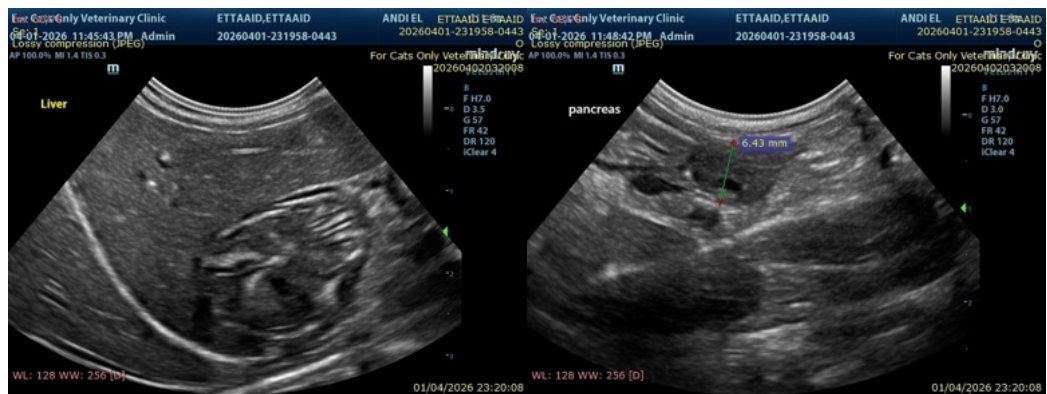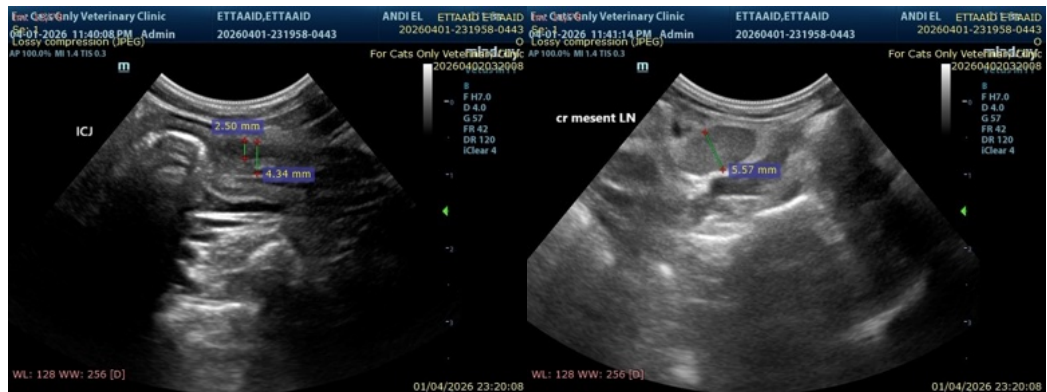Dr. Ziegler Post

**INVOICE**

74109

**DATE**

4/2/26



The information and recommendations provided are based on the images presented by the referring veterinarian/sonographer. No evaluation can be communicated regarding pathology that was not visible in the image/video clips provided.

Thank you for this referral. If the clinical or image interpretation does not parallel your findings or if I can be of any further assistance please contact me.

Alicia Angosto Guerrero, DMV, PgDip, MSc.

[info@SonoPath.com](mailto:info@SonoPath.com)