



## PATIENT

Preta Brito

## SPECIES

Feline

## BREED

DSH

## SEX

Spayed Female

## AGE

18 Years

## WEIGHT

5.4 pounds

## INTERPRETED BY

Alicia Angosto  
Guerrero, DMV,  
PgDip, MSc.

## IMAGING PERFORMED BY

Dr. Hesham Akbawy

## HOSPITAL NAME

Lincoln Avenue Cat  
and Dog Hospital

## REFERRING VET

Dr. Hesham Akbawy

## INVOICE

15202

## DATE

04/17/26

## PRESENTING CLINICAL SIGNS

Had a previous echo done on 03/31/2026. Came back with Ascites, disappearance of the hind leg petting edema. acting well. Dedication only every 5 days. 350 ml fluid was removed with Abdominocentesis. Took FNA from Liver & other tissues. Sending fluid analysis & cytology for Peritoneal effusion. FIP PCR test

## ULTRASONOGRAPHIC EXAMINATION OF THE ABDOMEN

### Urinary System

The urinary bladder lumen is normally distended, and the wall appears thin and smooth. The urine is anechoic. The bladder neck and proximal urethra have a normal appearance. No calculi or evidence of inflammatory or neoplastic changes are identified.

The left kidney is normal in shape and size; measurements are not provided. Cortical thickness is not provided.

The right kidney is normal in shape and size, measuring 2.87×1.78 cm, with a cortical thickness of 0.29 cm in the sagittal plane.

Both kidneys show cortical hyperechogenicity relative to the hepatic parenchyma. A 3.39×3.75 mm cyst is present in the left kidney. Mild pyelectasia of the left kidney is noted (1.88 mm), along with a small calculus. The corticomedullary ratio is preserved, although corticomedullary definition is decreased. A medullary rim sign is present. There is no evidence of nephrolithiasis in the right kidney.

### Adrenal Glands

Not confidently visualized.

### Spleen

Splenic thickness is 0.54 cm. The parenchyma demonstrates normal echogenicity and fine homogeneous echotexture without focal parenchymal abnormalities. The splenic capsule is smooth and regular.

### Liver

The liver shows an irregular contour, with a combination of sharp margins in some lobes and rounded margins in others, suggesting lobar volume asymmetry. The contour is mildly irregular, and hepatic parenchyma is isoechoic compared to the falciform fat. Two hyperechoic focal lesions are identified, measuring 1.08×1.14 cm and 1.71×2.28 cm. No hepatic lymphadenopathy is observed.

The gallbladder is normally distended, with a thin wall and a moderate amount of biliary sludge. No dilation of the cystic duct or common bile duct is observed.

### Gastrointestinal

The stomach is empty and folded, with a mural thickness of 1.80 mm and preserved wall layering. The pylorus measures 3.53 mm. The duodenum measures 2.26 mm. The jejunum measures 2.62 mm, with mucosa 1.47 mm, submucosa 0.67 mm, and muscularis propria 0.40 mm. The ileum measures 2.34 mm, with mucosa 1.03 mm, submucosa 0.88 mm, and muscularis propria 0.38 mm; wall layering is preserved. The ileocecal junction measures 2.96 mm, with muscularis 1.41 mm. No signs of inflammation, ileus, or foreign material are identified.



## PATIENT

The colon measures 1.17 mm and contains formed feces in the descending segment.

Preta Brito

## Pancreas

## SPECIES

The pancreas measures 8.86–9.11 mm in thickness. The parenchyma is hypoechoic relative to adjacent omental fat and heterogeneous, with multiple nodules <1 cm and an irregular contour. The pancreatic duct is dilated, measuring 2.92 mm. Peripancreatic lymphadenopathy is present.

Feline

## BREED

## Free Abdomen

DSH

Moderate amount of turbid abdominal effusion is present. Cranial mesenteric and ileocecal lymph nodes are not visualized, and the surrounding regions appear unremarkable. The iliac trifurcation appears normal.

## SEX

## PRIMARY FINDINGS

Spayed Female

- Irregular hepatic contour with lobar asymmetry.
- Two focal hyperechoic hepatic lesions.
- Pancreatic enlargement (8.86–9.11 mm), hypoechoogenicity, heterogeneity, nodular changes, irregular margins, and marked pancreatic duct dilation (2.92 mm).
- Peripancreatic lymphadenopathy.
- Moderate turbid abdominal effusion.

## AGE

18 Years

## WEIGHT

5.4 pounds

## SECONDARY FINDINGS

## INTERPRETED BY

- Bilateral renal cortical hyperechogenicity with decreased corticomedullary definition and medullary rim sign.
- Left renal cyst (3.39×3.75 mm), mild pyelectasia (1.88 mm), and small calculus.
- Moderate biliary sludge.

Alicia Angosto  
Guerrero, DMV,  
PgDip, MSc.

## INTERPRETATION OF THE FINDINGS & FURTHER RECOMMENDATIONS

## IMAGING PERFORMED BY

The most clinically significant finding is marked pancreatic disease, characterized by enlargement, hypoechoogenicity, heterogeneous and nodular architecture, irregular margins, and pancreatic duct dilation, accompanied by peripancreatic lymphadenopathy and moderate turbid abdominal effusion. This constellation of findings is most consistent with severe chronic pancreatitis with pancreatic nodular hyperplasia or pancreatic neoplasia. Given the degree of ductal dilation and nodular changes, a neoplastic process cannot be excluded and remains a relevant differential. Ultrasound alone cannot reliably differentiate between these entities.

Dr. Hesham Akbawy

## HOSPITAL NAME

Lincoln Avenue Cat  
and Dog Hospital

## REFERRING VET

Dr. Hesham Akbawy

Hepatic changes (irregular contour with lobar asymmetry and focal hyperechoic lesions) are compatible with chronic hepatopathy and could contribute to ascites through portal hypertension. However, this cannot be substantiated in the absence of portal vein hemodynamic assessment (velocity measurements) and without biochemical evaluation of hepatic function. Consequently, the role of hepatic disease in the development of effusion remains uncertain.

## INVOICE

15202

There is no ultrasonographic evidence of right-sided congestive heart failure to explain the effusion.

## DATE

04/17/26

Renal findings are consistent with chronic kidney disease in a geriatric cat and are likely incidental to the current presentation.

Gastrointestinal measurements, including muscularis-to-mucosa ratios, do not support inflammatory



**PATIENT**

bowel disease or small cell lymphoma.

Preta Brito

**Recommendations**

**SPECIES**

- Await and prioritize cytology of abdominal effusion and previously obtained FNAs (liver and other tissues), as these may provide a minimally invasive diagnosis.
- Complete serum biochemistry, including liver enzymes, bilirubin, albumin, and pancreatic markers (fPLI), is strongly recommended to contextualize hepatic and pancreatic findings.
- If clinical suspicion for neoplasia remains high and noninvasive tests are inconclusive, advanced imaging or surgical exploration/biopsy may be required for definitive diagnosis.
- Supportive management (analgesia, antiemetics, nutritional support) is reasonable while diagnostics are pending, but establishing an underlying diagnosis remains important for prognosis and treatment planning.

Feline

**BREED**

DSH

**SEX**

Spayed Female

Final diagnostic and therapeutic decisions should be made by the attending veterinarian, who can best integrate these findings with the patient's clinical status.

**AGE**

18 Years

**WEIGHT**

5.4 pounds

**INTERPRETED BY**

Alicia Angosto  
Guerrero, DMV,  
PgDip, MSc.

**IMAGING  
PERFORMED BY**

Dr. Hesham Akbawy

**HOSPITAL NAME**

Lincoln Avenue Cat  
and Dog Hospital

**REFERRING VET**

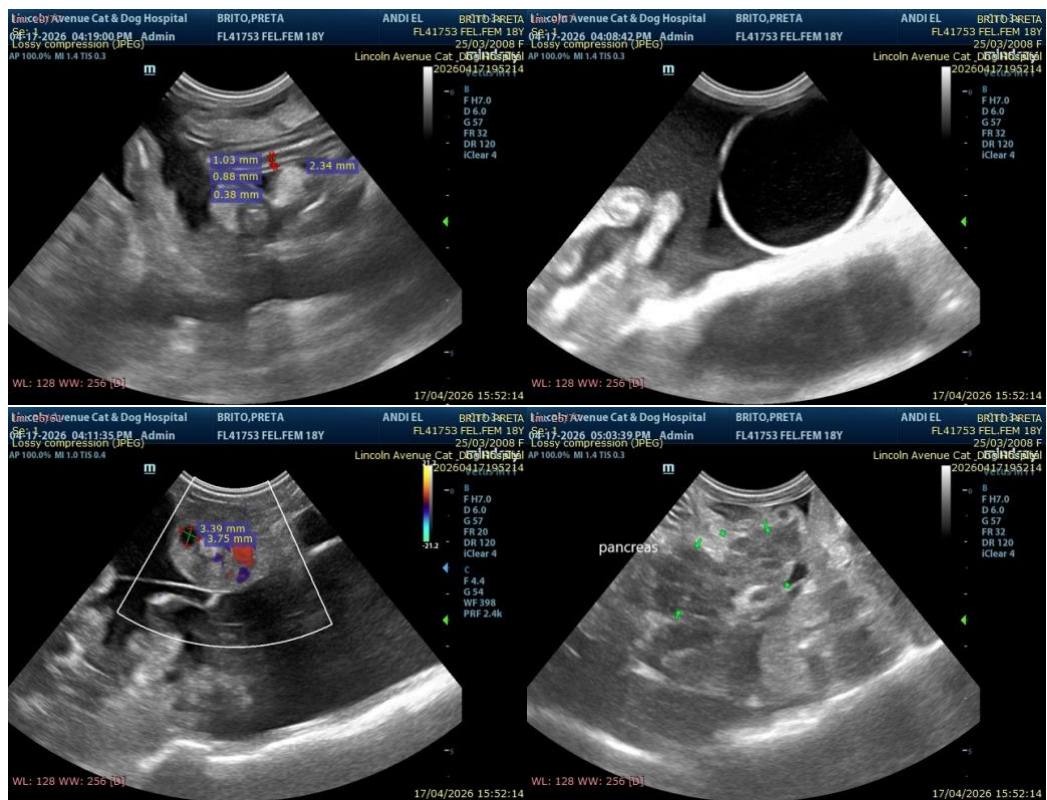
Dr. Hesham Akbawy

**INVOICE**

15202

**DATE**

04/17/26





**PATIENT**

Preta Brito

**SPECIES**

Feline

**BREED**

DSH

**SEX**

Spayed Female

**AGE**

18 Years

**WEIGHT**

5.4 pounds

**INTERPRETED BY**

Alicia Angosto  
Guerrero, DMV,  
PgDip, MSc.

**IMAGING  
PERFORMED BY**

Dr. Hesham Akbawy

**HOSPITAL NAME**

Lincoln Avenue Cat  
and Dog Hospital

**REFERRING VET**

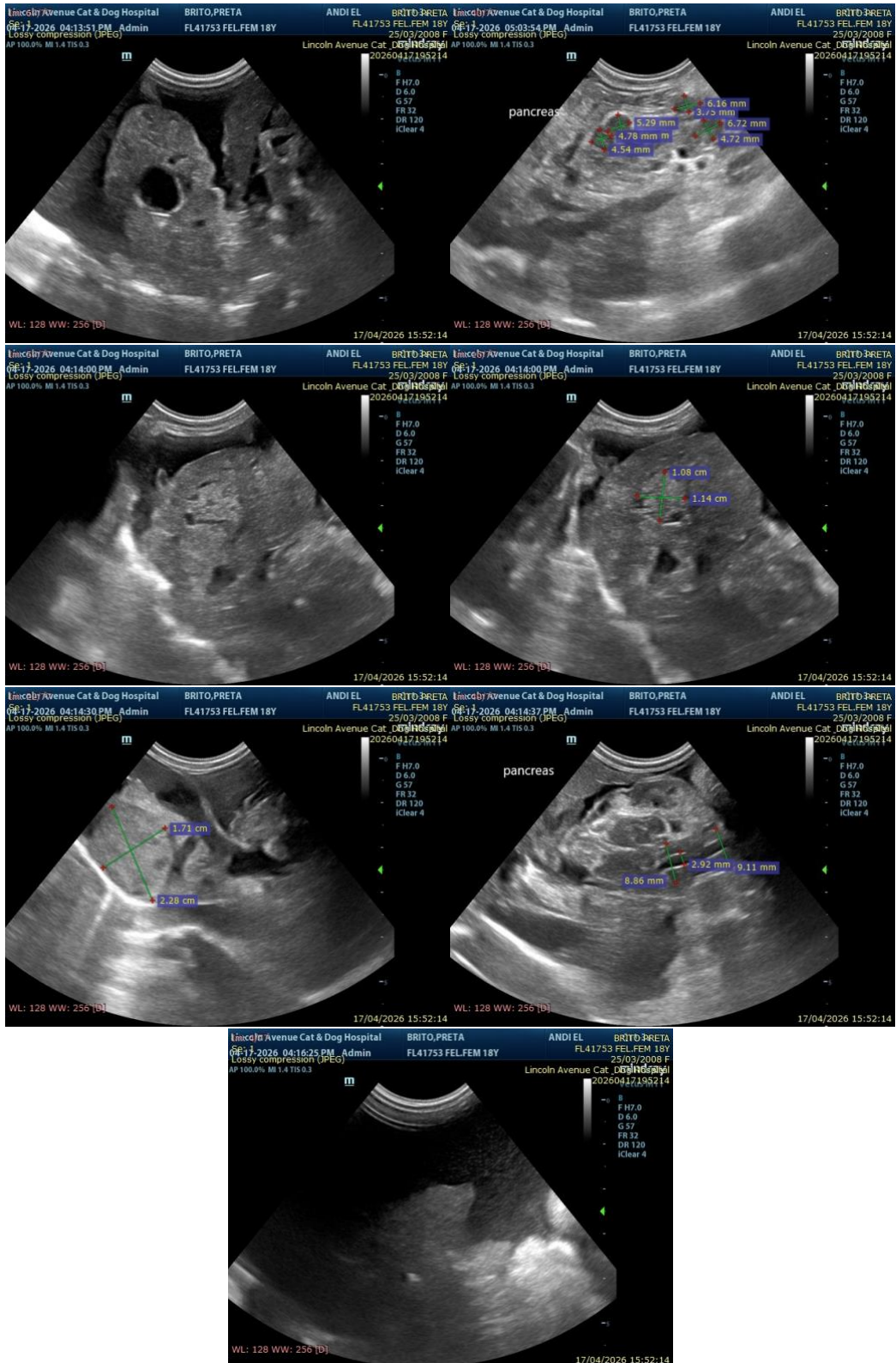
Dr. Hesham Akbawy

**INVOICE**

15202

**DATE**

04/17/26





## PATIENT

Preta Brito

## SPECIES

Feline

## BREED

DSH

## SEX

Spayed Female

## AGE

18 Years

## WEIGHT

5.4 pounds

## INTERPRETED BY

Alicia Angosto  
Guerrero, DMV,  
PgDip, MSc.

## IMAGING PERFORMED BY

Dr. Hesham Akbawy

## HOSPITAL NAME

Lincoln Avenue Cat  
and Dog Hospital

## REFERRING VET

Dr. Hesham Akbawy

## INVOICE

15202

## DATE

04/17/26

The information and recommendations provided are based on the images presented by the referring veterinarian/sonographer. No evaluation can be communicated regarding pathology that was not visible in the image/video clips provided.

Thank you for this referral. If the clinical or image interpretation does not parallel your findings or if I can be of any further assistance please contact me.

Alicia Angosto Guerrero, DMV, PgDip, MSc.

[info@SonoPath.com](mailto:info@SonoPath.com)