



PATIENT

Seti Bake

SPECIES

Feline

BREED

DSH

SEX

Spayed Female

AGE

7 Years

WEIGHT

11.2 pounds

INTERPRETED BY

Alicia Angosto
Guerrero, DMV,
PgDip, MSc.

IMAGING PERFORMED BY

Dr. Justin Eckenrode
DVM

HOSPITAL NAME

Carlisle Small Animal
Veterinary Clinic

REFERRING VET

Dr. Juel Shamitko
DVM

INVOICE

15110

DATE

04/14/26

PRESENTING CLINICAL SIGNS

Major Medical Conditions: Weight loss and decreased appetite; presumed resorptive lesions on teeth (dental scheduled) Patient History: O noted weight loss at home - was 16# on 2/26/25 and only weighed 12.3# on 3/18/26, 11.2# on 4/7/26. P has been eating softer foods more than hard kibble and seems painful with mouth when eating, but further weight loss seems significant in 3-week time. O is not noticing any changes to energy level and no vomiting or diarrhea seen. Primary concern or rule out: neoplasia vs inflammatory (GI) Spayed/neutered: spayed

Abnormal PE/Chem/CBC/UA Results: Total WBC - WNL; MONOCYTE 516 (467H); BASOPHIL 258 (100H) ALB 2.6 (2.6L); CHOLESTEROL 37 (91L) Previously FIV/FelV negative

ULTRASONOGRAPHIC EXAMINATION OF THE ABDOMEN

Urinary System

The urinary bladder lumen is normally distended, and the wall appears thin and smooth. The urine is anechoic. Normal appearance of the bladder neck and proximal urethra. There are no calculi or evidence of inflammatory or neoplastic changes.

The left kidney is normal in shape and size (3.51×2.10 cm), with a cortical thickness of 0.36 cm in the sagittal plane. The cortex is isoechoic compared to the liver parenchyma. The corticomedullary ratio is normal, and corticomedullary definition is preserved. There is no evidence of pyelectasia, nephroliths, or hydronephrosis. Color Doppler shows a normal vascular pattern.

The right kidney is normal in shape and size (3.78×2.16 cm), with a cortical thickness of 0.33 cm in the sagittal plane. The cortex is isoechoic compared to the liver parenchyma. The corticomedullary ratio is normal, and corticomedullary definition is preserved. There is no evidence of pyelectasia, nephroliths, or hydronephrosis. Color Doppler shows a normal vascular pattern.

Adrenal Glands

Both adrenal glands show normal shape and echogenicity. Dorsoventral diameters measured in the sagittal plane: The left adrenal gland measures 0.26 cm at the cranial pole and 0.30 cm at the caudal pole. The right adrenal gland measures 0.32 cm at the cranial pole and 0.32 cm at the caudal pole.

Spleen

Splenic thickness is 0.59 cm. The parenchyma demonstrates normal echogenicity and fine homogeneous echotexture without focal parenchymal abnormalities. The splenic capsule is smooth and regular. Splenic vasculature appears normal.

Liver

The liver is subjectively normal in size, with sharp edges and regular contour. The parenchyma is homogeneous and isoechoic relative to the falciform fat, with a normal echotexture. No hepatic lymphadenopathy is identified.

The gallbladder is normally distended, with a thin wall and predominantly anechoic contents. The common bile duct measures 2.69 mm, which is within normal limits for a cat (<3 mm).

Gastrointestinal



PATIENT

The stomach is empty and folded, with a mural thickness of 1.40 mm and preserved wall layering, within normal limits.

Seti Bake

SPECIES

Duodenum: 1.38 mm (within normal limits).

Jejunum: 1.95–2.17 mm (within normal limits). Layer measurements: mucosa 1.02 mm, submucosa 0.58 mm, muscularis propria 0.39 mm. The muscularis-to-mucosa ratio is approximately 0.38, which is within expected limits (<0.5) and does not support muscularis hypertrophy.

Feline

BREED

Ileum: 1.87 mm (within normal limits). Layer measurements: mucosa 0.70 mm, submucosa 1.03 mm, muscularis propria 0.40 mm. The muscularis-to-mucosa ratio is approximately 0.57, which is mildly increased relative to typical expectations (<0.5), although interpretation is limited given the relatively small mucosal measurement and potential segmental variability. Wall layering is preserved.

DSH

SEX

The ileocecal junction was normally visualized.

Spayed Female

AGE

No ultrasonographic evidence of ileus, obstructive material, or focal inflammatory changes is identified in the evaluated segments.

7 Years

Colon: 1.14 mm, within normal limits, containing formed feces in the descending segment.

WEIGHT

Pancreas

The evaluated pancreatic areas do not show evidence of overt inflammation or neoplastic disease.

11.2 pounds

Free Abdomen

INTERPRETED BY

No sonographic evidence of abdominal effusion, peritonitis, or lymphadenomegaly is identified. The iliac trifurcation is normal.

Alicia Angosto
Guerrero, DMV,
PgDip, MSc.

PRIMARY FINDINGS

- Very mild increase in ileal muscularis-to-mucosa ratio (≈ 0.57), of uncertain clinical significance.

IMAGING PERFORMED BY

INTERPRETATION OF THE FINDINGS & FURTHER RECOMMENDATIONS

Dr. Justin Eckenrode
DVM

This is a largely unremarkable abdominal ultrasound with no definitive structural cause identified for the patient's marked and rapid weight loss.

HOSPITAL NAME

Carlisle Small Animal
Veterinary Clinic

The gastrointestinal tract, within the limits of the study, shows normal wall thickness and preserved layering throughout. In the jejunum, the muscularis-to-mucosa ratio remains within expected limits, which does not support muscularis hypertrophy typically associated with chronic enteropathy or small cell lymphoma. The ileum shows a mild relative increase in this ratio (≈ 0.57); however, this finding is subtle, segmental, and not accompanied by wall thickening, loss of layering, or mesenteric lymphadenopathy. As such, it is not sufficient, in isolation, to support a diagnosis of inflammatory bowel disease or lymphoma, particularly given the known overlap and variability in feline intestinal measurements.

REFERRING VET

Dr. Juel Shamitko
DVM

INVOICE

However, the lack of ultrasonographic abnormalities does not exclude clinically significant gastrointestinal disease in cats, especially in cases of early or low-grade chronic enteropathy, or functional or diffuse mucosal disease (cobalamin deficiency-associated enteropathy) which may present minimal or absent sonographic changes.

15110

DATE

04/14/26

Recommendations

- Further gastrointestinal functional assessment:
 - Serum cobalamin and folate concentrations are strongly recommended.



PATIENT

Seti Bake

SPECIES

Feline

BREED

DSH

SEX

Spayed Female

AGE

7 Years

WEIGHT

11.2 pounds

INTERPRETED BY

Alicia Angosto
Guerrero, DMV,
PgDip, MSc.

IMAGING PERFORMED BY

Dr. Justin Eckenrode
DVM

HOSPITAL NAME

Carlisle Small Animal
Veterinary Clinic

REFERRING VET

Dr. Juel Shamitko
DVM

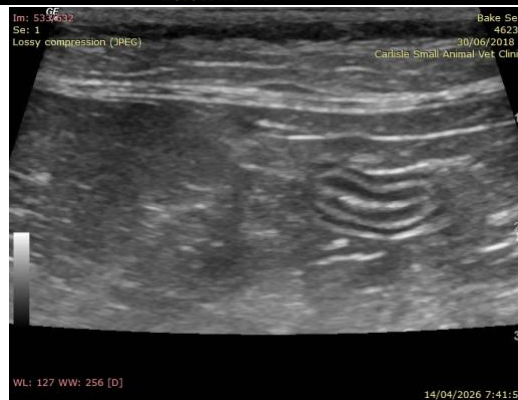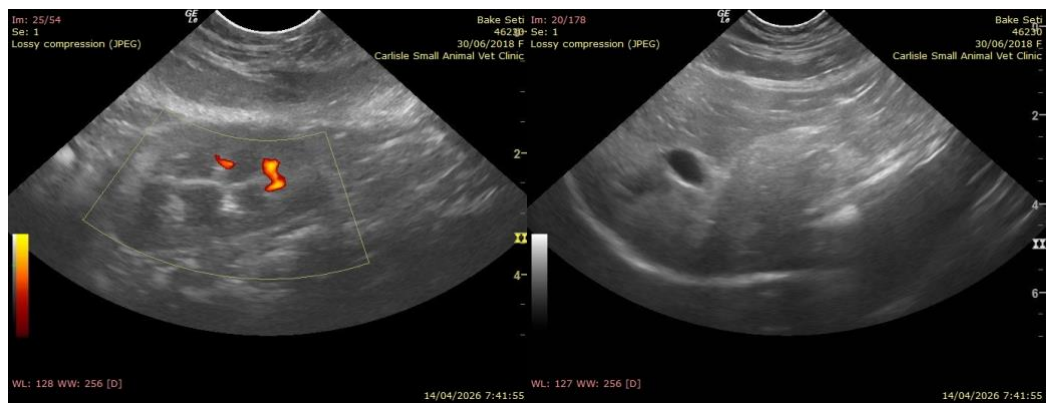
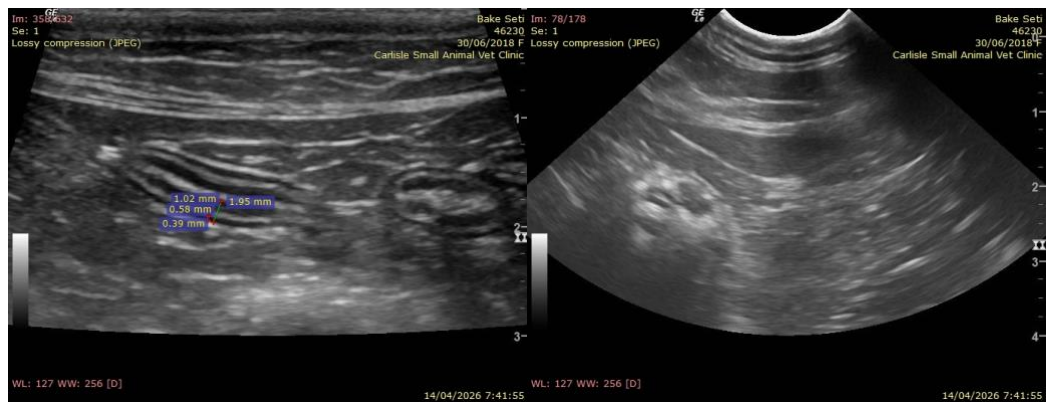
INVOICE

15110

DATE

04/14/26

- Consider feline pancreatic lipase (fPLI) to assess concurrent pancreatitis.
- Nutritional and clinical monitoring
 - Close monitoring of body weight, appetite, and stool quality.
 - Consider early dietary trial (highly digestible or novel protein) if not already initiated.
 - Empirical cobalamin supplementation is reasonable given the clinical context, even prior to results.
- If clinical signs persist or progress: intestinal biopsies should be considered, as this is the only reliable way to have a definitive diagnosis.



The information and recommendations provided are based on the images presented by the referring



PATIENT

Seti Bake

SPECIES

Feline

BREED

DSH

SEX

Spayed Female

AGE

7 Years

WEIGHT

11.2 pounds

INTERPRETED BY

Alicia Angosto
Guerrero, DMV,
PgDip, MSc.

IMAGING PERFORMED BY

Dr. Justin Eckenrode
DVM

HOSPITAL NAME

Carlisle Small Animal
Veterinary Clinic

REFERRING VET

Dr. Juel Shamitko
DVM

INVOICE

15110

DATE

04/14/26

veterinarian/sonographer. No evaluation can be communicated regarding pathology that was not visible in the image/video clips provided.

Thank you for this referral. If the clinical or image interpretation does not parallel your findings or if I can be of any further assistance please contact me.

Alicia Angosto Guerrero, DMV, PgDip, MSc.

info@SonoPath.com