



PATIENT

Colby Kimpland

SPECIES

Canine

BREED

Cockapoo

SEX

Neutered male

AGE

15 years

WEIGHT

23 lbs

INTERPRETED BY

Alicia Angosto
Guerrero, DMV,
PgDip, MSc.

IMAGING PERFORMED BY

Anshu Gupta

HOSPITAL NAME

Liverpool Village AH

REFERRING VET

Dr. Lathrop

INVOICE

74430

DATE

4/13/26

PRESENTING CLINICAL SIGNS

History: - AUS for hypercalcemia. Presented 4/3 for mobility changes and fecal incontinence.
Historical medical conditions: Anxiety; Nuclear sclerosis; Dental disease; OA; Heart murmur; Warts;
Neck pain
Abnormal PE/Chem/CBC/UA Results: PLT 694 BUN 42, Creat 1.2 Total Ca 12.6 mg/dL

ULTRASONOGRAPHIC EXAMINATION OF THE ABDOMEN

Urinary System

The urinary bladder is normally distended, with a thin and smooth wall. The urine is predominantly anechoic with scant suspended echoes. The bladder neck and proximal urethra are unremarkable. No uroliths or evidence of inflammatory or neoplastic changes are identified.

The left kidney measures 4.58×2.84 cm, with cortical thickness of 0.42 cm in the sagittal plane. The cortex is mildly hyperechoic relative to the hepatic parenchyma and contains a few cysts, the largest measuring 0.41×0.56 cm. Corticomedullary ratio and definition are preserved. No pyelectasia, nephrolithiasis, or hydronephrosis is identified. Doppler color shows a normal vascular pattern.

The right kidney measures 4.67×2.99 cm, with cortical thickness of 0.45 cm in the sagittal plane. The cortex is mildly hyperechoic relative to the hepatic parenchyma. Corticomedullary ratio and definition are preserved. No pyelectasia, nephrolithiasis, or hydronephrosis is identified. Doppler color shows a normal vascular pattern.

Prostate

Small, hypoechoic, and homogeneous, compatible with post-castration atrophy.

Adrenal Glands

Both adrenal glands have normal shape and echogenicity. Dorsoventral diameters measured in the sagittal plane: the left adrenal gland measures 0.52 cm (cranial pole) and 0.63 cm (caudal pole). The right adrenal gland measures 0.65 cm (cranial pole) and 0.49 cm (caudal pole). These measurements are mildly increased (reference upper limit ~0.6 cm).

Spleen

Splenic thickness is 1.57 cm. The parenchyma demonstrates normal echogenicity and homogeneous echotexture, with a focal lesion measuring 0.48×0.68 cm consistent with a myelolipoma. An additional lesion, measuring 0.9×1.44 cm, is identified at the ventral extremity, isoechoic to splenic parenchyma, homogeneous, and causing focal capsular bulging with an exophytic appearance. Surrounding fat is mildly hyperechoic. Doppler color appears unremarkable.



PATIENT

Colby Kimpland

SPECIES

Canine

BREED

Cockapoo

SEX

Neutered male

AGE

15 years

WEIGHT

23 lbs

INTERPRETED BY

Alicia Angosto
Guerrero, DMV,
PgDip, MSc.

IMAGING PERFORMED BY

Anshu Gupta

HOSPITAL NAME

Liverpool Village AH

REFERRING VET

Dr. Lathrop

INVOICE

74430

DATE

4/13/26

Liver

The liver is subjectively normal in size, with sharp edges and regular contour. The parenchyma is homogeneous and isoechoic relative to falciform fat, with normal echotexture. No hepatic lymphadenopathy is identified.

The gallbladder is markedly distended, with a thin wall and containing a moderate amount of biliary sludge. The cystic duct and common bile duct are not confidently visualized.

Gastrointestinal

The stomach is empty and folded, with mural thickness of 1.88 mm and preserved wall layering (within normal limits). The pylorus measures 4.67 mm (within normal limits). The duodenum measures 4.74 mm (within normal limits). The jejunum measures 3.42 mm, within normal limits, with preserved wall layering. No evidence of inflammation, ileus, or foreign material is identified. The colon measures 1.32 cm in diameter, containing a small amount of soft fecal material.

Pancreas

The evaluated pancreatic areas do not show evidence of overt inflammation or neoplastic disease.

Free Abdomen

No sonographic evidence of abdominal effusion, peritonitis, or lymphadenomegaly is identified. The iliac trifurcation is normal.

PRIMARY FINDINGS

- Isoechoic splenic nodule protruding beyond the splenic capsule, with mild increased echogenicity of the adjacent perisplenic fat.
- Markedly distended gallbladder with biliary sludge.

SECONDARY FINDINGS

- Mild bilateral adrenal enlargement.
- Mild bilateral renal cortical hyperechogenicity with renal cysts.

INTERPRETATION OF THE FINDINGS & FURTHER RECOMMENDATIONS

The adrenal glands are mildly enlarged (measurements approaching or slightly exceeding 0.6 cm), which may raise consideration for adrenal involvement; however, the changes are mild, relatively symmetric, and nonspecific, and are insufficient to support a diagnosis of hyperadrenocorticism or adrenal-dependent disease based on imaging alone.

The spleen contains two focal lesions: one is consistent with a benign myelolipoma, while the second, homogeneous and isoechoic exophytic lesion is most compatible with a benign nodular process (nodular



PATIENT

Colby Kimpland

SPECIES

Canine

BREED

Cockapoo

SEX

Neutered male

AGE

15 years

WEIGHT

23 lbs

INTERPRETED BY

Alicia Angosto
Guerrero, DMV,
PgDip, MSc.

IMAGING PERFORMED BY

Anshu Gupta

HOSPITAL NAME

Liverpool Village AH

REFERRING VET

Dr. Lathrop

INVOICE

74430

DATE

4/13/26

hyperplasia or extramedullary hematopoiesis). The mild increase in echogenicity of the adjacent fat is a subtle and nonspecific finding, which may reflect reactive change; however, there are no additional features to strongly support an aggressive or infiltrative splenic process.

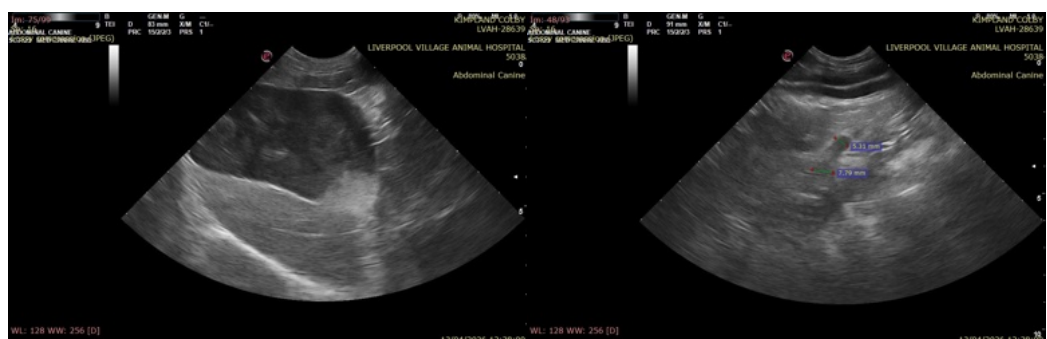
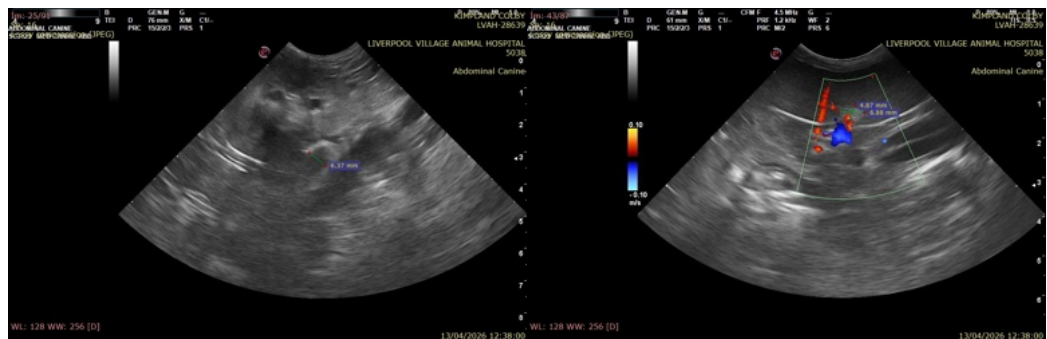Renal changes are most consistent with chronic or age-related change.

No lymphadenomegaly, mass lesions, or evidence of anal sac disease are identified within the limits of this study to support malignancy-associated hypercalcemia.

Recommendations

- Further characterization of hypercalcemia is recommended, ideally including measurement of ionized calcium to confirm true hypercalcemia.
- If confirmed, additional diagnostics such as PTH and PTHrP testing may be considered to differentiate between primary hyperparathyroidism and malignancy-associated hypercalcemia.
- Careful clinical evaluation of the anal sac region is advised if not already performed, as small lesions may be difficult to detect ultrasonographically.
- The splenic lesion may be monitored or aspirated if clinical concern persists.
- Continued clinical and laboratory monitoring is recommended, with reassessment if hypercalcemia persists or progresses.

Final diagnostic and therapeutic decisions should be made by the attending veterinarian, who can best integrate these findings with the patient's clinical status.





PATIENT

Colby Kimpland

SPECIES

Canine

BREED

Cockapoo

SEX

Neutered male

AGE

15 years

WEIGHT

23 lbs

INTERPRETED BY

Alicia Angosto Guerrero, DMV,
PgDip, MSc.

IMAGING PERFORMED BY

Anshu Gupta

HOSPITAL NAME

Liverpool Village AH

REFERRING VET

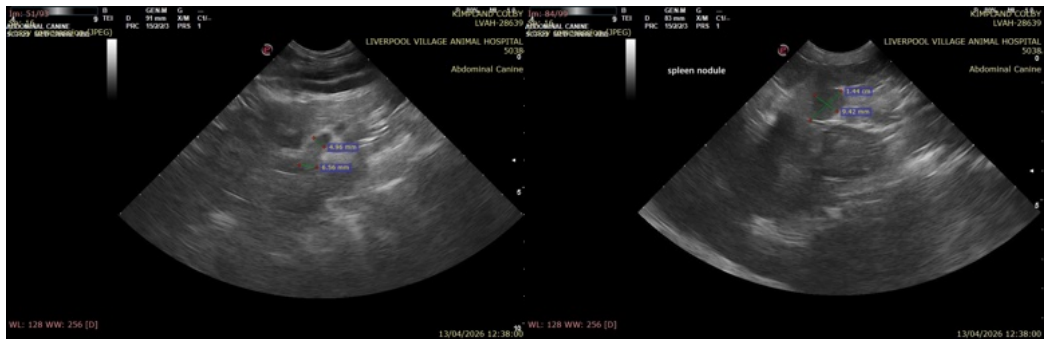
Dr. Lathrop

INVOICE

74430

DATE

4/13/26



The information and recommendations provided are based on the images presented by the referring veterinarian/sonographer. No evaluation can be communicated regarding pathology that was not visible in the image/video clips provided.

Thank you for this referral. If the clinical or image interpretation does not parallel your findings or if I can be of any further assistance please contact me.

Alicia Angosto Guerrero, DMV, PgDip, MSc.

info@SonoPath.com