



PATIENT

Brick Poitras

SPECIES

Canine

BREED

Mix

SEX

Neutered male

AGE

13 years

WEIGHT

66 lbs

INTERPRETED BY

Alicia Angosto
Guerrero, DMV,
PgDip, MSc.

IMAGING PERFORMED BY

Lexi Naylor

HOSPITAL NAME

Malletts Bay VH

REFERRING VET

Dr. Naylor

INVOICE

74421

DATE

4/13/26

PRESENTING CLINICAL SIGNS

History: weight gain, cranial organomegaly, lethargy, mobility changes <6m. PE otherwise unremarkable

Abnormal PE/Chem/CBC/UA Results: mild NR anemia, otherwise WNL

ULTRASONOGRAPHIC EXAMINATION OF THE ABDOMEN

Urinary System

The urinary bladder lumen is not completely distended, and the wall measures up to 4.01 mm at the cranial aspect and appears smooth (measurement may be overestimated due to underdistension). The urine is anechoic. The bladder neck and proximal urethra are unremarkable. No uroliths or evidence of inflammatory or neoplastic changes are identified.

The left kidney is normal in shape and size (6.45×3.44 cm), with cortical thickness measuring 0.60 cm in the sagittal plane. The cortex is isoechoic relative to the hepatic parenchyma. Corticomedullary ratio and definition are preserved. No pyelectasia, nephrolithiasis, or hydronephrosis is identified. Doppler color shows a normal vascular pattern.

The right kidney is normal in shape and size (5.99×3.50 cm), with cortical thickness measuring 0.57 cm in the sagittal plane. The cortex is isoechoic relative to the hepatic parenchyma. Corticomedullary ratio and definition are preserved. No pyelectasia, nephrolithiasis, or hydronephrosis is identified. Doppler color shows a normal vascular pattern.

Adrenal Glands

Dorsoventral diameters measured in the sagittal plane: the left adrenal gland measures 0.49 cm at the cranial pole (caudal pole not confidently visualized). The right adrenal gland is partially visualized and measures 0.51 cm.

Spleen

Splenic thickness is 2.01 cm. Margins are tapered. The parenchyma demonstrates normal echogenicity and fine homogeneous echotexture without focal abnormalities. The capsule is smooth and regular.

Liver

The liver does not clearly extend beyond the lesser curvature of the stomach. Margins appear mildly rounded. No marked hepatomegaly is identified, although radiography is more reliable for liver size assessment if clinically indicated. The parenchyma is homogeneous and isoechoic relative to falciform fat, with normal echotexture. A small hyperechoic focus measuring 4.62×5.15 mm is noted. No hepatic lymphadenopathy is identified.

The gallbladder is normally distended, with a thin wall and predominantly anechoic contents, containing a small amount of biliary sludge. No dilation of the cystic duct or common bile duct is identified.



PATIENT

Brick Poitras

SPECIES

Canine

BREED

Mix

SEX

Neutered male

AGE

13 years

WEIGHT

66 lbs

INTERPRETED BY

Alicia Angosto
Guerrero, DMV,
PgDip, MSc.

IMAGING PERFORMED BY

Lexi Naylor

HOSPITAL NAME

Malletts Bay VH

REFERRING VET

Dr. Naylor

INVOICE

74421

DATE

4/13/26

Gastrointestinal

The stomach is empty and folded, with mural thickness of 2.11 mm and preserved wall layering (within normal limits). The pylorus measures 6.49 mm (within normal limits). The duodenum measures 3.18 mm (within normal limits). The jejunum measures 4.12–4.17 mm, within normal limits, with preserved wall layering. No evidence of inflammation, ileus, or foreign material is identified. The colon measures 0.76 cm in diameter, containing formed feces within the descending segment.

Pancreas

The evaluated pancreatic areas do not show evidence of overt inflammation or neoplastic disease.

Free Abdomen

No sonographic evidence of abdominal effusion, peritonitis, or lymphadenomegaly is identified. The iliac trifurcation appears normal.

PRIMARY FINDINGS

- Adrenal glands measure within accepted limits for a dog of this size.
- Mild rounding of hepatic margins.
- Small focal hyperechoic hepatic lesion.
- Mild biliary sludge.

INTERPRETATION OF THE FINDINGS & FURTHER RECOMMENDATIONS

The adrenal glands measure within accepted limits for a dog of this size (dorsoventral diameters <0.6 cm), without ultrasonographic evidence of enlargement or asymmetry. As such, there are no definitive sonographic findings to support adrenal hyperplasia.

The liver shows mildly rounded margins without clear hepatomegaly on ultrasound, and with otherwise homogeneous echotexture. There is no evidence of increased hepatic parenchymal echogenicity or ultrasonic attenuation. The small focal hyperechoic lesion is most consistent with an incidental benign change (nodular hyperplasia or fat change), given its size and appearance.

No additional structural abnormalities are identified to explain the reported cranial abdominal enlargement. However, there is a large accumulation of echogenic falciform and cranial abdominal fat, which likely contributes to the perceived organomegaly on physical examination.

The spleen, gastrointestinal tract, and pancreas are unremarkable, and no mass effect, effusion, or lymphadenomegaly is present.

Overall, this study does not provide definitive ultrasonographic evidence of hyperadrenocorticism or other structural abdominal disease.

Recommendations



PATIENT

Brick Poitras

SPECIES

Canine

BREED

Mix

SEX

Neutered male

AGE

13 years

WEIGHT

66 lbs

INTERPRETED BY

Alicia Angosto
Guerrero, DMV,
PgDip, MSc.

IMAGING PERFORMED BY

Lexi Naylor

HOSPITAL NAME

Malletts Bay VH

REFERRING VET

Dr. Naylor

INVOICE

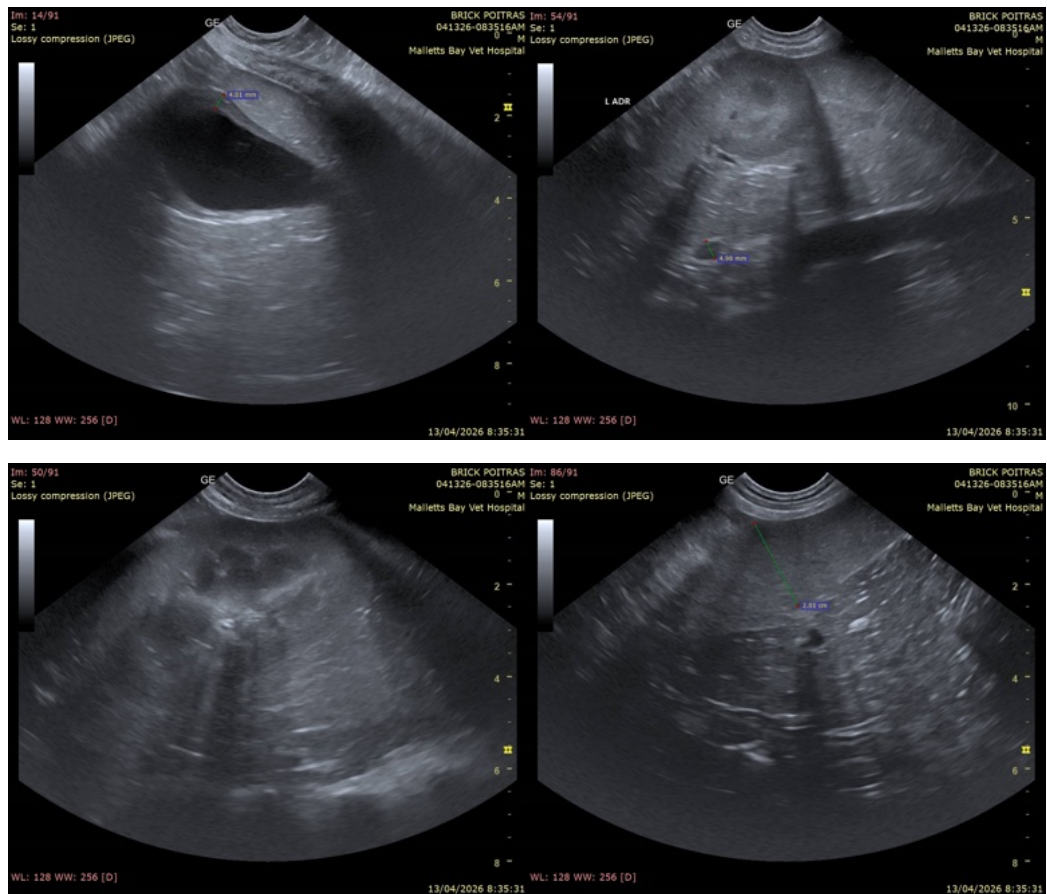
74421

DATE

4/13/26

- At this stage, a structured weight management plan is recommended, as the increased cranial abdominal volume is most likely attributable to excess fat accumulation.
- Given the absence of supportive ultrasonographic findings and lack of biochemical abnormalities (including liver enzyme elevations), hyperadrenocorticism appears less likely; however, if clinical suspicion persists, endocrine testing may be considered at the clinician's discretion.
- Clinical monitoring is advised, with reassessment should clinical signs progress or fail to improve with weight management.

Final diagnostic and therapeutic decisions should be made by the attending veterinarian, who can best integrate these findings with the patient's clinical status.





PATIENT

Brick Poitras

SPECIES

Canine

BREED

Mix

SEX

Neutered male

AGE

13 years

WEIGHT

66 lbs

INTERPRETED BY

Alicia Angosto
Guerrero, DMV,
PgDip, MSc.

IMAGING PERFORMED BY

Lexi Naylor

HOSPITAL NAME

Malletts Bay VH

REFERRING VET

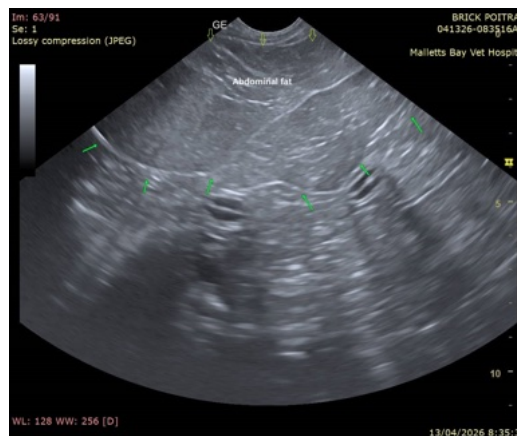
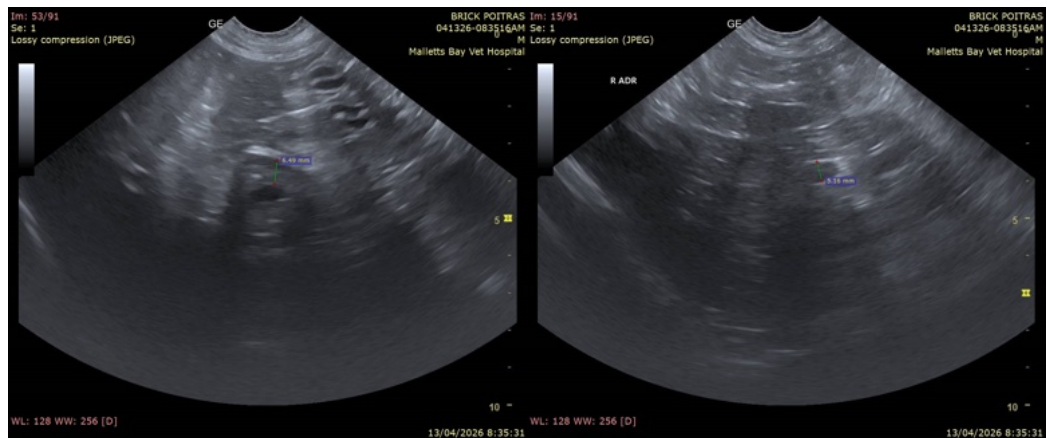
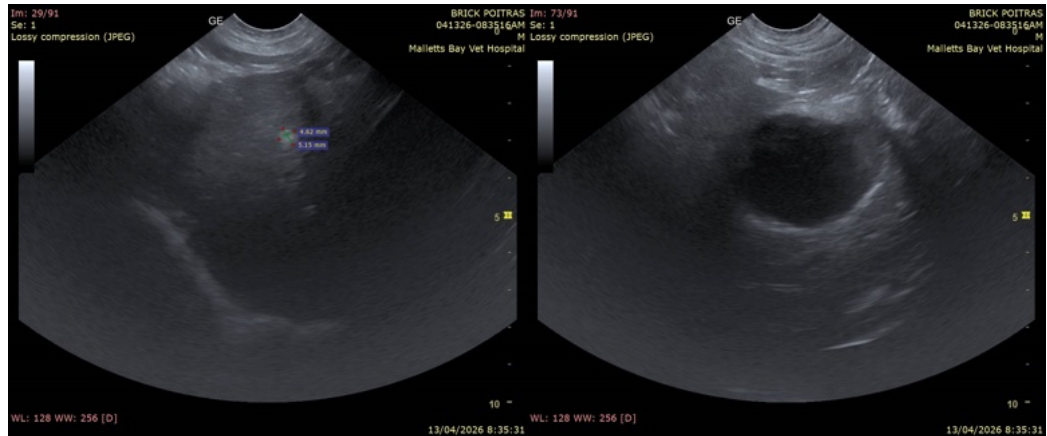
Dr. Naylor

INVOICE

74421

DATE

4/13/26



The information and recommendations provided are based on the images presented by the referring veterinarian/sonographer. No evaluation can be communicated regarding pathology that was not visible in the image/video clips provided.

Thank you for this referral. If the clinical or image interpretation does not parallel your findings or if I can be of any further assistance please contact me.



PATIENT

Alicia Angosto Guerrero, DMV, PgDip, MSc.

Brick Poitras

info@SonoPath.com

SPECIES

Canine

BREED

Mix

SEX

Neutered male

AGE

13 years

WEIGHT

66 lbs

INTERPRETED BY

Alicia Angosto
Guerrero, DMV,
PgDip, MSc.

**IMAGING
PERFORMED BY**

Lexi Naylor

HOSPITAL NAME

Malletts Bay VH

REFERRING VET

Dr. Naylor

INVOICE

74421

DATE

4/13/26