



PATIENT

Lori C2336 Animals in Distress

SPECIES

Feline

BREED

Domestic Shorthair

SEX

Spayed female

AGE

12 ½ years

WEIGHT

7 lbs

INTERPRETED BY

Alicia Angosto
Guerrero, DMV,
PgDip, MSc.

IMAGING PERFORMED BY

Renee Ziegler Post

HOSPITAL NAME

For Cats Only VC

REFERRING VET

Dr. Ziegler Post

INVOICE

74035

DATE

4/1/26

PRESENTING CLINICAL SIGNS

- Recent weight loss, Sept 16 2025 9.06lbs, April 1st 2026 7.01lbs
- Lethargy, odd behavior, laying in urine.
- Vomiting with trace blood.
- Granulocytic leukocytosis 26.08 - has been elevated T4 2.3

ULTRASONOGRAPHIC EXAMINATION OF THE ABDOMEN

Urinary System

The urinary bladder is normally distended. The bladder wall is thin, smooth, and regular. The luminal contents are predominantly anechoic with scant suspended echoes. Normal appearance of the bladder neck and proximal urethra. No evidence of urolithiasis or inflammatory or proliferative changes is identified.

The left kidney is normal in shape and size, measuring 3.68×1.59 cm in the sagittal plane. Cortical thickness was not obtained. The cortex is isoechoic compared to the hepatic parenchyma. The corticomedullary ratio is within normal limits, and corticomedullary definition is preserved. There is no evidence of pyelectasia, nephrolithiasis, or hydronephrosis. Color Doppler demonstrates a normal vascular pattern.

The right kidney is normal in shape and size, measuring 3.81×1.52 cm in the sagittal plane. Cortical thickness is 0.30 cm. The cortex is isoechoic compared to the hepatic parenchyma. The corticomedullary ratio is within normal limits, and corticomedullary definition is preserved. There is no evidence of pyelectasia, nephrolithiasis, or hydronephrosis. Color Doppler demonstrates a normal vascular pattern.

Adrenal Glands

Both adrenal glands show normal shape and echogenicity. Dorsoventral diameters measured in the sagittal plane: The left adrenal gland measures 0.21 cm at the cranial pole and 0.20 cm at the caudal pole. The right adrenal gland measures 0.21 cm at the cranial pole and 0.21 cm at the caudal pole.

Spleen

Splenic thickness is 0.79 cm. The parenchyma demonstrates normal echogenicity and fine homogeneous echotexture without focal parenchymal abnormalities. The splenic capsule is smooth and regular. Splenic vasculature appears normal.

Liver

The liver is subjectively normal in size, with sharp margins and a regular contour. The hepatic parenchyma is homogeneous and isoechoic relative to the falciform fat, with a normal echotexture. No focal lesions or hepatic lymphadenopathy are identified.

The gallbladder is normally distended. The wall is thin and regular. The luminal contents are anechoic. The common bile duct measures 3.86–3.47–2.47–2.27 mm along its course.



PATIENT

Lori C2336 Animals in Distress

SPECIES

Feline

BREED

Domestic Shorthair

SEX

Spayed female

AGE

12 ½ years

WEIGHT

7 lbs

INTERPRETED BY

Alicia Angosto Guerrero, DMV, PgDip, MSc.

IMAGING PERFORMED BY

Renee Ziegler Post

HOSPITAL NAME

For Cats Only VC

REFERRING VET

Dr. Ziegler Post

INVOICE

74035

DATE

4/1/26

Gastrointestinal

The stomach is empty and folded, with a wall thickness of 1.87 mm and preserved layering. The pylorus was not measured.

Duodenum: 2.32 mm. Jejunum: total wall thickness 3.03 mm, with mucosa 1.90 mm, submucosa 0.64 mm, and muscularis propria 0.48 mm. Ileum: total wall thickness 2.85 mm, with mucosa 0.93 mm, submucosa 0.99 mm, and muscularis propria 0.89 mm. Wall layering is preserved. A segment of small intestine shows increased wall thickness up to 3.55 mm, with muscularis thickness measuring 1.53 mm. The ileocecal junction measures 3.09 mm, with muscularis thickness of 0.89 mm.

Colon: 0.66 mm, containing formed feces in the descending segment.

Pancreas

The evaluated pancreatic areas do not show evidence of overt inflammation or neoplastic disease.

Free Abdomen

No abdominal effusion or signs of peritonitis are present.

Cranial mesenteric lymph nodes measure 7.73 mm, with normal shape and echogenicity.

Ileocecal lymph nodes are not visualized; the surrounding region appears unremarkable.

The region of the iliac trifurcation appears normal.

PRIMARY FINDINGS

- Segmental small intestinal thickening with marked muscularis thickening.
- Ileal muscularis thickening
- Mild enlargement of cranial mesenteric lymph nodes (7.73 mm).

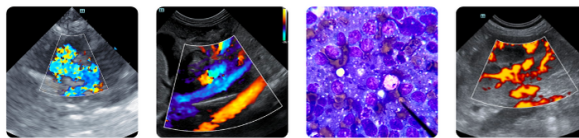
SECONDARY FINDINGS

- Mildly increased common bile duct diameter.

INTERPRETATION OF THE FINDINGS & FURTHER RECOMMENDATIONS

The most relevant finding is segmental small intestinal thickening with marked muscularis expansion, reaching 1.53 mm in one segment. This results in a muscularis-to-mucosa ratio approaching or exceeding 1, which is abnormal in cats. Additionally, the ileum shows muscularis thickening, further supporting a muscularis-predominant pattern.

These findings are consistent with chronic enteropathy, including both inflammatory bowel disease and low-grade (small cell) lymphoma, which cannot be reliably differentiated based on ultrasonographic appearance alone. The presence of segmental involvement, relatively increased muscularis thickness, and the clinical history of weight loss, leukocytosis, and vomiting indicate that this is a clinically



PATIENT

Lori C2336 Animals in Distress

SPECIES

Feline

BREED

Domestic Shorthair

SEX

Spayed female

AGE

12 ½ years

WEIGHT

7 lbs

INTERPRETED BY

Alicia Angosto Guerrero, DMV, PgDip, MSc.

IMAGING PERFORMED BY

Renee Ziegler Post

HOSPITAL NAME

For Cats Only VC

REFERRING VET

Dr. Ziegler Post

INVOICE

74035

DATE

4/1/26

significant process. However, there is considerable overlap between inflammatory and infiltrative conditions in cats, and no definitive distinction can be made based on imaging alone.

Cranial mesenteric lymph nodes are mildly enlarged (7.73 mm; typical feline reference $\leq 5-6$ mm) but retain normal morphology. This does not confirm lymphomatous involvement but does not exclude early or low-grade infiltration.

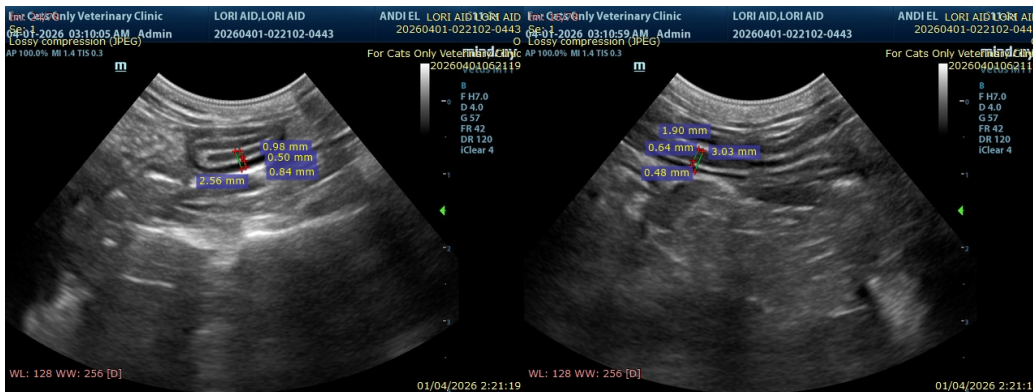
The common bile duct measures up to 3.86 mm, representing a mild increase in diameter for a feline patient. This may reflect mild variation in biliary flow in the context of gastrointestinal disease; however, in the absence of intrahepatic biliary dilation or gallbladder abnormalities, there is no ultrasonographic evidence of clinically significant cholestasis.

The pancreas appears unremarkable, although concurrent pancreatitis cannot be excluded.

Recommendations

- Intestinal biopsy is recommended for definitive diagnosis.
- Consider performing a gastrointestinal panel.
- Empirical treatment: Antiemetics, supportive care, strict dietary trial (hydrolyzed or novel protein) and cobalamine supplementation. Empirical immunomodulatory therapy may be considered.

Final diagnostic and therapeutic decisions should be made by the attending veterinarian, who can best integrate these findings with the patient's clinical status.





PATIENT

Lori C2336 Animals in Distress

SPECIES

Feline

BREED

Domestic Shorthair

SEX

Spayed female

AGE

12 ½ years

WEIGHT

7 lbs

INTERPRETED BY

Alicia Angosto Guerrero, DMV, PgDip, MSc.

IMAGING PERFORMED BY

Renee Ziegler Post

HOSPITAL NAME

For Cats Only VC

REFERRING VET

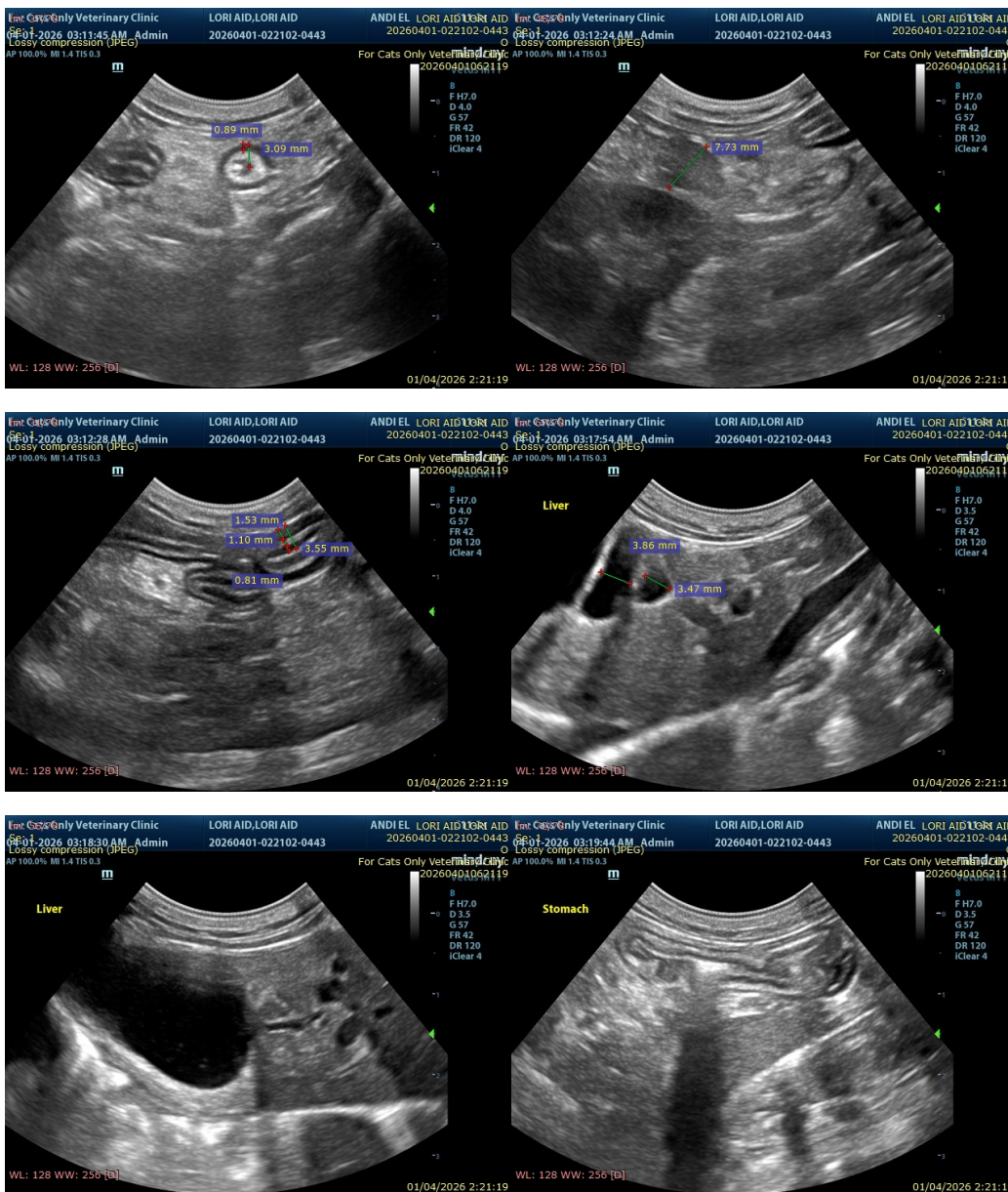
Dr. Ziegler Post

INVOICE

74035

DATE

4/1/26





PATIENT

Lori C2336 Animals in Distress

SPECIES

Feline

BREED

Domestic Shorthair

SEX

Spayed female

AGE

12 ½ years

WEIGHT

7 lbs

INTERPRETED BY

Alicia Angosto Guerrero, DMV, PgDip, MSc.

IMAGING PERFORMED BY

Renee Ziegler Post

HOSPITAL NAME

For Cats Only VC

REFERRING VET

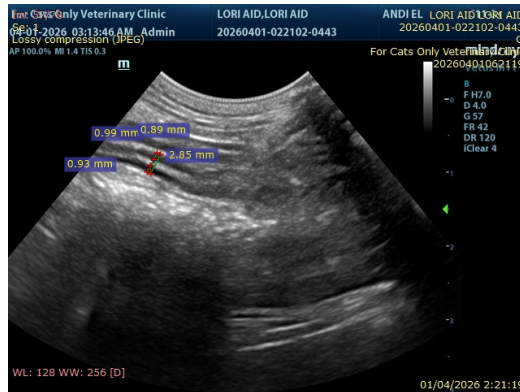
Dr. Ziegler Post

INVOICE

74035

DATE

4/1/26



The information and recommendations provided are based on the images presented by the referring veterinarian/sonographer. No evaluation can be communicated regarding pathology that was not visible in the image/video clips provided.

Thank you for this referral. If the clinical or image interpretation does not parallel your findings or if I can be of any further assistance please contact me.

Alicia Angosto Guerrero, DMV, PgDip, MSc.

info@SonoPath.com