



## PATIENT

Nini Burton

## SPECIES

Bearded Dragon

## BREED

Central Bearded Dragon

## SEX

Female

## AGE

1 Year

## WEIGHT

0.31 kg

## INTERPRETED BY

Alicia Angosto  
Guerrero, DMV,  
PgDip, MSc.

## IMAGING PERFORMED BY

Dr. Clinton Wayland

## HOSPITAL NAME

Wilvet South

## REFERRING VET

Dr. Clinton Wayland

## INVOICE

73476

## DATE

3/8/26

## PRESENTING CLINICAL SIGNS

Noticed she was starting to act off. Hiding a lot, not basking. Just hanging out in the hide. Would offer an insect, she would eat it, bask for a moment. That lasted about a week. Tried again the bait situation, but this time refused, which has never happened before. Made an appt at rDVM due concern for reproductive activity. No male present but could be infertile eggs. Did take her in and they did X-Rays and they found follicles.

Abnormal PE/Chem/CBC/UA Results: Patient presents as a referral from rDVM for an abdominal ultrasound. There is concern that the patient may be gravid or have retained eggs. The physical exam was entirely unremarkable.

## ULTRASONOGRAPHIC EXAMINATION OF THE ABDOMEN

### Urinary System

The cloaca and the kidneys were not reliably visualized in the provided images.

In this species, the kidneys are located very caudally within the coelomic cavity, deep within the pelvic canal near the base of the tail, which may limit ultrasonographic visualization depending on the scanning window.

### Reproductive System

Both ovaries contain multiple vitellogenic follicles in advanced stages of maturation, measuring approximately 1.19×1.12 cm and 1.21×1.05 cm.

Several follicles demonstrate mildly irregular or distorted margins with focal hyperechoic areas within the yolk material, resulting in a heterogeneous yolk appearance.

Additionally, small anechoic follicles consistent with early previtellogenic follicles may be present; however, confirmation with color Doppler evaluation would be recommended to better characterize vascular activity and follicular status.

### Spleen

In small reptiles, the spleen is typically small and located immediately dorsal to the stomach or pylorus. Visualization may be challenging unless enlarged. In this case, the spleen was not definitively identified.

### Liver

The liver is subjectively normal in size, with sharp margins and a regular contour. The hepatic parenchyma demonstrates normal echogenicity and echotexture.

The gallbladder was not clearly visualized during this examination.

### Gastrointestinal

The stomach is distended with ingesta, although in a lower volume than typically expected in Pogona species, which may correlate with the reported hyporexia.

- Gastric wall thickness: 0.81 mm
- Pyloric wall thickness: 2.14 mm

Both measurements are within expected limits.



## PATIENT

Nini Burton

## SPECIES

Bearded Dragon

## BREED

Central Bearded Dragon

## SEX

Female

## AGE

1 Year

## WEIGHT

0.31 kg

## INTERPRETED BY

Alicia Angosto  
Guerrero, DMV,  
PgDip, MSc.

## IMAGING PERFORMED BY

Dr. Clinton Wayland

## HOSPITAL NAME

Wilvet South

## REFERRING VET

Dr. Clinton Wayland

## INVOICE

73476

## DATE

3/8/26

Small intestinal wall thickness measures up to 1.33 mm, which is within normal limits for this species.

### ***Fat Bodies***

Fat bodies measure 1.46 cm and 1.29 cm in thickness. No sonographic abnormalities are identified.

### ***Coelomic Cavity***

Anechoic free fluid is present within the gonadal recesses. Additional small-volume coelomic fluid is identified within the hepato-pericardial recess.

### **PRIMARY FINDINGS**

- Persistent vitellogenic follicles with recruitment of additional follicles.

Few follicles demonstrate:

- Mild margin irregularity.
- Heterogeneous yolk echogenicity (mottled yolk pattern).
- Small-volume coelomic fluid within the gonadal recesses and hepato-pericardial recess.

### **INTERPRETATION OF THE FINDINGS & FURTHER RECOMMENDATIONS**

The ovaries contain multiple advanced-stage vitellogenic follicles, indicating active reproductive follicular development. Although this finding in adult female bearded dragons may represent physiologic reproductive cycling, the constellation of findings in this case and the clinical history of behavioral changes, further supports the suspicion of a reproductive disorder such as follicular stasis.

A few follicles demonstrate mild margin irregularity and focal areas of increased echogenicity within the yolk, resulting in a heterogeneous or mottled yolk appearance. These findings may represent early degenerative changes within persistent vitellogenic follicles, which have been described in association with follicular stasis.

Small anechoic follicles consistent with early previtellogenic follicles may also be present. The concurrent presence of developing previtellogenic follicles while advanced vitellogenic follicles remain within the ovary may suggest asynchronous follicular development, which can be observed in cases of follicular stasis, although it may also occur in clinically normal animals producing multiple clutches during the same reproductive season.

The presence of anechoic fluid within the gonadal recesses and a small volume of coelomic fluid may be observed physiologically in healthy reptiles. However, in the appropriate clinical context, these findings may also be associated with early coelomitis secondary to follicular stasis or inflammatory reproductive disease.

No ultrasonographic evidence of follicular rupture or ovarian rupture is identified.

Recommendations:

- Correlation with clinical examination, husbandry conditions, and dietary history is recommended, as these factors can significantly influence reproductive cycling in captive bearded dragons.
- In some cases, coelomic fluid sampling and analysis may be performed to evaluate coelomitis prior to considering surgical intervention. However, in this patient, ultrasound-guided aspiration may carry



**PATIENT**

Nini Burton

**SPECIES**

Bearded Dragon

**BREED**

Central Bearded Dragon

**SEX**

Female

**AGE**

1 Year

**WEIGHT**

0.31 kg

**INTERPRETED BY**

Alicia Angosto  
Guerrero, DMV,  
PgDip, MSc.

**IMAGING PERFORMED BY**

Dr. Clinton Wayland

**HOSPITAL NAME**

Wilvet South

**REFERRING VET**

Dr. Clinton Wayland

**INVOICE**

73476

**DATE**

3/8/26

increased risk, as the volume of fluid is limited and there is potential for inadvertent puncture of the ovary or adjacent follicles.

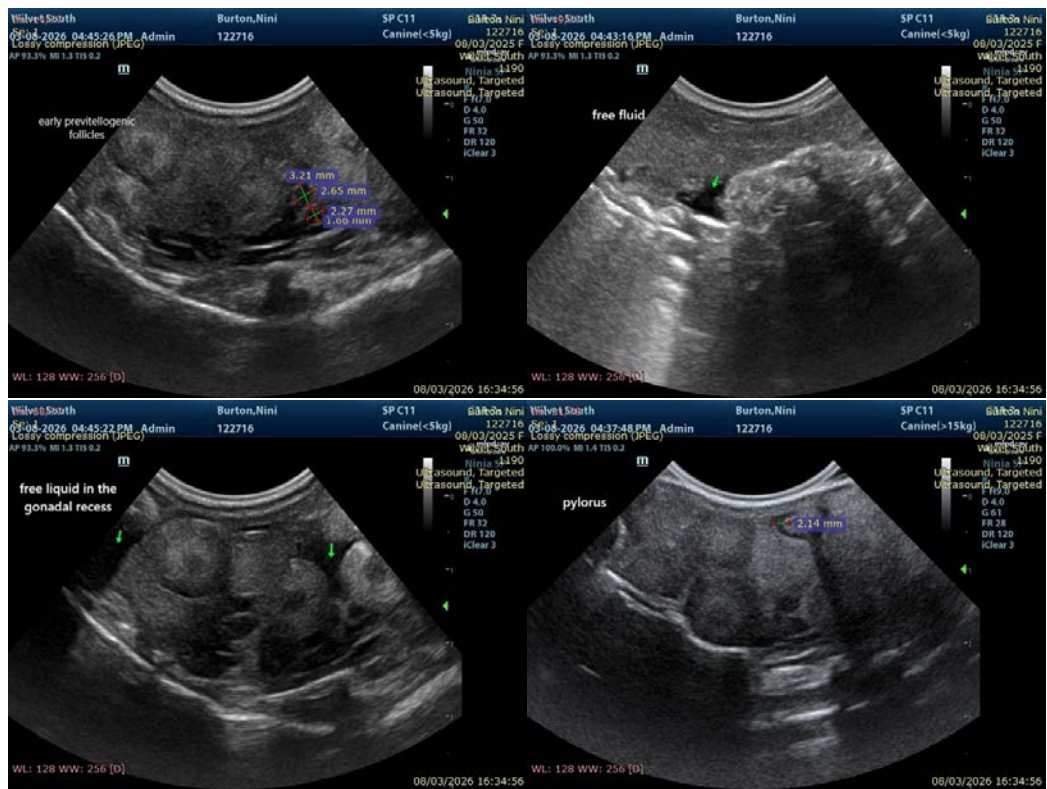
Two potential management approaches may be considered:

1. Conservative management.

Attempt to stimulate ovulation through optimization of husbandry conditions (appropriate thermal gradient, UVB exposure, photoperiod, nutritional support, and provision of a suitable nesting substrate). Close clinical and ultrasonographic monitoring over the following week is recommended. If ovulation or follicular regression does not occur, surgical management may be required.

2. Surgical management.

Elective ovariosalpingectomy may be considered while the patient remains clinically stable, at the discretion of the attending veterinarian.





**PATIENT**

Nini Burton

**SPECIES**

Bearded Dragon

**BREED**

Central Bearded Dragon

**SEX**

Female

**AGE**

1 Year

**WEIGHT**

0.31 kg

**INTERPRETED BY**

Alicia Angosto Guerrero, DMV, PgDip, MSc.

**IMAGING PERFORMED BY**

Dr. Clinton Wayland

**HOSPITAL NAME**

Wilvet South

**REFERRING VET**

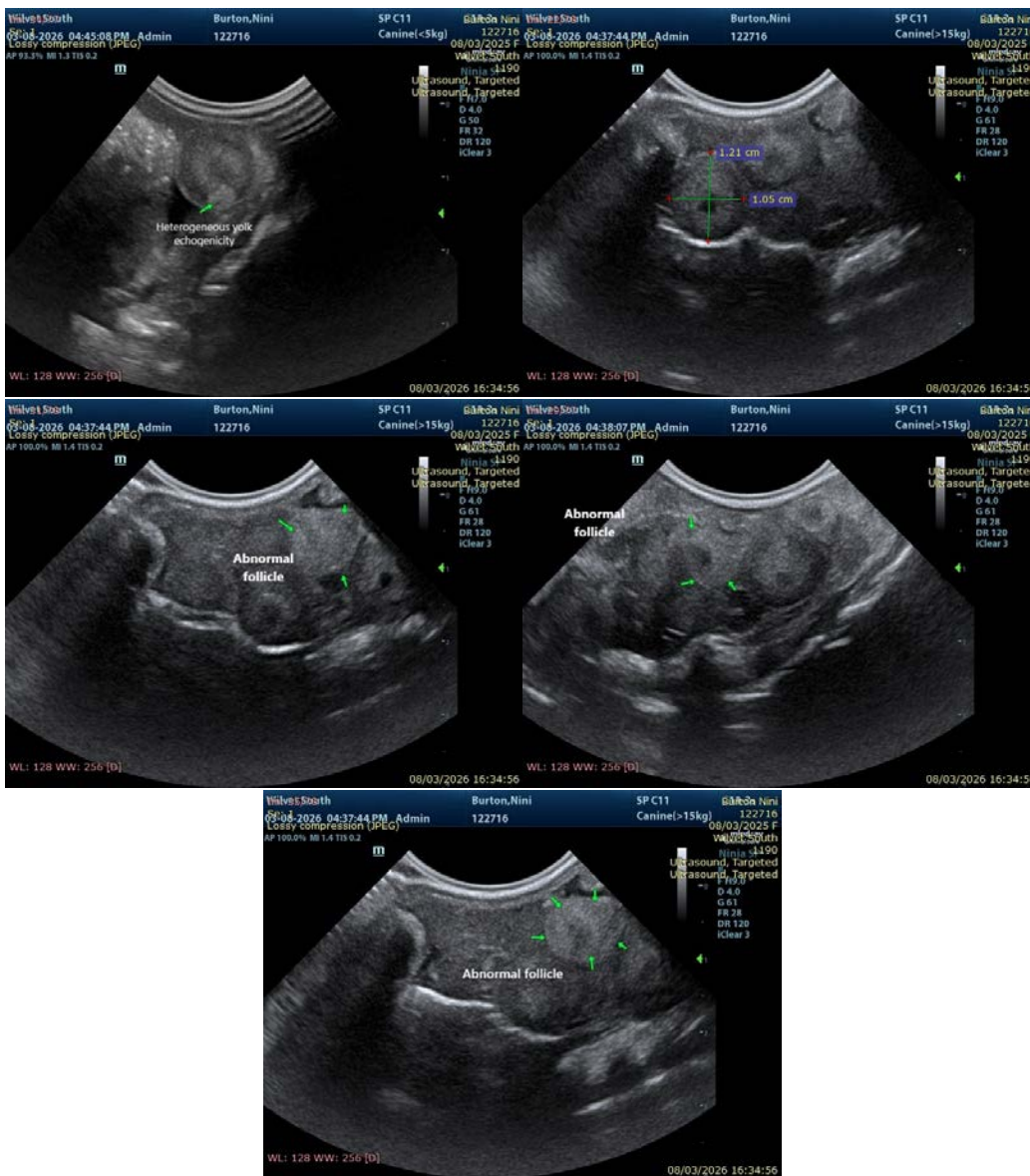Dr. Clinton Wayland

**INVOICE**

73476

**DATE**

3/8/26



The information and recommendations provided are based on the images presented by the referring veterinarian/sonographer. No evaluation can be communicated regarding pathology that was not visible in the image/video clips provided.

Thank you for this referral. If the clinical or image interpretation does not parallel your findings or if I can be of any further assistance please contact me.

Alicia Angosto Guerrero, DMV, PgDip, MSc.

[info@SonoPath.com](mailto:info@SonoPath.com)