



PATIENT

Marshmallow Carmona

SPECIES

Feline

BREED

Domestic Medium Hair

SEX

Neutered Male

AGE

9

WEIGHT

11.4

INTERPRETED BY

Alicia Angosto
Guerrero, DMV,
PgDip, MSc.

IMAGING PERFORMED BY

Dr. Janjusevic

HOSPITAL NAME

Camden Pet Hospital

REFERRING VET

Dr. Jelena

INVOICE

73369

DATE

3/3/26

PRESENTING CLINICAL SIGNS

Hx of inappetence, lethargy and weight loss (~ 3 Lbs over 8 month). Hx of URI

Abnormal PE/Chem/CBC/UA Results: On PE - arox 5% dehydrated, mild to moderate periodontal dz, congested with ocular discharge labs - CBC: hemo 10.4, WBC 20.1, neuts 16080, mono 663, rest wnl
Chem: cystatin B 159, Ca 8.1, Na 146, TP 11.6, Alb 2.2, Glob 9.4, alb:glob ratio 0.2 USG 1.049, UP 2+ TT4 - 1.6 spec fPL - normal URI PCR - negative

ULTRASONOGRAPHIC EXAMINATION OF THE ABDOMEN

Urinary System

The urinary bladder is normally distended, and the wall appears thin and smooth. The urine is turbid with abundant suspended echoes. The bladder neck and proximal urethra have a normal ultrasonographic appearance. No uroliths or sonographic evidence of mural inflammatory or neoplastic changes are identified.

The left kidney is normal in shape and size, measuring 4.31×2.63 cm, with cortical thickness measuring 0.37 cm in the sagittal plane. The cortex is isoechoic relative to the liver parenchyma. The corticomedullary ratio is normal and corticomedullary definition is preserved. No pyelectasia, nephrolithiasis, or hydronephrosis is identified.

The right kidney is normal in shape and size, measuring 4.01×2.53 cm, with cortical thickness measuring 0.40 cm in the sagittal plane. The cortex is isoechoic relative to the liver parenchyma. The corticomedullary ratio is normal and corticomedullary definition is preserved. No pyelectasia, nephrolithiasis, or hydronephrosis is identified.

Adrenal Glands

Dorsoventral diameters measured in the sagittal plane: The left adrenal gland measures 0.37 cm at the cranial pole and 0.31 cm at the caudal pole.

The right adrenal gland was not clearly visualized.

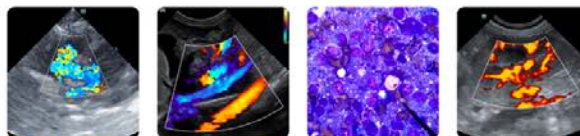
Spleen

Splenic thickness measures 0.84 cm. The splenic parenchyma demonstrates normal echogenicity and fine homogeneous echotexture without focal abnormalities. The splenic capsule is smooth and regular.

Liver

A solid hepatic mass measuring approximately 3.56×4.39 cm (largest measurements from three obtained) is identified in the region of the left hepatic lobes, most likely the left medial lobe. The mass is heterogeneous and appears infiltrative, causing distortion of the surrounding hepatic architecture. Vascular involvement cannot be assessed on the submitted images.

An additional hepatic nodule measuring 1.18×1.32 cm is identified within one of the right hepatic lobes, demonstrating similar echogenicity and echotexture to the primary mass.



PATIENT

Marshmallow Carmona

SPECIES

Feline

BREED

Domestic Medium Hair

SEX

Neutered Male

AGE

9

WEIGHT

11.4

INTERPRETED BY

Alicia Angosto
Guerrero, DMV,
PgDip, MSc.

IMAGING PERFORMED BY

Dr. Janjusevic

HOSPITAL NAME

Camden Pet Hospital

REFERRING VET

Dr. Jelena

INVOICE

73369

DATE

3/3/26

Aside from these lesions, the remaining liver parenchyma appears homogeneous and isoechoic relative to the falciform fat. The liver is subjectively normal in size with sharp margins and regular contour. No hepatic lymphadenopathy is identified.

The gallbladder is normally distended. The wall is thin and the contents are predominantly anechoic with a small amount of biliary sludge. No dilation of the cystic duct or common bile duct is observed.

Gastrointestinal

The stomach is mostly empty with a small amount of partially digested ingesta. Gastric wall thickness measures 1.77–2.01 mm with preserved wall layering.

Duodenum: 1.76 mm.
Jejunum: 2.11–2.42 mm.
Ileum: 1.86 mm.

Wall layering is preserved throughout the small intestinal segments examined.

No sonographic evidence of ileus, obstruction, or intraluminal foreign material is identified.

Colon: transverse 1.41 mm, descending 0.83 mm, with formed feces in the descending colon.

Pancreas

The evaluated pancreatic regions do not show sonographic evidence of overt inflammation or focal mass lesions.

Free Abdomen

No abdominal effusion is identified. The omentum adjacent to the hepatic mass appears hyperechoic. No sonographic evidence of generalized peritonitis or abdominal lymphadenomegaly is identified. The iliac trifurcation appears normal.

PRIMARY FINDINGS

- Large heterogeneous hepatic mass.
- Additional hepatic nodule within the right hepatic division, with similar echogenicity.

SECONDARY FINDINGS

- Focal hyperechogenicity of the adjacent omental fat, compatible with regional reactive/inflammatory change.
- Abundant echogenic urinary sediment within the urinary bladder lumen.

INTERPRETATION OF THE FINDINGS & FURTHER RECOMMENDATIONS

The most significant finding is a large heterogeneous hepatic mass located within the left hepatic lobes, most likely the left medial lobe, together with a smaller hepatic nodule within a right hepatic lobe displaying identical echogenicity and echotexture. Primary differential considerations include



PATIENT

Marshmallow Carmona

SPECIES

Feline

BREED

Domestic Medium Hair

SEX

Neutered Male

AGE

9

WEIGHT

11.4

INTERPRETED BY

Alicia Angosto
Guerrero, DMV,
PgDip, MSc.

IMAGING PERFORMED BY

Dr. Janjusevic

HOSPITAL NAME

Camden Pet Hospital

REFERRING VET

Dr. Jelena

INVOICE

73369

DATE

3/3/26

multifocal primary hepatic neoplasia (hepatocellular carcinoma or cholangiocarcinoma), or lymphoma.

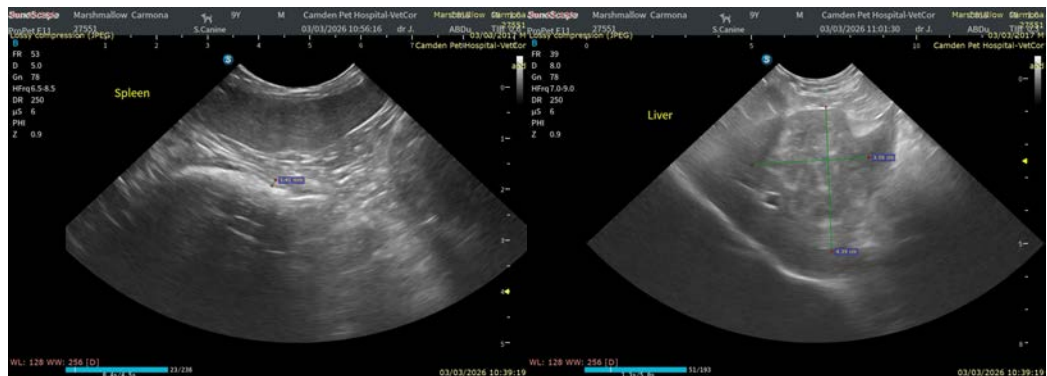
The localized increase in echogenicity of the omental fat adjacent to the hepatic mass suggests regional reactive change, which may occur secondary to local inflammation, capsular irritation, or tumor interaction with surrounding tissues. No generalized peritonitis or abdominal effusion is identified.

Given the patient's marked hyperglobulinemia and markedly decreased albumin-to-globulin ratio, systemic diseases associated with hepatic infiltration should also be considered. In particular, lymphoma or inflammatory granulomatous disease (including dry-form feline infectious peritonitis) remain differential considerations in this clinical context.

Overall, the findings are most consistent with significant hepatic disease characterized by a dominant hepatic mass and an additional hepatic nodule, with malignant hepatic neoplasia considered the most likely underlying process, although infiltrative systemic disease cannot be definitively excluded based on ultrasound alone.

Recommendations:

- Ultrasound-guided fine-needle aspiration of the hepatic mass and hepatic nodule is strongly recommended for cytologic characterization.
- Sampling of the enlarged hepatic lesion should be performed with appropriate coagulation assessment prior to the procedure, if clinically indicated.
- Further staging may be considered, including thoracic imaging, depending on cytologic results.





PATIENT

Marshmallow Carmona

SPECIES

Feline

BREED

Domestic Medium Hair

SEX

Neutered Male

AGE

9

WEIGHT

11.4

INTERPRETED BY

Alicia Angosto
Guerrero, DMV,
PgDip, MSc.

**IMAGING
PERFORMED BY**

Dr. Janjusevic

HOSPITAL NAME

Camden Pet Hospital

REFERRING VET

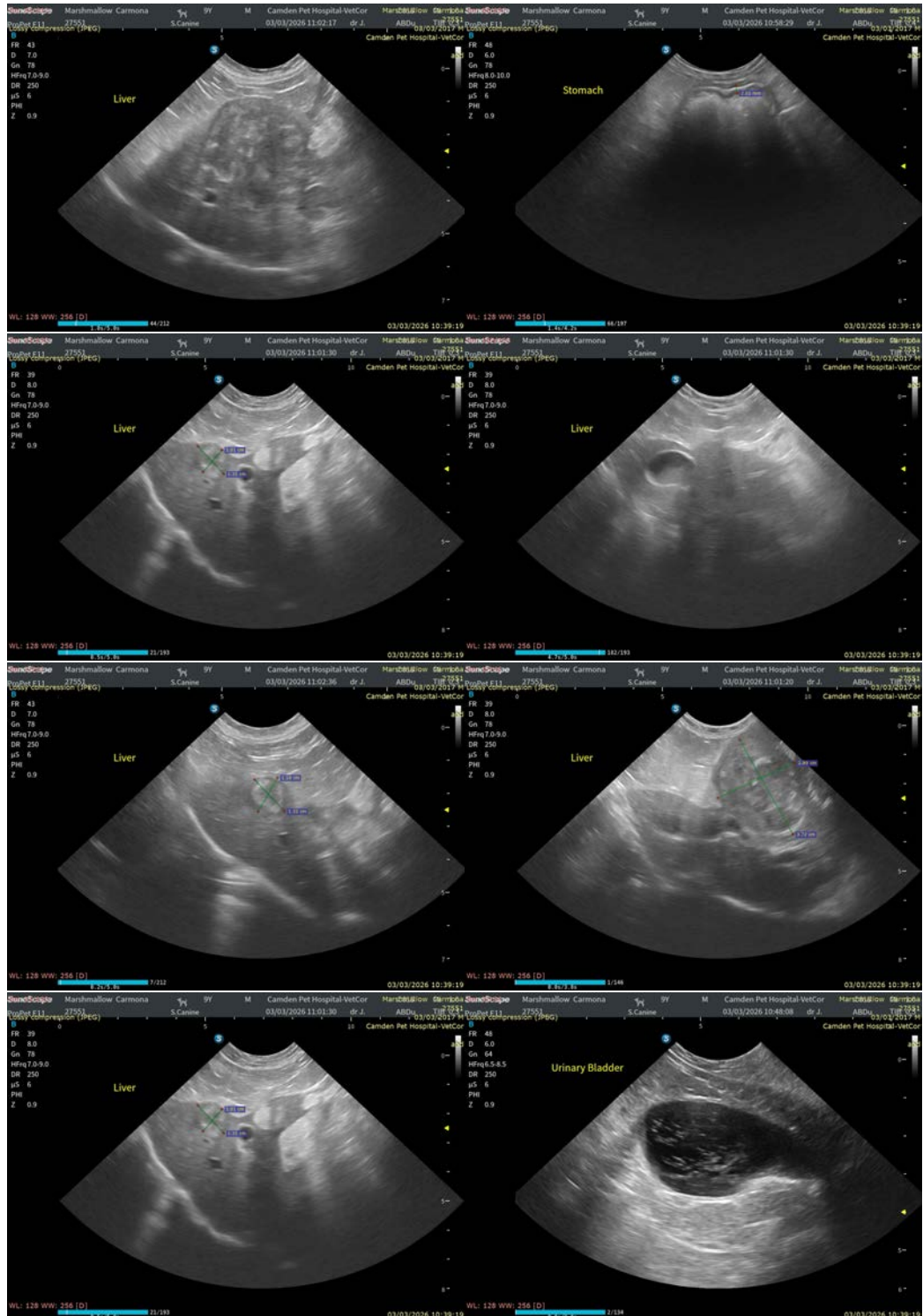
Dr. Jelena

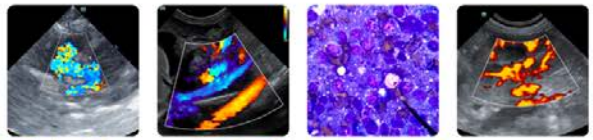
INVOICE

73369

DATE

3/3/26





PATIENT

Marshmallow Carmona

SPECIES

Feline

BREED

Domestic Medium Hair

SEX

Neutered Male

AGE

9

WEIGHT

11.4

INTERPRETED BY

Alicia Angosto
Guerrero, DMV,
PgDip, MSc.

IMAGING PERFORMED BY

Dr. Janjusevic

HOSPITAL NAME

Camden Pet Hospital

REFERRING VET

Dr. Jelena

INVOICE

73369

DATE

3/3/26

The information and recommendations provided are based on the images presented by the referring veterinarian/sonographer. No evaluation can be communicated regarding pathology that was not visible in the image/video clips provided.

Thank you for this referral. If the clinical or image interpretation does not parallel your findings or if I can be of any further assistance please contact me.

Alicia Angosto Guerrero, DMV, PgDip, MSc.

info@SonoPath.com