



## PATIENT

Clover Gouldey

## SPECIES

Feline

## BREED

Domestic Longhair

## SEX

Spayed Female

## AGE

14 ½ years

## WEIGHT

9 lbs

## INTERPRETED BY

Alicia Angosto  
Guerrero, DMV,  
PgDip, MSc.

## IMAGING PERFORMED BY

Renee Ziegler Post

## HOSPITAL NAME

For Cats VC

## REFERRING VET

Renee Ziegler Post

## INVOICE

78364

## DATE

3/27/26

## PRESENTING CLINICAL SIGNS

- Weight loss
- Previous vet suspected IBD. Occasional vomiting
- No current medications

## ULTRASONOGRAPHIC EXAMINATION OF THE ABDOMEN

### *Urinary System*

The urinary bladder is normally distended, with a thin and smooth wall. The urine is predominantly anechoic with scant suspended echoes. The bladder neck and proximal urethra have a normal appearance. No calculi or evidence of inflammatory or neoplastic changes are identified.

The left kidney is normal in shape and size: 4.07 × 1.92 cm, with a cortical thickness of 0.35 cm in the sagittal plane. The cortex is mildly hypoechoic compared to the liver parenchyma. The corticomedullary ratio is normal and corticomedullary definition is preserved. No pyelectasia, nephroliths, or hydronephrosis are identified. Color Doppler demonstrates a normal vascular pattern.

The right kidney is normal in shape and size: 3.97 × 1.89 cm. The cortex is mildly hypoechoic compared to the liver parenchyma. The corticomedullary ratio is normal and corticomedullary definition is preserved. No pyelectasia, nephroliths, or hydronephrosis are identified. Color Doppler demonstrates a normal vascular pattern.

### *Adrenal Glands*

Both adrenal glands show normal shape and echogenicity. Dorsoventral diameters measured in the sagittal plane: The left adrenal gland measures 0.30 cm at the cranial pole and 0.32 cm at the caudal pole. The right adrenal gland measures 0.27 cm at the cranial pole and 0.27 cm at the caudal pole.

### *Spleen*

Splenic thickness is 0.63 cm. The parenchyma demonstrates normal echogenicity and fine homogeneous echotexture without focal parenchymal abnormalities. The splenic capsule is smooth and regular.

### *Liver*

The liver is subjectively normal in size, with sharp edges and a regular contour. The parenchyma is homogeneous and isoechoic compared to the falciform fat, with a normal echotexture. No hepatic lymphadenopathy is identified.

The gallbladder is normally distended, with a thin wall. The contents are predominantly anechoic with a small amount of biliary sludge. The common bile duct measures approximately 2.55–1.20 mm from proximal to distal, within normal limits for a cat.



## PATIENT

Clover Gouldey

## SPECIES

Feline

## BREED

Domestic Longhair

## SEX

Spayed Female

## AGE

14 ½ years

## WEIGHT

9 lbs

## INTERPRETED BY

Alicia Angosto  
Guerrero, DMV,  
PgDip, MSc.

## IMAGING PERFORMED BY

Renee Ziegler Post

## HOSPITAL NAME

For Cats VC

## REFERRING VET

Renee Ziegler Post

## INVOICE

78364

## DATE

3/27/26

## Gastrointestinal

The stomach is empty and folded, with a mural thickness of 1.78 mm and preserved wall layering. The pylorus measures 3.49 mm. The duodenum measures 2.87 mm, with a small amount of luminal fluid. The duodenal papilla measures approximately 3.10×4.36 mm.

The jejunum measures 2.21–2.34 mm, with preserved wall layering (mucosa: 1.17 mm; submucosa: 0.61 mm; muscularis propria: 0.47 mm). The muscularis-to-mucosa ratio is approximately 0.40, within normal to mildly increased limits.

The ileum measures up to 2.80–3.37 mm, with segmental thickening predominantly affecting the muscularis layer, which measures approximately 1.33–1.40 mm at the ileocecal junction (mucosa ~0.74 mm). The muscularis-to-mucosa ratio is increased (~1.8–1.9). Wall layering remains preserved. No signs of obstruction, ileus, or foreign material are identified.

The colon measures 0.83 mm, with formed feces in the descending segment.

## Pancreas

The pancreas measures approximately 6.33 mm in thickness. The parenchyma is isoechoic to the adjacent omental fat. The pancreatic duct measures approximately 1.03 mm. No peripancreatic fat inflammation is identified.

## Free Abdomen

No sonographic evidence of abdominal effusion, peritonitis, or lymphadenomegaly is identified. The iliac trifurcation appears normal.

## PRIMARY FINDINGS

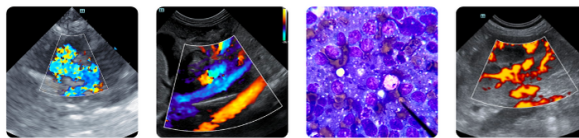
- Mild segmental ileal thickening with muscularis predominance.
- Mild jejunal muscularis prominence.

## SECONDARY FINDINGS

- Small amount of biliary sludge.

## INTERPRETATION OF THE FINDINGS & FURTHER RECOMMENDATIONS

The muscularis-to-mucosa ratio is mildly increased in the jejunum (~0.40) and markedly increased in the ileum (~1.8–1.9), supporting a pattern of muscularis-predominant thickening. In cats, this pattern is consistent with chronic enteropathy. In this case, segmental or diffuse muscularis thickening with preserved wall layering and no associated lymphadenopathy is identified. While this pattern is often described with inflammatory disease, overlap with inflammatory bowel disease and low-grade lymphoma exists, and ultrasound is not diagnostic.



**PATIENT**

Clover Gouldey

**SPECIES**

Feline

**BREED**

Domestic Longhair

**SEX**

Spayed Female

**AGE**

14 ½ years

**WEIGHT**

9 lbs

**INTERPRETED BY**

Alicia Angosto  
Guerrero, DMV,  
PgDip, MSc.

**IMAGING PERFORMED BY**

Renee Ziegler Post

**HOSPITAL NAME**

For Cats VC

**REFERRING VET**

Renee Ziegler Post

**INVOICE**

78364

**DATE**

3/27/26

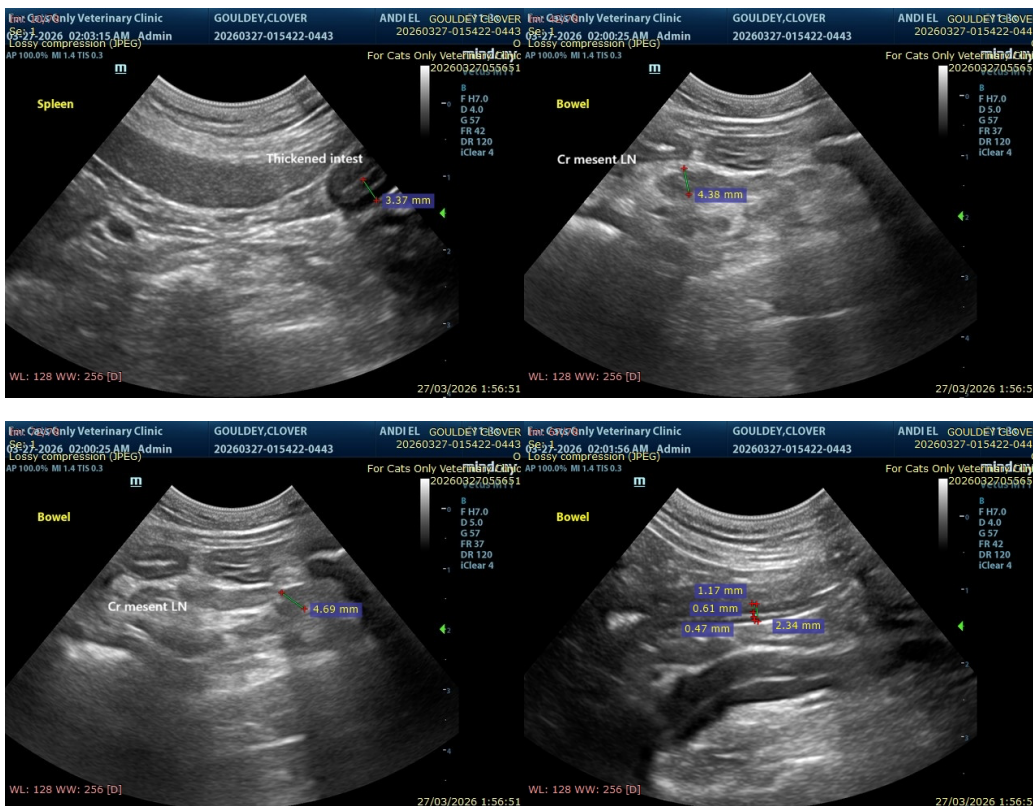
No ultrasonographic evidence of pancreatitis is identified; however, mild or chronic pancreatic involvement cannot be excluded based on ultrasound alone.

The hepatobiliary system is unremarkable aside from minimal sludge, with no evidence of clinically significant biliary obstruction.

**Recommendations**

- A stepwise approach is recommended, including a dietary trial (novel or hydrolyzed diet) and assessment of cobalamin and folate levels, with supplementation as indicated.
- Consider fPLI testing, as mild or chronic pancreatitis may be present despite unremarkable ultrasonographic findings.
- For a definitive diagnosis, intestinal biopsy is recommended to differentiate inflammatory disease from low-grade lymphoma.
- Re-evaluation is recommended based on clinical progression, particularly if weight loss or vomiting persists.

Final diagnostic and therapeutic decisions should be made by the attending veterinarian, who can best integrate these findings with the patient's clinical status.





**PATIENT**

Clover Gouldey

**SPECIES**

Feline

**BREED**

Domestic Longhair

**SEX**

Spayed Female

**AGE**

14 ½ years

**WEIGHT**

9 lbs

**INTERPRETED BY**

Alicia Angosto Guerrero, DMV, PgDip, MSc.

**IMAGING PERFORMED BY**

Renee Ziegler Post

**HOSPITAL NAME**

For Cats VC

**REFERRING VET**

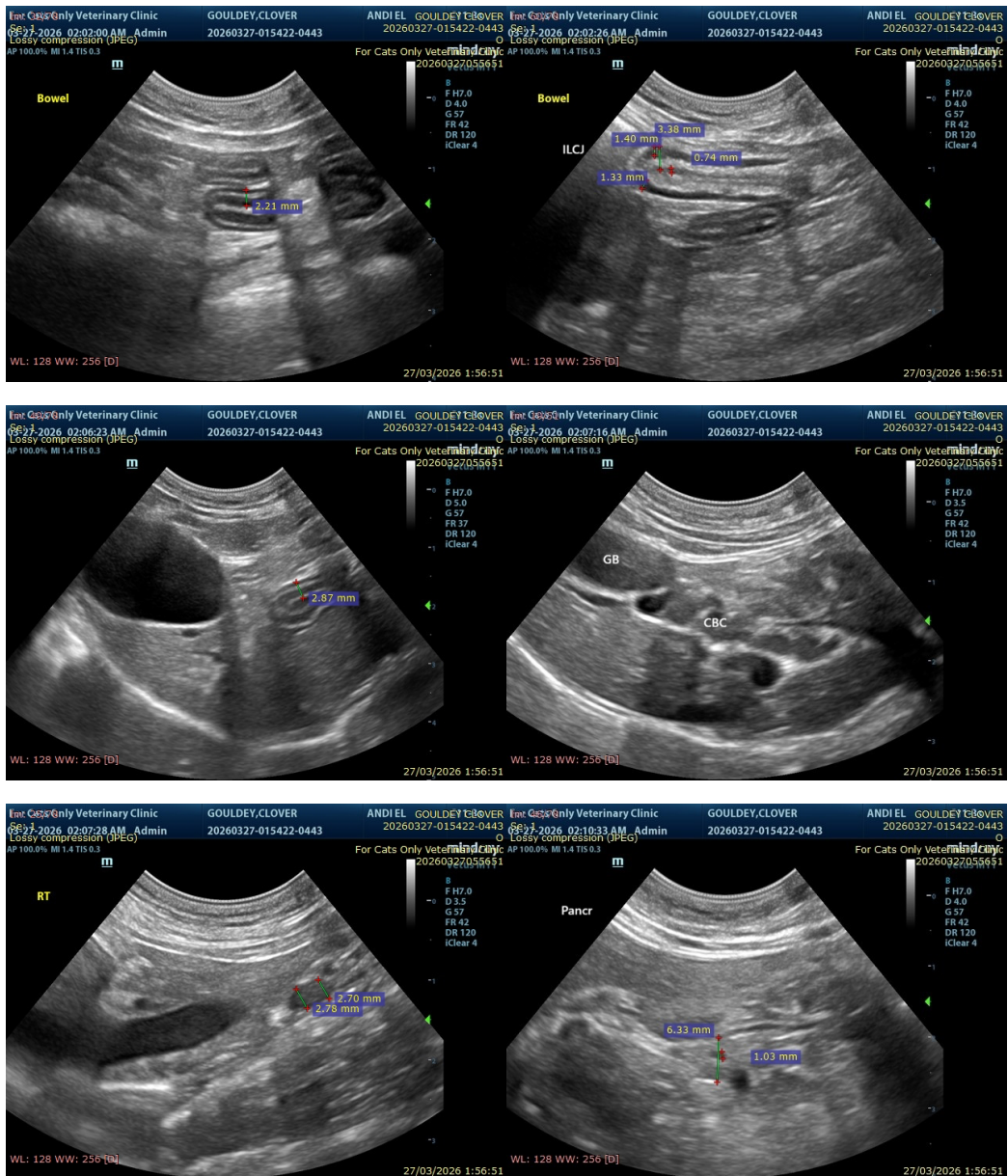
Renee Ziegler Post

**INVOICE**

78364

**DATE**

3/27/26



The information and recommendations provided are based on the images presented by the referring veterinarian/sonographer. No evaluation can be communicated regarding pathology that was not visible in the image/video clips provided.

Thank you for this referral. If the clinical or image interpretation does not parallel your findings or if I can be of any further assistance please contact me.

Alicia Angosto Guerrero, DMV, PgDip, MSc.

[info@SonoPath.com](mailto:info@SonoPath.com)