



PATIENT

Rocky Myer

SPECIES

Canine

BREED

Dachshund Mix

SEX

Neutered male

AGE

10 years

WEIGHT

37 lbs

INTERPRETED BY

Dr. Alicia Angosto
Guerrero

IMAGING PERFORMED BY

Mark Reser

HOSPITAL NAME

Harvest Hills VH

REFERRING VET

Dr. Reser

INVOICE

73817

DATE

3/25/26

PRESENTING CLINICAL SIGNS

Dog has been morbidly obese for a while. Has recently become more polyphagic and PU/PD. Otherwise normal

Obese, rounded abdomen. BW showed increasing liver enzymes, mostly ALP. (196 a year ago, 395 6 months ago and now is 1293). ALT has been normal until last labs and was 161. Rest of chem and CBC normal, UA showed dilute urine with mild proteinuria (1.8), and T4 was normal at 1.6. LDDST was normal and not consistent with Cushing's.

ULTRASONOGRAPHIC EXAMINATION OF THE ABDOMEN

Urinary System

The urinary bladder is normally distended. The wall appears thin and smooth. The urine is anechoic. The bladder neck and proximal urethra appear normal. No calculi or sonographic evidence of inflammatory or neoplastic changes are identified.

The left kidney is normal in shape and size, measuring 5.98×3.48 cm. Cortical thickness is 0.61 cm in the sagittal plane. A small cortical cyst measuring 1.82×1.86 mm is noted. The right kidney is normal in shape and size, measuring 6.27×3.42 cm. Cortical thickness is 0.65 cm in the sagittal plane. In both kidneys, the cortex is mildly hyperechoic compared to the liver parenchyma. The corticomedullary ratio and definition are preserved. No evidence of pyelectasia, nephrolithiasis, or hydronephrosis is identified. Color Doppler shows a normal vascular pattern.

Adrenal Glands

Dorsoventral diameters measured in the sagittal plane: the left adrenal gland measures 0.83 cm at the cranial pole and 0.67 cm at the caudal pole. Visualization of this gland was somewhat limited, which may affect measurement accuracy. The right adrenal gland measures 1.17 cm at the cranial pole and 1.09 cm at the caudal pole.

Spleen

Splenic thickness is 1.83 cm. The parenchyma demonstrates normal echogenicity and fine homogeneous echotexture without focal parenchymal abnormalities. The splenic capsule is smooth and regular. Splenic vasculature appears normal.

Liver

The liver is enlarged, with rounded margins and regular contour. The parenchyma is homogeneous and isoechoic relative to falciform fat, with normal echotexture. No hepatic lymphadenopathy is identified.

The gallbladder contains a moderate amount of echogenic, non-shadowing intraluminal material forming multiple, well-defined rounded to ovoid aggregates. These are variably echogenic with mild internal heterogeneity. No consistent distal acoustic shadowing is observed. The gallbladder wall is normal in thickness.



PATIENT

Rocky Myer

SPECIES

Canine

BREED

Dachshund Mix

SEX

Neutered male

AGE

10 years

WEIGHT

37 lbs

INTERPRETED BY

Dr. Alicia Angosto
Guerrero

IMAGING PERFORMED BY

Mark Reser

HOSPITAL NAME

Harvest Hills VH

REFERRING VET

Dr. Reser

INVOICE

73817

DATE

3/25/26

Gastrointestinal

The stomach contains a very small amount of ingesta, with a wall thickness of 1.78 mm and preserved layering. The pylorus measures 6.12 mm.

The duodenum measures 4.47 mm and the jejunum 4.21 mm. Wall layering is preserved. The ileocecal junction appears unremarkable.

No evidence of inflammation, ileus, or intraluminal foreign material is identified.

The colon measures 0.88–1.12 mm and contains formed feces in the descending segment.

Pancreas

The right pancreatic limb measures 1.12 cm in thickness. The pancreatic parenchyma is distinctly hyperechoic relative to the surrounding mesenteric fat. No peripancreatic inflammatory changes are identified.

Free Abdomen

No sonographic evidence of abdominal effusion, peritonitis, or lymphadenomegaly is identified. The iliac trifurcation appears normal.

PRIMARY FINDINGS

- Hepatomegaly.
- Marked gallbladder sediment with organized aggregates.
- Bilateral adrenal enlargement.
- Pancreatic parenchyma diffusely hyperechoic relative to the surrounding mesenteric fat.

SECONDARY FINDINGS

- Mild bilateral renal cortical hyperechogenicity.

INTERPRETATION OF THE FINDINGS & FURTHER RECOMMENDATIONS

Hepatomegaly with homogeneous parenchyma, marked ALP elevation, and concurrent adrenal enlargement is most consistent with steroid hepatopathy.

The adrenal glands are enlarged (right up to 1.17 cm), exceeding expected reference ranges (<0.7–0.8 cm), with relatively preserved shape. Mild asymmetry is present. This pattern supports adrenal hyperplasia, although an adrenal-dependent process cannot be fully excluded based on ultrasound alone.

Gallbladder findings are most consistent with organized (inspissated) biliary sludge forming rounded aggregates (tumefactive sludge). Given the patient's history of hyperadrenocorticism, these changes likely reflect altered bile composition and increased mucin content, predisposing to bile stasis and



PATIENT

Rocky Myer

SPECIES

Canine

BREED

Dachshund Mix

SEX

Neutered male

AGE

10 years

WEIGHT

37 lbs

INTERPRETED BY

Dr. Alicia Angosto
Guerrero

IMAGING PERFORMED BY

Mark Reser

HOSPITAL NAME

Harvest Hills VH

REFERRING VET

Dr. Reser

INVOICE

73817

DATE

3/25/26

aggregation. This appearance may represent an early or atypical stage of gallbladder mucocele formation.

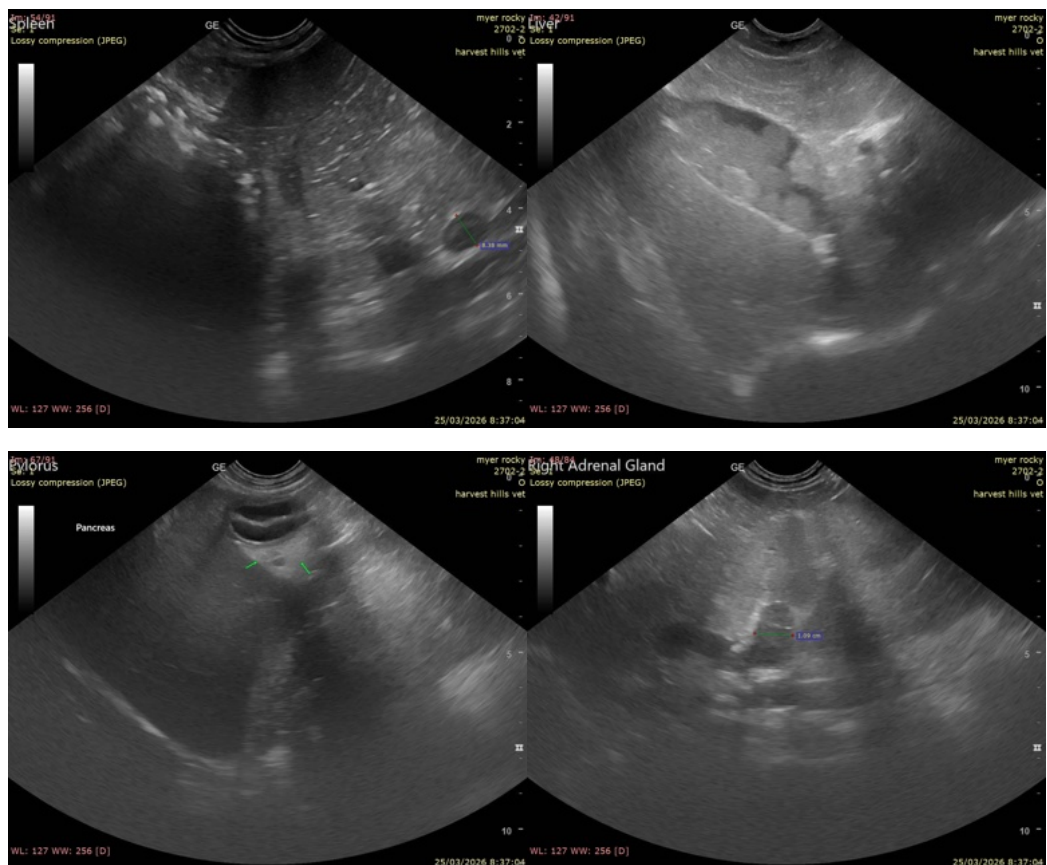
The pancreas is diffusely hyperechoic without inflammatory changes, most consistent with pancreatic lipomatosis / fatty infiltration or metabolic change (e.g., obesity-related or endocrine-associated).

Renal cortical echogenicity is mildly increased, which may reflect early chronic or metabolic renal change, particularly in the context of dilute urine and mild proteinuria.

Recommendations

- Re-evaluate hyperadrenocorticism: repeat endocrine testing (ACTH stimulation test ± additional testing as clinically indicated).
- Hepatobiliary monitoring: consider hepatoprotective therapy and ursodeoxycholic acid; follow-up ultrasound to assess gallbladder content progression.
- Clinical monitoring and management guided by endocrine results.

Final diagnostic and therapeutic decisions should be made by the attending veterinarian, who can best integrate these findings with the patient's clinical status.





PATIENT

Rocky Myer

SPECIES

Canine

BREED

Dachshund Mix

SEX

Neutered male

AGE

10 years

WEIGHT

37 lbs

INTERPRETED BY

Dr. Alicia Angosto
Guerrero

IMAGING PERFORMED BY

Mark Reser

HOSPITAL NAME

Harvest Hills VH

REFERRING VET

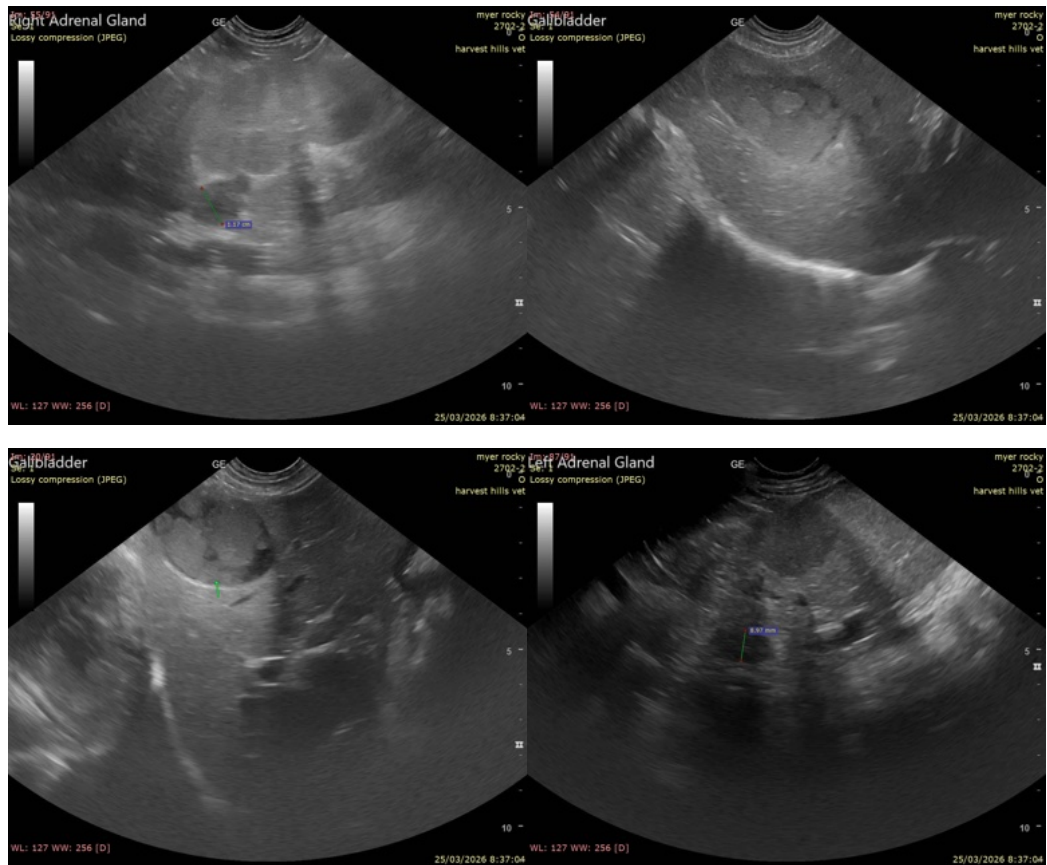
Dr. Reser

INVOICE

73817

DATE

3/25/26



The information and recommendations provided are based on the images presented by the referring veterinarian/sonographer. No evaluation can be communicated regarding pathology that was not visible in the image/video clips provided.

Thank you for this referral. If the clinical or image interpretation does not parallel your findings or if I can be of any further assistance please contact me.

Alicia Angosto Guerrero, DMV, PgDip, MSc.

MV Esp Ultrasound in Domestic and Wild Animals

info@SonoPath.com