



PATIENT

Ryder Martini

SPECIES

Feline

BREED

Domestic Shorthair

SEX

Neutered male

AGE

7 years

WEIGHT

9.5 lbs

INTERPRETED BY

Alicia Angosto
Guerrero, DMV,
PgDip, MSc.

IMAGING PERFORMED BY

Dr. Scott

HOSPITAL NAME

Wyckoff VH

REFERRING VET

Dr. Eisenberg

INVOICE

73782

DATE

3/24/26

PRESENTING CLINICAL SIGNS

Vomiting, ADR, decreased app

Eosinophils 1,176, Lymphocytes 168, total WBC 5.6K t4 1.0 chem wnl usg 1.057, UPC 0.9

ULTRASONOGRAPHIC EXAMINATION OF THE ABDOMEN

Urinary System

The bladder lumen is moderately distended, and the wall of the urinary bladder appears thin and smooth. The urine is anechoic. Normal appearance of the bladder neck and proximal urethra. There are no calculi and no evidence of inflammatory or neoplastic changes.

The left kidney is normal in shape and size: 4.35×2.34 cm, with a cortical thickness of 0.34 cm in the sagittal plane. The cortex is isoechoic compared to the liver parenchyma. The corticomedullary ratio is normal and corticomedullary definition is preserved. No evidence of pyelectasia, nephrolithiasis, or hydronephrosis.

The right kidney is normal in shape and size: 4.21×2.95 cm. The cortex is isoechoic compared to the liver parenchyma. The corticomedullary ratio is normal and corticomedullary definition is preserved. No evidence of pyelectasia, nephrolithiasis, or hydronephrosis.

Adrenal Glands

Both adrenal glands show normal shape and echogenicity. Dorsoventral diameters measured in the sagittal plane: The left adrenal gland measures 0.28 cm at the cranial pole and 0.30 cm at the caudal pole. The right adrenal gland measures 0.31 cm at the cranial pole and 0.30 cm at the caudal pole.

Spleen

Splenic thickness is 0.79 cm. The parenchyma demonstrates decreased echogenicity and fine homogeneous echotexture without focal parenchymal abnormalities. The splenic capsule is smooth and regular.

Liver

The liver is subjectively normal in size, with sharp edges and a regular contour. The liver parenchyma looks uniform and isoechoic compared to the falciform fat, with a normal echotexture. No hepatic lymphadenopathy is observed.

The gallbladder is moderately distended, with a thin wall and a moderate amount of biliary sludge. The common bile duct measures 3.4–2.06–1.18 mm from proximal to distal.



PATIENT

Ryder Martini

SPECIES

Feline

BREED

Domestic Shorthair

SEX

Neutered male

AGE

7 years

WEIGHT

9.5 lbs

INTERPRETED BY

Alicia Angosto
Guerrero, DMV,
PgDip, MSc.

IMAGING PERFORMED BY

Dr. Scott

HOSPITAL NAME

Wyckoff VH

REFERRING VET

Dr. Eisenberg

INVOICE

73782

DATE

3/24/26

Gastrointestinal

The stomach is empty and folded, with a fluid pattern, mural thickness (1.46 mm), and preserved wall layering.

Jejunum: 3.51 mm, mucosa: 1.20 mm. Submucosa: 0.58 mm. Muscularis propria: 0.76 mm. Ileum: 2.81 mm, mucosa: 0.76 mm. Submucosa: 1.40 mm. Muscularis propria: 0.65 mm. Normal wall layering. The ileocecal junction was not visualized. There are intestinal segments measuring up to 3.06 and 4.08 mm, with thickening of the muscularis layer up to 2.67 mm.

Colon: 0.86 cm, with formed feces in the descending segment.

Pancreas

The evaluated pancreatic areas do not show evidence of overt inflammation or neoplastic disease.

Free Abdomen

No abdominal effusion or peritonitis is observed. A large abdominal mass (approximately 6.45 × 5.14 × 3.74 cm) is identified in the region of the mesenteric root, near the mesenteric vessels. The mass has no clear organ association and is most consistent with a markedly enlarged mesenteric lymph node. The iliac trifurcation is normal.

PRIMARY FINDINGS

- Large mesenteric mass consistent with severe lymphadenopathy (~6.4 cm).
- Segmental small intestinal thickening with marked muscularis hypertrophy.

SECONDARY FINDINGS

- Mild diffuse splenic hypoechogenicity.
- Moderate biliary sludge.

INTERPRETATION OF THE FINDINGS & FURTHER RECOMMENDATIONS

There is a large mesenteric mass, most consistent with severe mesenteric lymphadenopathy, in combination with segmental small intestinal thickening characterized by marked muscularis hypertrophy. This pattern strongly supports an infiltrative gastrointestinal process, with intestinal lymphoma considered the primary differential.

Given eosinophilia, an eosinophilic inflammatory enteropathy remains a differential diagnosis; however, the eosinophilia may also represent a paraneoplastic response secondary to cytokine production (IL-5) by the lymphoma. The presence of a large, discrete mesenteric mass makes neoplasia significantly more likely.

The spleen appears diffusely mildly hypoechoic, which may represent reactive change; however, early



PATIENT

Ryder Martini

SPECIES

Feline

BREED

Domestic Shorthair

SEX

Neutered male

AGE

7 years

WEIGHT

9.5 lbs

INTERPRETED BY

Alicia Angosto
Guerrero, DMV,
PgDip, MSc.

IMAGING PERFORMED BY

Dr. Scott

HOSPITAL NAME

Wyckoff VH

REFERRING VET

Dr. Eisenberg

INVOICE

73782

DATE

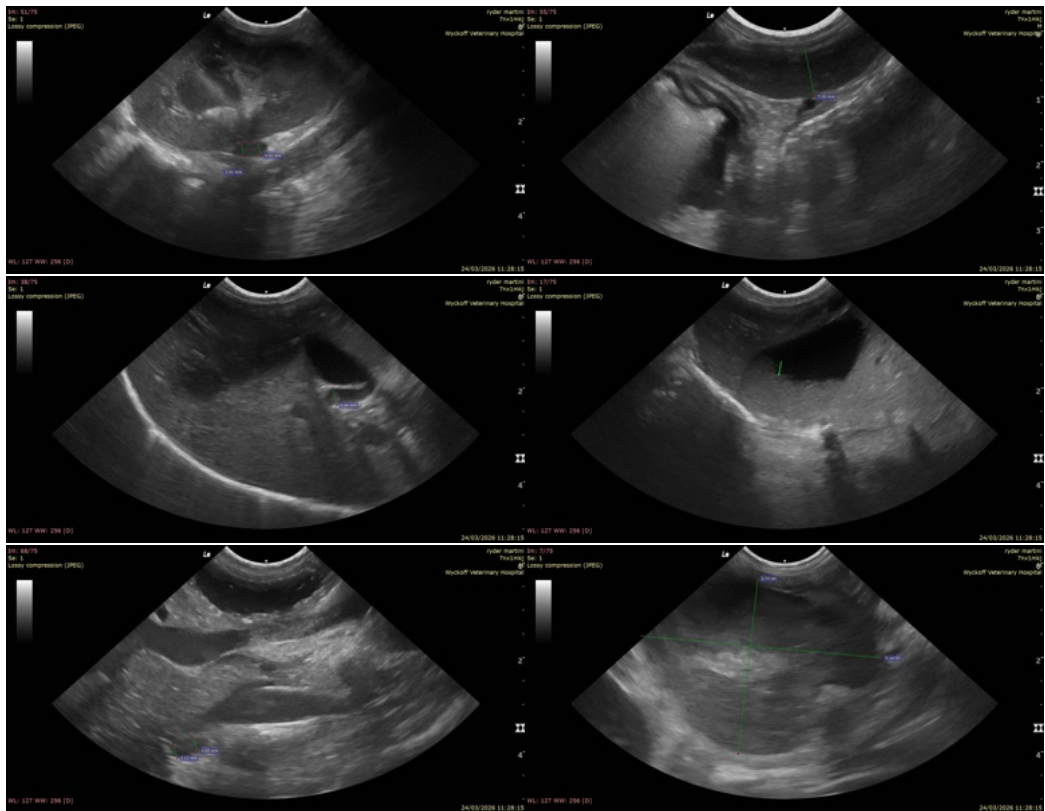
3/24/26

or diffuse infiltrative disease cannot be excluded in the current clinical context.

Recommendations

- Tissue sampling: Fine-needle aspirate of the mesenteric mass and spleen, with intestinal biopsies recommended if clinically indicated based on initial findings.
- Further staging if neoplasia confirmed: Thoracic imaging and additional lymph node evaluation.

Final diagnostic and therapeutic decisions should be made by the attending veterinarian, who can best integrate these findings with the patient's clinical status.





PATIENT

Ryder Martini

SPECIES

Feline

BREED

Domestic Shorthair

SEX

Neutered male

AGE

7 years

WEIGHT

9.5 lbs

INTERPRETED BY

Alicia Angosto
Guerrero, DMV,
PgDip, MSc.

IMAGING PERFORMED BY

Dr. Scott

HOSPITAL NAME

Wyckoff VH

REFERRING VET

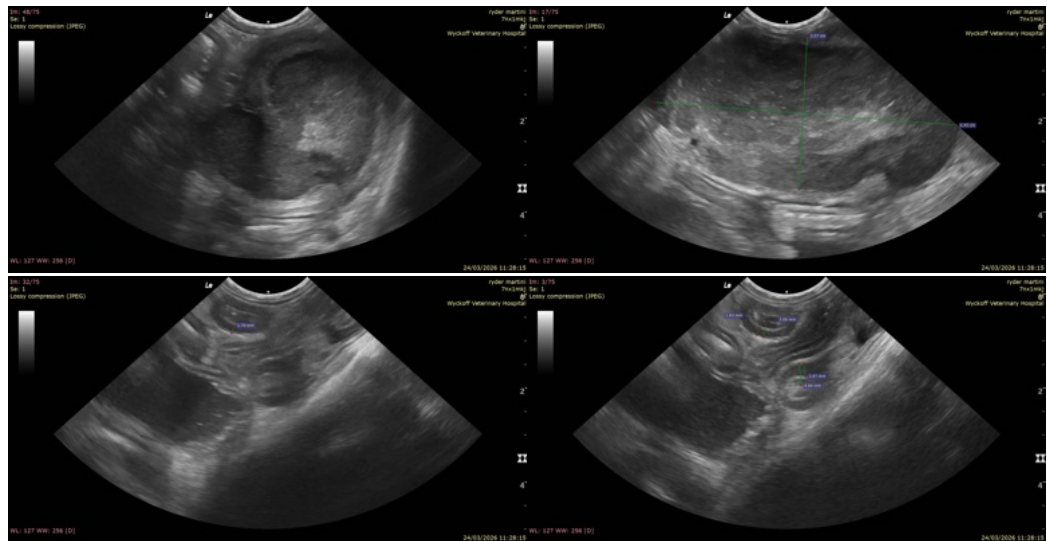
Dr. Eisenberg

INVOICE

73782

DATE

3/24/26



The information and recommendations provided are based on the images presented by the referring veterinarian/sonographer. No evaluation can be communicated regarding pathology that was not visible in the image/video clips provided.

Thank you for this referral. If the clinical or image interpretation does not parallel your findings or if I can be of any further assistance please contact me.

Alicia Angosto Guerrero, DMV, PgDip, MSc.

info@SonoPath.com