



## PATIENT

Ollie Heid

## SPECIES

Canine

## BREED

Jug

## SEX

Neutered male

## AGE

11 years

## WEIGHT

15 lbs

## INTERPRETED BY

Dr. Alicia Angosto  
Guerrero

## IMAGING PERFORMED BY

Amanda Hockenbrock

## HOSPITAL NAME

Lewisburg VH

## REFERRING VET

Dr. Vincent

## INVOICE

73444

## DATE

3/16/26

## PRESENTING CLINICAL SIGNS

- Patient came in for annual exam, no concerns
- Pre-anesthetic bloodwork ran for potential dental as patient has severe periodontal disease
- Patient is also arthritic.
- Takes zonisamide and phenobarbital PO and has been seizure free for 2 years on medications.
- Chem 10 - ALT 871 (10-125), ALKP >2000 (23-212), GLOB 5.2 (2.5-4.5) CBC- MONO 1.91 (0.16-1.12), PLT 79 (148-484). Concerned about hepatopathy.

## ULTRASONOGRAPHIC EXAMINATION OF THE ABDOMEN

### Urinary System

The bladder lumen is normally distended, and the wall of the urinary bladder appears thin and smooth. The urine is anechoic. The bladder neck and proximal urethra have a normal appearance. There are no calculi and no ultrasonographic evidence of inflammatory or neoplastic changes.

The left kidney is normal in shape and size, measuring 4.21×2.50 cm, with a cortical thickness of 0.50 cm in the sagittal plane. The cortex is isoechoic compared to the liver parenchyma. The corticomedullary ratio is normal and corticomedullary definition is preserved. There is no evidence of pyelectasia, nephrolithiasis, or hydronephrosis.

The right kidney is normal in shape and size, measuring 3.95×2.34 cm, with a cortical thickness of 0.44 cm in the sagittal plane. The cortex is isoechoic compared to the liver parenchyma. The corticomedullary ratio is normal and corticomedullary definition is preserved. There is no evidence of pyelectasia, nephrolithiasis, or hydronephrosis.

### Adrenal Glands

Both adrenal glands show normal shape and echogenicity. Dorsoventral diameters measured in the sagittal plane (maximum of three measurements): the left adrenal gland measures 0.56 cm at the cranial pole and 0.58 cm at the caudal pole. The right adrenal gland measures 0.56 cm at the cranial pole and 0.49 cm at the caudal pole.

### Spleen

Splenic thickness is 1.16 cm. The parenchyma demonstrates normal echogenicity and a fine homogeneous echotexture without focal abnormalities. The splenic capsule is smooth and regular.

### Liver

The liver is subjectively normal in size, with sharp edges and a regular contour. The parenchyma appears homogeneous and isoechoic compared to the falciform fat, with a normal echotexture. No hepatic lymphadenopathy is observed.



## PATIENT

Ollie Heid

The gallbladder lumen is moderately distended. The wall shows mucosal gland hyperplasia with very mild striated pattern formation and abundant immobile echogenic biliary sludge, consistent with an early gallbladder mucocele. No dilation of the cystic duct or common bile duct is observed.

## SPECIES

Canine

### *Gastrointestinal*

## BREED

The stomach is empty and folded, with a wall thickness of 2.53 mm and preserved layering. The pylorus measures 4.66 mm.

Jug

The duodenum measures 3.21 mm. The jejunum measures 3.33 mm. No ultrasonographic signs of inflammation, ileus, or foreign material are identified.

## SEX

Neutered male

The colon measures 0.89 mm and contains formed feces in the descending segment.

## AGE

11 years

### *Pancreas*

The evaluated pancreatic regions do not show ultrasonographic evidence of overt inflammation or neoplastic disease.

## WEIGHT

15 lbs

### *Peritoneal Cavity*

## INTERPRETED BY

Dr. Alicia Angosto  
Guerrero

No ultrasonographic evidence of abdominal effusion, peritonitis, or lymphadenomegaly is identified. The iliac trifurcation is unremarkable.

## IMAGING PERFORMED BY

Amanda Hockenbrock

## ULTRASONOGRAPHIC FINDINGS

- Early gallbladder mucocele (grade II) with mucosal hyperplasia and immobile sludge.

## HOSPITAL NAME

Lewisburg VH

## INTERPRETATION OF THE FINDINGS & FURTHER RECOMMENDATIONS

The most clinically relevant finding is the presence of early gallbladder mucocele formation (grade II), characterized by mucosal gland hyperplasia, mild striated pattern, and abundant immobile biliary sludge. In dogs, gallbladder mucocele formation is a well-recognized cause of cholestatic hepatopathy with secondary hepatocellular injury, even in the absence of biliary obstruction. The lack of common bile duct dilation supports a non-obstructive or early-stage process.

## REFERRING VET

Dr. Vincent

## INVOICE

73444

The hepatic parenchyma is unremarkable on ultrasound. This does not exclude significant hepatopathy, as functional and metabolic hepatic disease (including drug-induced hepatopathy from phenobarbital) may occur without overt structural changes. Given the patient's medication history, a concurrent drug-induced hepatopathy (vacuolar-type) remains a strong contributing or predisposing factor.

## DATE

3/16/26

Overall, findings are most consistent with early gallbladder mucocele formation with associated cholestatic hepatopathy, likely contributing to the marked enzyme elevations, potentially in combination with phenobarbital-associated hepatic enzyme induction or hepatopathy.



**PATIENT**

Ollie Heid

**SPECIES**

Canine

**BREED**

Jug

**SEX**

Neutered male

**AGE**

11 years

**WEIGHT**

15 lbs

**INTERPRETED BY**

Dr. Alicia Angosto  
Guerrero

**IMAGING  
PERFORMED BY**

Amanda Hockenbrock

**HOSPITAL NAME**

Lewisburg VH

**REFERRING VET**

Dr. Vincent

**INVOICE**

73444

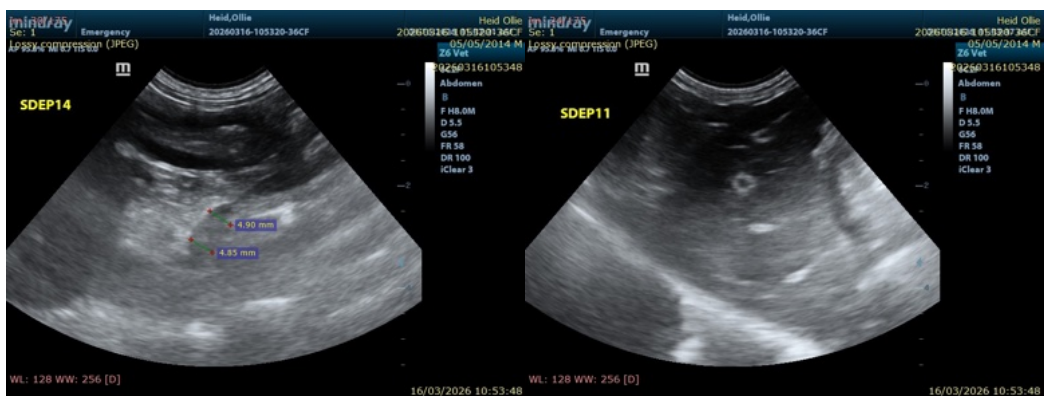
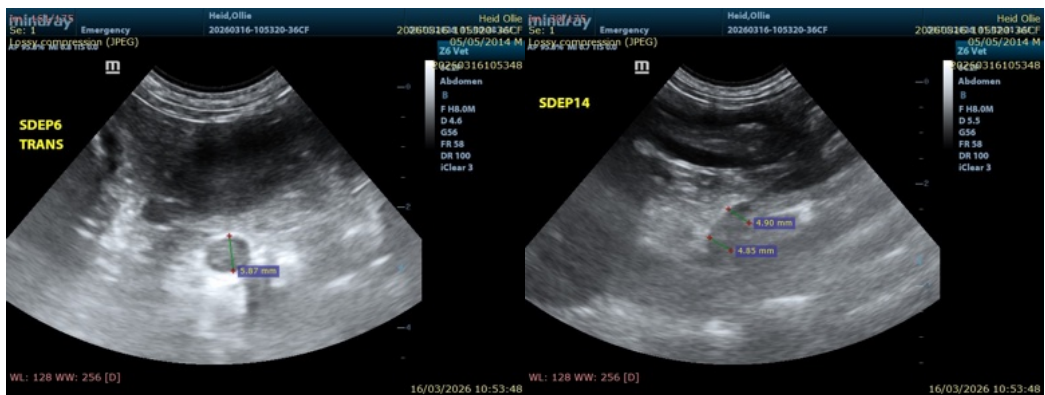
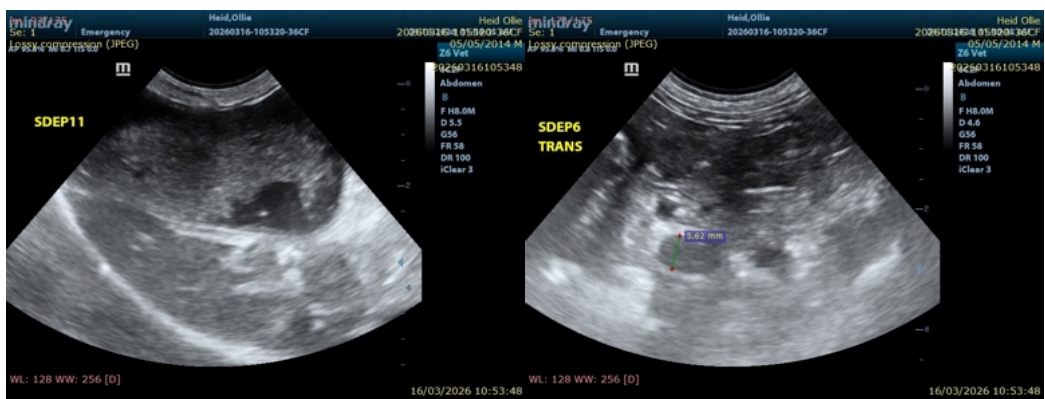
**DATE**

3/16/26

**Recommendations**

- Consider medical management of early gallbladder mucocele.
- Monitor for mucocele progression.
- Recheck liver enzymes.

Recommendations are provided as guidance and should be carried out at the discretion of the attending veterinarian.





## PATIENT

Ollie Heid

## SPECIES

Canine

## BREED

Jug

## SEX

Neutered male

## AGE

11 years

## WEIGHT

15 lbs

## INTERPRETED BY

Dr. Alicia Angosto Guerrero

## IMAGING PERFORMED BY

Amanda Hockenbrock

## HOSPITAL NAME

Lewisburg VH

## REFERRING VET

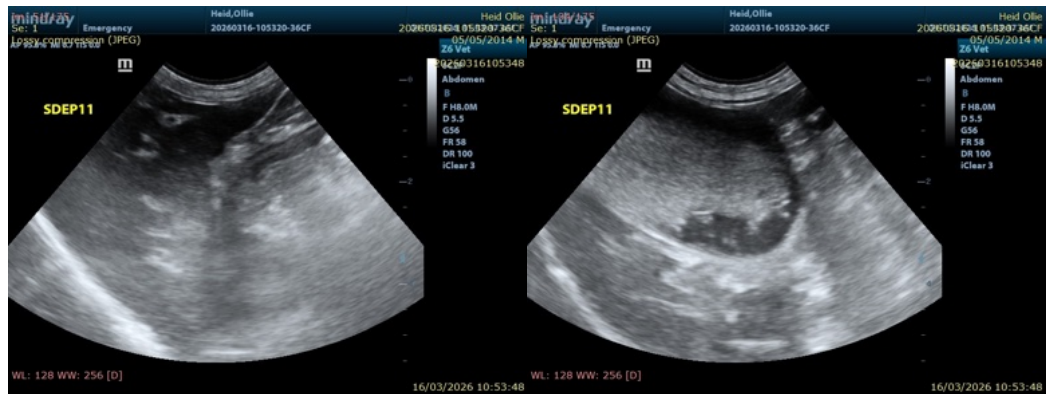
Dr. Vincent

## INVOICE

73444

## DATE

3/16/26



The information and recommendations provided are based on the images presented by the referring veterinarian/sonographer. No evaluation can be communicated regarding pathology that was not visible in the image/video clips provided.

Thank you for this referral. If the clinical or image interpretation does not parallel your findings or if I can be of any further assistance please contact me.

Alicia Angosto Guerrero, DMV, PgDip, MSc.

MV Esp Ultrasound in Domestic and Wild Animals

[info@SonoPath.com](mailto:info@SonoPath.com)