



PATIENT

Usagi Salamancha

SPECIES

Feline

BREED

Domestic Longhair

SEX

Spayed female

AGE

9 years

WEIGHT

6.3 lbs

INTERPRETED BY

Dr. Alicia Angosto
Guerrero

IMAGING PERFORMED BY

Shanna Sallee

HOSPITAL NAME

Hermiston VC

REFERRING VET

Dr. Sallee

INVOICE

73410

DATE

3/11/26

PRESENTING CLINICAL SIGNS

- Weight loss over 5 months, normal appetite
- Started on i/d diet last week, p now has diarrhea
- K 8.1 (3.5-5.8 mmol/l) globulins 5.6 (2.8-5.1 g/dl) fPLI 40.1 (0-4.4 U/L)

ULTRASONOGRAPHIC EXAMINATION OF THE ABDOMEN

Urinary System

The bladder lumen is normally distended and the wall appears thin and smooth. The urine is predominantly anechoic with scant suspended echoes. The bladder neck and proximal urethra have a normal appearance. No calculi are identified and there is no evidence of inflammatory or neoplastic changes.

The left kidney measures 2.98×1.87 cm. Cortical thickness measures 0.22 cm in the sagittal plane. The cortex is mildly hyperechoic compared with the hepatic parenchyma. The corticomedullary ratio is normal and corticomedullary definition is preserved. There is no evidence of pyelectasia, nephrolithiasis, or hydronephrosis. Color Doppler demonstrates a normal vascular pattern.

The right kidney measures 2.66×1.64 cm. The cortex is mildly hyperechoic compared with the hepatic parenchyma. The corticomedullary ratio is normal and corticomedullary definition is preserved. There is no evidence of pyelectasia, nephrolithiasis, or hydronephrosis. Color Doppler demonstrates a normal vascular pattern.

Adrenal Glands

Both adrenal glands demonstrate normal shape and echogenicity. Dorsoventral diameters measured in the sagittal plane:

Left adrenal gland: 0.36 cm at the cranial pole and 0.34 cm at the caudal pole. Right adrenal gland: 0.29 cm at the cranial pole and 0.25 cm at the caudal pole.

Spleen

Splenic thickness measures 0.57 cm. The parenchyma demonstrates normal echogenicity and a fine homogeneous echotexture without focal abnormalities. The splenic capsule is smooth and regular.

Liver

The liver is subjectively normal in size with sharp edges and a regular contour. The hepatic parenchyma appears uniform and isoechoic relative to the falciform fat, with normal echotexture. No hepatic lymphadenopathy is observed.

The gallbladder lumen is normally distended. The wall is thin and the contents are anechoic. The common bile duct measures 2.86–1.50–1.45 mm along the evaluated segments.



PATIENT

Usagi Salamancha

SPECIES

Feline

BREED

Domestic Longhair

SEX

Spayed female

AGE

9 years

WEIGHT

6.3 lbs

INTERPRETED BY

Dr. Alicia Angosto
Guerrero

IMAGING PERFORMED BY

Shanna Sallee

HOSPITAL NAME

Hermiston VC

REFERRING VET

Dr. Sallee

INVOICE

73410

DATE

3/11/26

Gastrointestinal

The stomach is partially empty with a small amount of ingesta within the lumen. Gastric mural thickness measures 1.69 mm with preserved wall layering. The pylorus measures 3 mm. The duodenum measures 2.49 mm in thickness. The major duodenal papilla measures 3.12×3.76 mm.

The jejunum measures 2.83 mm in total thickness, with the mucosa measuring 1.93 mm, the submucosa 0.60 mm, and the muscularis propria 0.38 mm. Wall layering is preserved.

The ileum measures 2.63 mm in total thickness, with mucosa measuring 0.78 mm, submucosa 0.57 mm, and muscularis propria 1.05 mm. Wall layering remains recognizable; however, the muscularis layer is subjectively thickened relative to the mucosa.

At the level of the ileocecal junction, the intestinal wall measures 2.21 mm, with the mucosa measuring 0.48 mm and the muscularis 1.40 mm.

The colon measures 0.65 mm in the ascending segment and 0.90 mm in the transverse segment, with formed fecal material present within the descending colon.

Pancreas

The left pancreatic limb measures 5.96 mm. The pancreatic parenchyma is mildly hypoechoic relative to the adjacent omental fat and appears slightly irregular in contour. No focal mass lesion is identified and no sonographic evidence of active peripancreatic fat inflammation is observed.

Peritoneal Cavity

A very small amount of anechoic abdominal effusion is observed between intestinal loops.

Cranial mesenteric lymph nodes measure 7.23–9.56 mm and appear rounded and mildly hypoechoic. Ileocecal lymph nodes measure 2.17 mm and maintain normal shape and echogenicity.

The iliac trifurcation region appears normal.

ULTRASONOGRAPHIC FINDINGS

PRIMARY FINDINGS

- Ileal and ileocecal muscularis thickening with increased muscularis-to-mucosa ratio.
- Mild enlargement and rounding of cranial mesenteric lymph nodes (7.23–9.56 mm).

SECONDARY FINDINGS

- Very small volume abdominal effusion.



PATIENT

Usagi Salamanca

SPECIES

Feline

BREED

Domestic Longhair

SEX

Spayed female

AGE

9 years

WEIGHT

6.3 lbs

INTERPRETED BY

Dr. Alicia Angosto
Guerrero

IMAGING PERFORMED BY

Shanna Sallee

HOSPITAL NAME

Hermiston VC

REFERRING VET

Dr. Sallee

INVOICE

73410

DATE

3/11/26

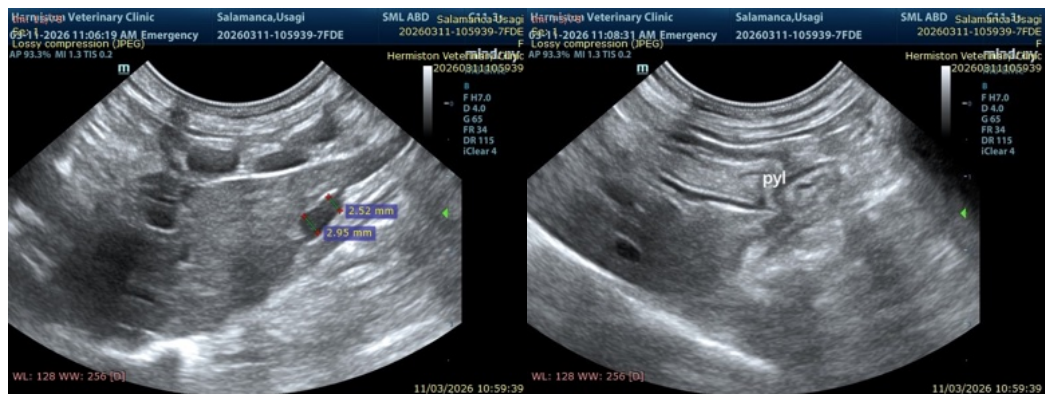
INTERPRETATION OF THE FINDINGS & FURTHER RECOMMENDATIONS

Ultrasonographic findings are most consistent with chronic enteropathy with ileal predominance. The ileum and ileocecal region demonstrate disproportionate muscularis thickening, with increased muscularis-to-mucosa ratios (ileum 1.35; ileocecal junction 2.9). In normal feline intestine this ratio is typically <0.5, therefore these values indicate marked muscularis expansion compatible with infiltrative enteropathy. This pattern raises concern for low-grade intestinal lymphoma, although severe inflammatory bowel disease remains a differential diagnosis, as these entities frequently overlap on ultrasonography and cannot be definitively differentiated based on imaging alone. Enlargement of the cranial mesenteric lymph nodes further supports an underlying chronic intestinal inflammatory or infiltrative process.

In the context of a markedly elevated fPLI, pancreatic findings are compatible with pancreatitis, which may be chronic or recurrent in nature. In cats, pancreatitis commonly lacks the marked peripancreatic inflammatory changes typically observed in dogs, and ultrasonographic findings may be subtle. No pancreatic mass is clearly identified.

Recommendations

- Findings support chronic enteropathy (IBD vs low-grade lymphoma), and definitive differentiation requires intestinal biopsy.
- Consider evaluation of serum cobalamin concentration or a complete feline gastrointestinal panel.
- If clinical suspicion for pancreatitis remains high given the markedly elevated fPLI, supportive management for pancreatitis may be considered even in the absence of strong ultrasonographic changes.
- Clinical correlation and response to dietary and medical management for chronic enteropathy may help guide further diagnostics.
- Diagnostic and therapeutic decisions should ultimately be guided by the attending veterinarian.





PATIENT

Usagi Salamanca

SPECIES

Feline

BREED

Domestic Longhair

SEX

Spayed female

AGE

9 years

WEIGHT

6.3 lbs

INTERPRETED BY

Dr. Alicia Angosto
Guerrero

IMAGING PERFORMED BY

Shanna Sallee

HOSPITAL NAME

Hermiston VC

REFERRING VET

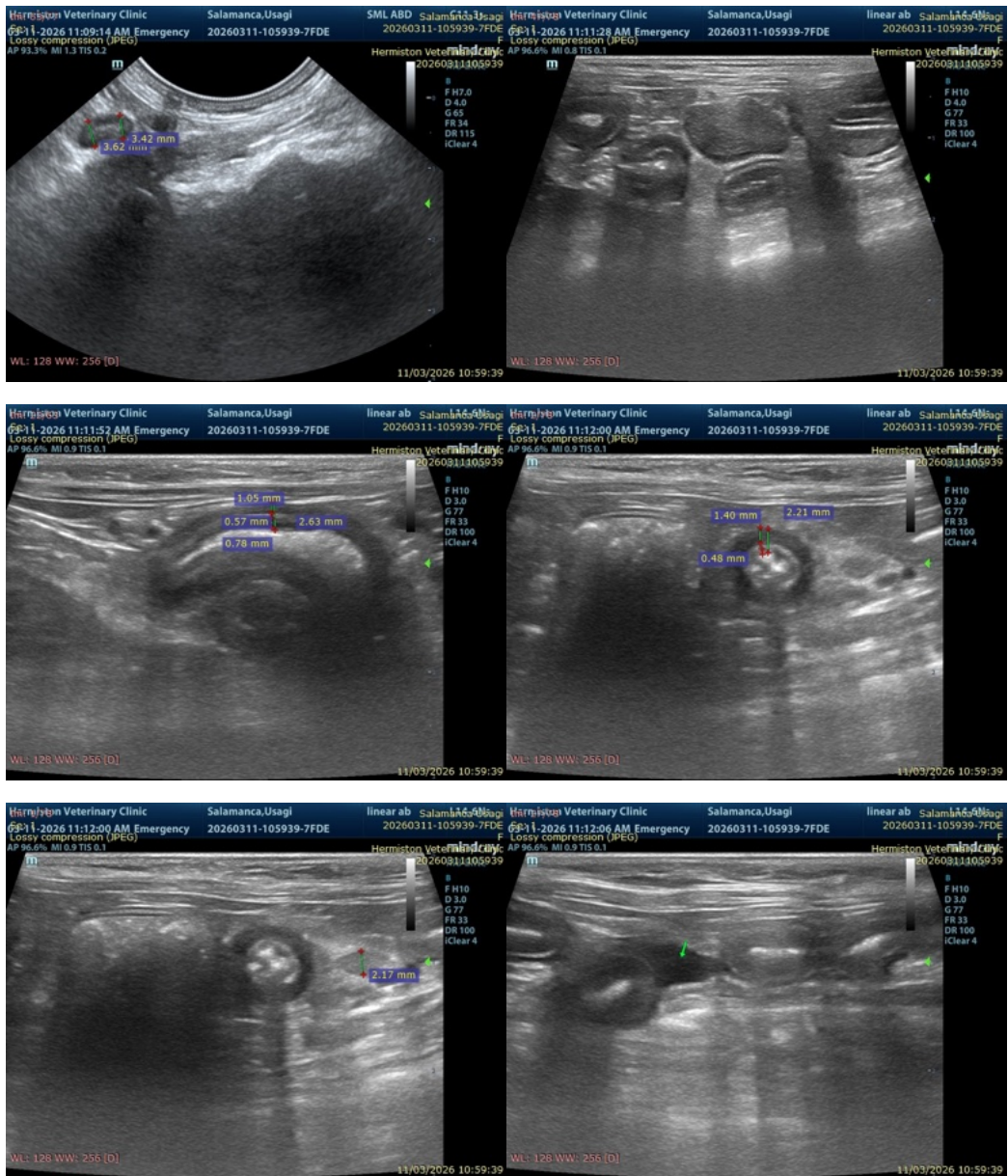
Dr. Sallee

INVOICE

73410

DATE

3/11/26





PATIENT

Usagi Salamanca

SPECIES

Feline

BREED

Domestic Longhair

SEX

Spayed female

AGE

9 years

WEIGHT

6.3 lbs

INTERPRETED BY

Dr. Alicia Angosto Guerrero

IMAGING PERFORMED BY

Shanna Sallee

HOSPITAL NAME

Hermiston VC

REFERRING VET

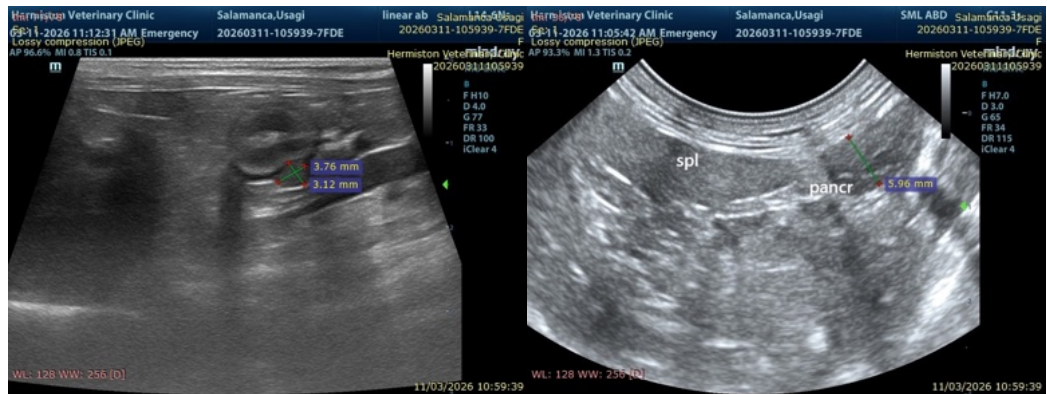
Dr. Sallee

INVOICE

73410

DATE

3/11/26



The information and recommendations provided are based on the images presented by the referring veterinarian/sonographer. No evaluation can be communicated regarding pathology that was not visible in the image/video clips provided.

Thank you for this referral. If the clinical or image interpretation does not parallel your findings or if I can be of any further assistance please contact me.

Alicia Angosto Guerrero, DMV, PgDip, MSc.

MV Esp Ultrasound in Domestic and Wild Animals

info@SonoPath.com