



PATIENT

Lani Luc

SPECIES

Canine

BREED

Lab Mix

SEX

Spayed female

AGE

11 years

WEIGHT

27 kg

INTERPRETED BY

Dr. Alicia Angosto
Guerrero

IMAGING PERFORMED BY

Dr. Louise Corbeil

HOSPITAL NAME

Cochrane AC

REFERRING VET

Dr. Corbeil

INVOICE

73407

DATE

3/11/26

PRESENTING CLINICAL SIGNS

- Seen 2 days ago March 9th for inappetence and vomiting approx 5d duration. Approx 10+cm intra abdominal R cranial mass found on POCUS. Started cerenia mirtazapine.
- Eating now but still picky. Fasted overnight.
- No further vomiting. Now has diarrhea.
- Bloodwork (CBC chem T4): Mild eosinophilia - Eosinophils $1.89 \times 10^9/L$ rr 0.06- 1.23 otherwise no significant findings. Radiographs: No visible thoracic masses. Soft tissue abdominal mass difficult to see. L2-L3 vertebral spondylosis

ULTRASONOGRAPHIC EXAMINATION OF THE ABDOMEN

Urinary System

The bladder lumen is almost empty, and therefore the bladder wall cannot be reliably evaluated.

The left kidney is normal in shape and size: 6.77×3.14 cm, and the thickness of the cortex is 0.66 cm in the sagittal plane. The cortex is isoechoic compared to the liver parenchyma. The corticomedullary ratio is normal and corticomedullary definition is preserved. There is no evidence of pyelectasia, nephroliths, or hydronephrosis. Color Doppler shows a normal vascular pattern.

The right kidney is normal in shape and size: 6.60×3.24 cm, and the thickness of the cortex is 0.69 cm in the sagittal plane. The cortex is isoechoic compared to the liver parenchyma. The corticomedullary ratio is normal and corticomedullary definition is preserved. There is no evidence of pyelectasia, nephroliths, or hydronephrosis. Color Doppler shows a normal vascular pattern.

Adrenal Glands

Not confidently identified.

Spleen

Splenic thickness is 1.93 cm. The parenchyma demonstrates normal echogenicity and fine homogeneous echotexture without focal parenchymal abnormalities. The splenic capsule is smooth and regular.

Liver

The liver is subjectively normal in size, with sharp edges and a regular contour. The liver parenchyma appears uniform and isoechoic compared to the falciform fat, with a normal echotexture. No hepatic lymphadenopathy is observed.

The gallbladder lumen is normally distended. The wall is thin and the contents are primarily anechoic with a small amount of biliary sludge. No dilation of the cystic duct or common bile duct is observed.



PATIENT

Lani Luc

SPECIES

Canine

BREED

Lab Mix

SEX

Spayed female

AGE

11 years

WEIGHT

27 kg

INTERPRETED BY

Dr. Alicia Angosto
Guerrero

IMAGING PERFORMED BY

Dr. Louise Corbeil

HOSPITAL NAME

Cochrane AC

REFERRING VET

Dr. Corbeil

INVOICE

73407

DATE

3/11/26

Gastrointestinal

The stomach is empty and folded, with gas in the lumen, mural thickness (2.19 mm) and preserved wall layering.

The duodenum measures 2.93 mm. The jejunum measures 3.41 mm, with preserved wall layering.

A segment labeled as the ileocecal junction/colon demonstrates marked focal wall thickening measuring approximately 6.36–7 mm with complete loss of normal mural layering.

The colon measures 0.82 mm, with formed feces present in the descending segment.

Pancreas

The evaluated pancreatic areas do not show evidence of overt inflammation or neoplastic disease.

Peritoneal Cavity

Abdominal effusion is present, most evident within the splenorenal recess and hepatorenal fossa.

There are signs of regional mesenteric inflammation surrounding the abnormal intestinal segment and adjacent lymph nodes. No pneumoperitoneum is identified.

A hypoechoic, moderately heterogeneous mass measuring approximately 9.05×3.84 cm is identified. An adjacent mass measuring approximately 7.30×2.93 cm with irregular margins is also present in the mid-abdomen within the mesenteric region between the mesenteric vessels, compatible with severely abnormal cranial mesenteric lymph nodes.

Additionally, sublumbar lymph nodes are markedly enlarged, rounded, and markedly hypoechoic, with surrounding hyperechoic perinodal fat, indicating significant regional lymphadenopathy.

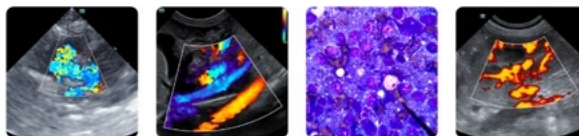
ULTRASONOGRAPHIC FINDINGS

PRIMARY FINDINGS

- Marked focal thickening of an intestinal segment (6.36–7 mm) with complete loss of mural layering.
- Severely enlarged cranial mesenteric lymph nodes forming mass-like structures.
- Marked sublumbar lymphadenopathy.

SECONDARY FINDINGS

- Small amount of abdominal effusion.
- Regional mesenteric inflammatory changes.



PATIENT

Lani Luc

SPECIES

Canine

BREED

Lab Mix

SEX

Spayed female

AGE

11 years

WEIGHT

27 kg

INTERPRETED BY

Dr. Alicia Angosto
Guerrero

INTERPRETATION OF THE FINDINGS & FURTHER RECOMMENDATIONS

The most significant abnormality identified is a markedly thickened segment of intestine with complete loss of normal mural layering, a pattern that is highly suspicious for infiltrative intestinal disease or intestinal neoplasia.

Additionally, there is severe mesenteric and sublumbal lymphadenopathy, with lymph nodes appearing markedly enlarged, rounded, and hypoechoic, and associated perinodal fat inflammation. Two large masses within the mesenteric region most likely represent severely enlarged mesenteric lymph nodes, which may reflect lymphomatous involvement or metastatic nodal disease.

A small amount of abdominal effusion is present, along with regional mesenteric inflammatory changes surrounding the affected intestinal segment. The characteristics of the free abdominal fluid are most compatible with an inflammatory exudate. No sonographic evidence of intestinal perforation is identified, although this possibility cannot be completely excluded.

Taken together, these findings are most consistent with intestinal neoplasia with extensive regional lymph node involvement. The primary differential diagnoses include intestinal lymphoma, and intestinal adenocarcinoma with nodal metastasis, although other infiltrative neoplastic processes cannot be excluded.

Recommendations

- Ultrasound-guided fine needle aspiration (pending) or biopsy of the enlarged mesenteric lymph nodes or the intestinal lesion may help establish a diagnosis.
- If cytology is inconclusive, surgical exploration and intestinal biopsy may be required for definitive diagnosis.

IMAGING PERFORMED BY

Dr. Louise Corbeil

HOSPITAL NAME

Cochrane AC

REFERRING VET

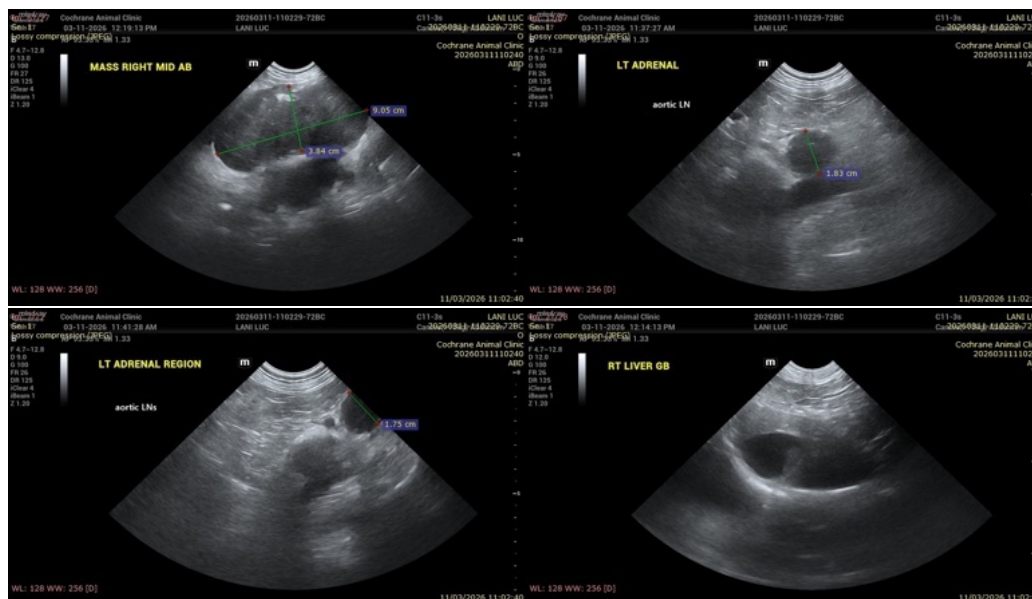
Dr. Corbeil

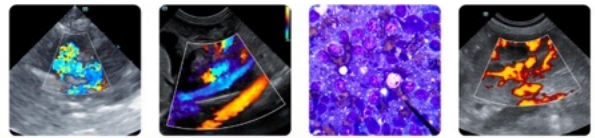
INVOICE

73407

DATE

3/11/26





PATIENT

Lani Luc

SPECIES

Canine

BREED

Lab Mix

SEX

Spayed female

AGE

11 years

WEIGHT

27 kg

INTERPRETED BY

Dr. Alicia Angosto
Guerrero

IMAGING PERFORMED BY

Dr. Louise Corbeil

HOSPITAL NAME

Cochrane AC

REFERRING VET

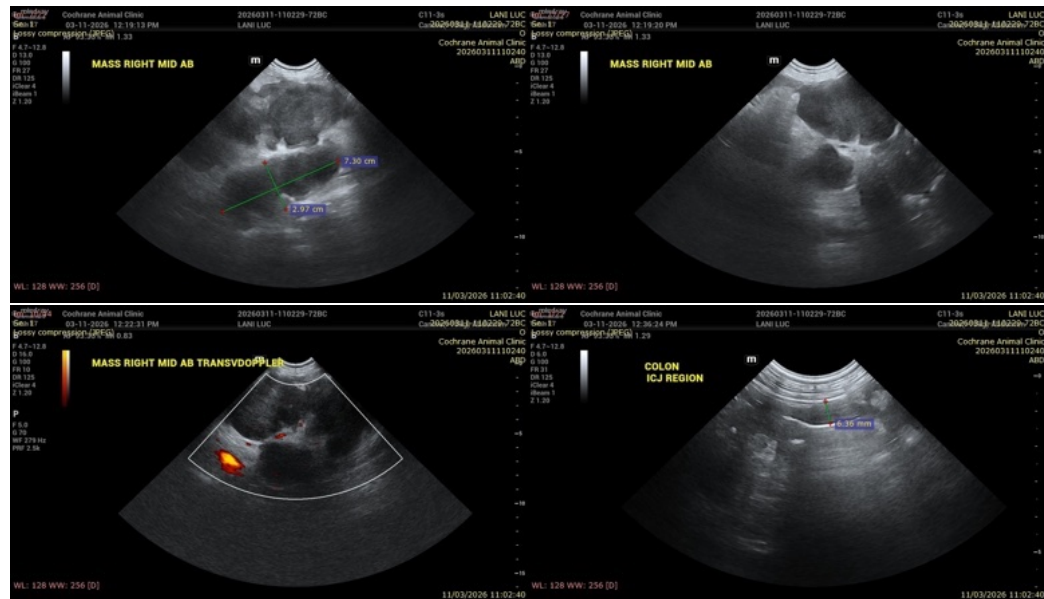
Dr. Corbeil

INVOICE

73407

DATE

3/11/26



The information and recommendations provided are based on the images presented by the referring veterinarian/sonographer. No evaluation can be communicated regarding pathology that was not visible in the image/video clips provided.

Thank you for this referral. If the clinical or image interpretation does not parallel your findings or if I can be of any further assistance please contact me.

Alicia Angosto Guerrero, DMV, PgDip, MSc.

MV Esp Ultrasound in Domestic and Wild Animals

info@SonoPath.com