



## PATIENT

Memphis Canniff

## SPECIES

Canine

## BREED

Doberman Pinscher

## SEX

Neutered Male

## AGE

5

## WEIGHT

65.2 pounds

## INTERPRETED BY

Alicia Angosto  
Guerrero, DMV,  
PgDip, MSc.

## IMAGING PERFORMED BY

Dr. Carlos Abdul-Chani

## HOSPITAL NAME

Byram Animal Hospital

## REFERRING VET

Dr. Maria Cruz

## INVOICE

14193

## DATE

03/10/26

## PRESENTING CLINICAL SIGNS

- Chronic colitis
- R/O Abdominal disease
- current meds: Galliprant/Trazadone

## ULTRASONOGRAPHIC EXAMINATION OF THE ABDOMEN

### *Urinary System*

The urinary bladder is almost completely empty and therefore not adequately evaluable. The small amount of urine present appears normally anechoic.

The left kidney is normal in shape and size: 7.44×3.53 cm, and the thickness of the cortex is 0.63 cm in the sagittal plane. The cortex is isoechoic compared to the liver parenchyma. The corticomedullary ratio is normal and corticomedullary definition is preserved. There is no evidence of pyelectasia, nephroliths, or hydronephrosis. Color Doppler shows a normal vascular pattern.

The right kidney is normal in shape and size: 7.62×3.40 cm, and the thickness of the cortex is 0.65 cm in the sagittal plane. The cortex is isoechoic compared to the liver parenchyma. The corticomedullary ratio is normal and corticomedullary definition is preserved. There is no evidence of pyelectasia, nephroliths, or hydronephrosis. Color Doppler shows a normal vascular pattern.

### *Adrenal Glands*

Both adrenal glands show normal shape and echogenicity. Dorsoventral diameters measured in the sagittal plane: the left adrenal gland measures 0.50 cm at the cranial pole and 0.51 cm at the caudal pole. The right adrenal gland measures 0.57 cm at the cranial pole and 0.49 cm at the caudal pole.

### *Spleen*

Splenic thickness is 1.82 cm. The parenchyma demonstrates normal echogenicity and a fine homogeneous echotexture without focal parenchymal abnormalities. The splenic capsule is smooth and regular. Splenic vasculature appears normal.

### *Liver*

The liver is subjectively normal in size, with sharp edges and a regular contour. The liver parenchyma appears uniform and isoechoic compared to the falciform fat, with a normal echotexture. No hepatic lymphadenopathy is observed.

The gallbladder lumen is normally distended. The wall is thin and the contents are primarily anechoic with a small amount of biliary sludge. No dilation of the cystic duct or common bile duct is observed.

### *Gastrointestinal*

The stomach is empty and folded with gas content, mural thickness (3.66 mm), and preserved wall layering. An intraluminal structure producing marked acoustic shadowing is observed, which could represent residual ingesta or other ingested material. Correlation with fasting status and clinical history is recommended. This finding does not appear to be causing obstruction.

The pylorus measures 5.26 mm.



## PATIENT

Memphis Canniff

Duodenum: 5.27 mm.  
Jejunum: 2.90–2.98 mm.  
Ileum: 2.52 mm.

## SPECIES

Canine

Normal wall layering is preserved throughout. The ileocecal junction was not visualized. No ultrasonographic signs of inflammation, ileus, or foreign material are identified.

## BREED

Doberman Pinscher

Colon: ascending colon 1.52 mm, transverse colon 1.79–1.80 mm, descending colon 2.11–2.21 mm, with a small amount of fecal material within the lumen producing mild distal acoustic shadowing.

### **Pancreas**

The evaluated pancreatic regions do not show evidence of overt inflammation or neoplastic disease.

## SEX

Neutered Male

### **Free Abdomen**

No sonographic evidence of abdominal effusion, peritonitis, or lymphadenomegaly is identified. The lymph node at the iliac trifurcation appears normal.

## AGE

5

### **PRIMARY FINDINGS**

## WEIGHT

65.2 pounds

- The small and large intestines demonstrate normal wall thickness and preserved layering.
- Intraluminal gastric material producing marked acoustic shadowing, most compatible with residual ingesta or ingested material.

## INTERPRETED BY

Alicia Angosto  
Guerrero, DMV,  
PgDip, MSc.

### **INTERPRETATION OF THE FINDINGS & FURTHER RECOMMENDATIONS**

Overall, no structural abdominal abnormalities are identified that would explain the patient's history of chronic colitis. It should be noted that several common causes of chronic large bowel disease may not produce detectable ultrasonographic abnormalities, particularly when inflammation is confined to the mucosa. These include dietary-responsive colitis, dysbiosis-associated colitis (antibiotic-responsive colitis), parasitic colitis (*Trichuris vulpis* or *Giardia*), stress-associated colitis, and early or mucosa-limited inflammatory colitis.

## IMAGING PERFORMED BY

Dr. Carlos Abdul-Chani

### **Recommendations**

## HOSPITAL NAME

Byram Animal Hospital

- If clinical signs of chronic colitis persist, further diagnostic evaluation may include fecal testing (including centrifugation flotation and *Giardia* testing) if not recently performed. Empirical deworming, dietary trials, and gastrointestinal panel testing (including cobalamin assessment) may also be considered at the discretion of the attending veterinarian.
- If these evaluations are negative and clinical signs persist despite appropriate therapeutic trials, colonoscopy with mucosal biopsy may be considered, as inflammatory or microscopic colonic disease may occur in the absence of ultrasonographic abnormalities.

## REFERRING VET

Dr. Maria Cruz

## INVOICE

14193

## DATE

03/10/26



**PATIENT**

Memphis Canniff

**SPECIES**

Canine

**BREED**

Doberman Pinscher

**SEX**

Neutered Male

**AGE**

5

**WEIGHT**

65.2 pounds

**INTERPRETED BY**

Alicia Angosto  
Guerrero, DMV,  
PgDip, MSc.

**IMAGING  
PERFORMED BY**

Dr. Carlos Abdul-Chani

**HOSPITAL NAME**

Byram Animal Hospital

**REFERRING VET**

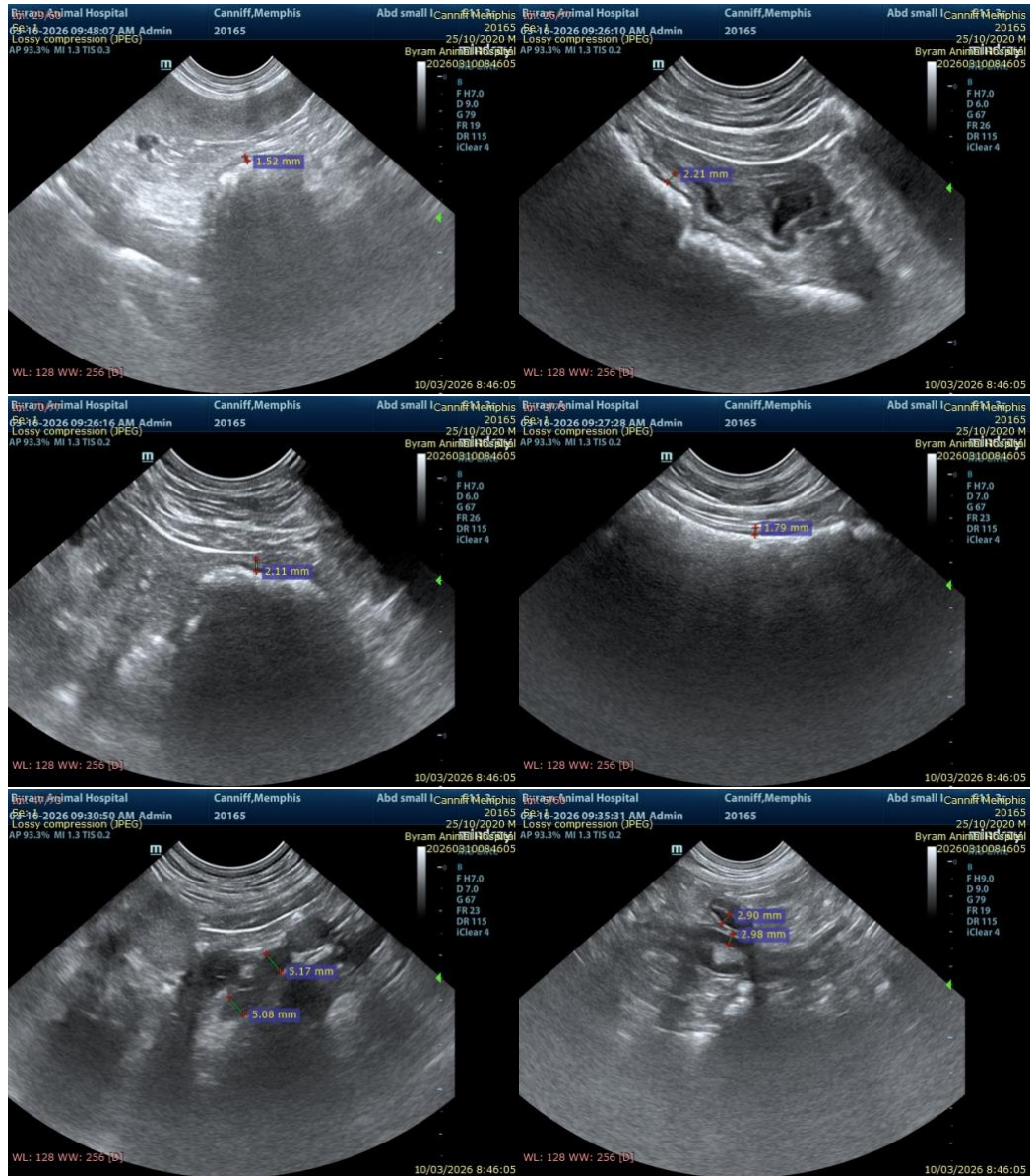
Dr. Maria Cruz

**INVOICE**

14193

**DATE**

03/10/26





**PATIENT**

Memphis Canniff

**SPECIES**

Canine

**BREED**

Doberman Pinscher

**SEX**

Neutered Male

**AGE**

5

**WEIGHT**

65.2 pounds

**INTERPRETED BY**

Alicia Angosto Guerrero, DMV, PgDip, MSc.

**IMAGING PERFORMED BY**

Dr. Carlos Abdul-Chani

**HOSPITAL NAME**

Byram Animal Hospital

**REFERRING VET**

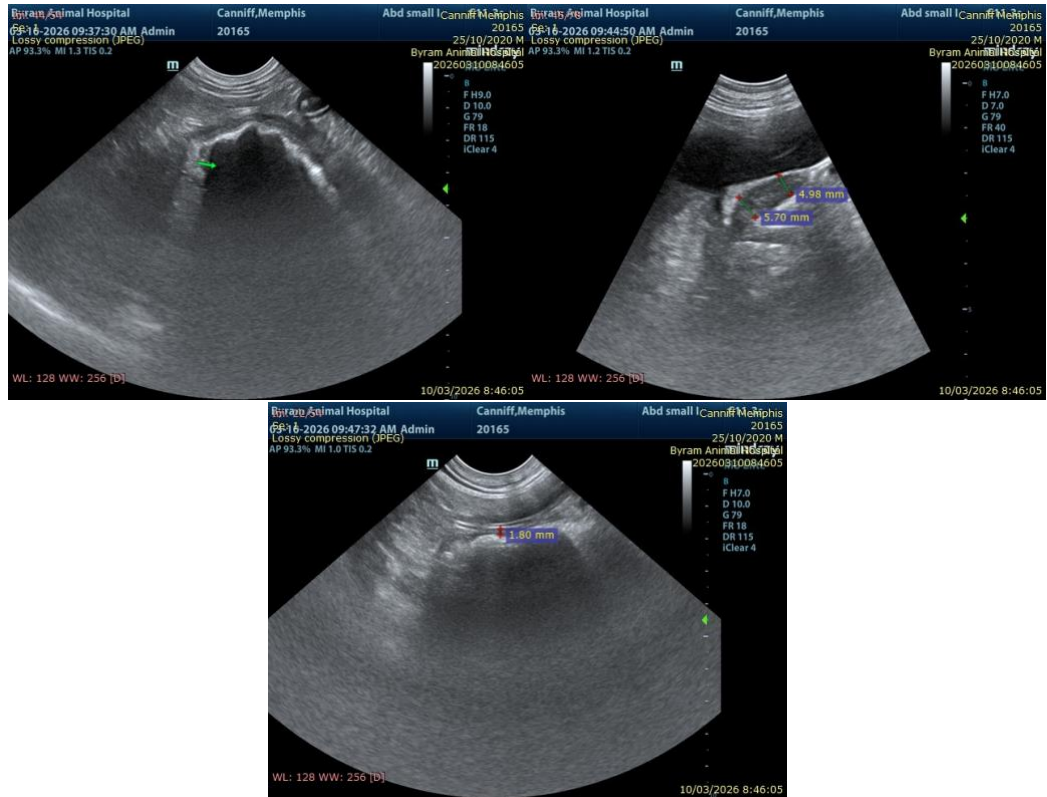
Dr. Maria Cruz

**INVOICE**

14193

**DATE**

03/10/26



The information and recommendations provided are based on the images presented by the referring veterinarian/sonographer. No evaluation can be communicated regarding pathology that was not visible in the image/video clips provided.

Thank you for this referral. If the clinical or image interpretation does not parallel your findings or if I can be of any further assistance please contact me.

Alicia Angosto Guerrero, DMV, PgDip, MSc.

[info@SonoPath.com](mailto:info@SonoPath.com)