



PATIENT

Aiesha Lemmon

SPECIES

Canine

BREED

Pitbull Mix

SEX

Spayed female

AGE

13 years

WEIGHT

65 lbs

INTERPRETED BY

Dr. Alicia Angosto
Guerrero

IMAGING PERFORMED BY

Ashley McCaughan,
DVM

HOSPITAL NAME

Marina Village
Veterinary &
Integrative Care

REFERRING VET

Dr. McCaughan

INVOICE

71406

DATE

2/9/26

PRESENTING CLINICAL SIGNS

- Older patient, abdominal ultrasound is purely informative for polydipsia concerns. Severe allergic skin disease
- Severe pododermatitis; otitis externa. Recent lab work abnormal: UA: pyuria, proteinuria, pH 8.5, WBCs, RBCs. Urine culture pending. No UPC. CBC - NSF, Chem 17 - NSF. T4 - WNL.

ULTRASONOGRAPHIC EXAMINATION OF THE ABDOMEN

Urinary System

The urinary bladder lumen is normally distended. The urinary bladder wall is thin and smooth. Urine is anechoic. The bladder neck and proximal urethra have a normal ultrasonographic appearance. No uroliths are identified. There is no ultrasonographic evidence of inflammatory or neoplastic changes.

The left kidney is normal in shape and size, measuring 6.24×3.71 cm in the sagittal plane. Cortical thickness measures 0.64 cm. A well-defined, round anechoic cyst measuring 5.79×6.12 mm is identified at the caudal pole. The right kidney is normal in shape and size, measuring 6.73×3.76 cm in the sagittal plane. Cortical thickness measures 0.66 cm. In both kidneys, the renal cortex is mildly increased in echogenicity relative to the liver parenchyma. The corticomedullary ratio and corticomedullary definition are preserved. There is no evidence of pyelectasia, nephrolithiasis, or hydronephrosis.

Adrenal Glands

The adrenal glands were not visualized on the provided images.

Spleen

Splenic thickness measures 2.44 cm. The splenic parenchyma demonstrates normal echogenicity and a fine, homogeneous echotexture. No focal splenic lesions are identified. The splenic capsule is smooth and regular.

Liver

Within the limits of the examination, the visualized hepatic lobes are subjectively normal in size and contour; not all lobes were fully visualized. The hepatic parenchyma is homogeneous and isoechoic relative to the falciform fat, with a normal echotexture. No hepatic lymphadenopathy is observed.

Gallbladder is not visualized.

Gastrointestinal

The stomach is empty and contains a large amount of gas. Gastric wall thickness measures 1.59 mm, with preserved wall layering.



PATIENT

Aiesha Lemmon

The duodenum measures between 3.98 and 4.12 mm in wall thickness. The jejunum measures between 3.30 and 3.35 mm, with preserved wall layering throughout. No ultrasonographic evidence of mural inflammation, ileus, or foreign material is identified.

SPECIES

Canine

The colon measures 0.76 mm in wall thickness and contains formed feces within the descending segment.

BREED

Pitbull Mix

Pancreas

The evaluated pancreatic regions do not show ultrasonographic evidence of overt inflammation.

SEX

Spayed female

Peritoneal Cavity

No abdominal effusion or signs of peritonitis are observed. Abdominal lymph nodes are not visualized; the surrounding regions appear unremarkable. The iliac trifurcation is normal.

AGE

13 years

WEIGHT

65 lbs

ULTRASONOGRAPHIC FINDINGS

- Mild bilateral increase in renal cortical echogenicity.
- Small, solitary renal cyst (5.79×6.12 mm) in the left kidney.

INTERPRETED BY

Dr. Alicia Angosto
Guerrero

INTERPRETATION OF THE FINDINGS & FURTHER RECOMMENDATIONS

Renal size and architecture are appropriate for body size and age. The mildly increased renal cortical echogenicity bilaterally is a common age-related or chronic change in geriatric dogs and, in the absence of renal pelvic dilation or loss of corticomedullary definition, does not indicate acute renal pathology. The small, solitary renal cyst identified in the left kidney is an incidental finding and is unlikely to be clinically significant.

IMAGING PERFORMED BY

Ashley McCaughan,
DVM

The urinary bladder appears normal, with no ultrasonographic evidence of cystitis, urolithiasis, or mural disease. Importantly, the urinalysis abnormalities (pyuria, hematuria, proteinuria, alkaline pH) are not accompanied by structural bladder or renal changes, supporting lower urinary tract infection or inflammation without ultrasonographically detectable complications at this time.

HOSPITAL NAME

Marina Village
Veterinary &
Integrative Care

The gastrointestinal tract shows normal wall thickness and preserved layering, with no evidence of inflammatory bowel disease, obstruction, or infiltrative disease. Gastric gas is considered nonspecific and likely related to aerophagia or patient positioning.

REFERRING VET

Dr. McCaughan

INVOICE

71406

Recommendations

- Prioritize interpretation of urine culture results and treat appropriately for urinary tract infection, as this remains the most likely contributor to polydipsia.
- If proteinuria persists after resolution of infection, quantitative protein assessment (UPC) is recommended to further characterize renal involvement.

DATE

2/9/26



PATIENT

Aiesha Lemmon

SPECIES

Canine

BREED

Pitbull Mix

SEX

Spayed female

AGE

13 years

WEIGHT

65 lbs

INTERPRETED BY

Dr. Alicia Angosto
Guerrero

IMAGING PERFORMED BY

Ashley McCaughan,
DVM

HOSPITAL NAME

Marina Village
Veterinary &
Integrative Care

REFERRING VET

Dr. McCaughan

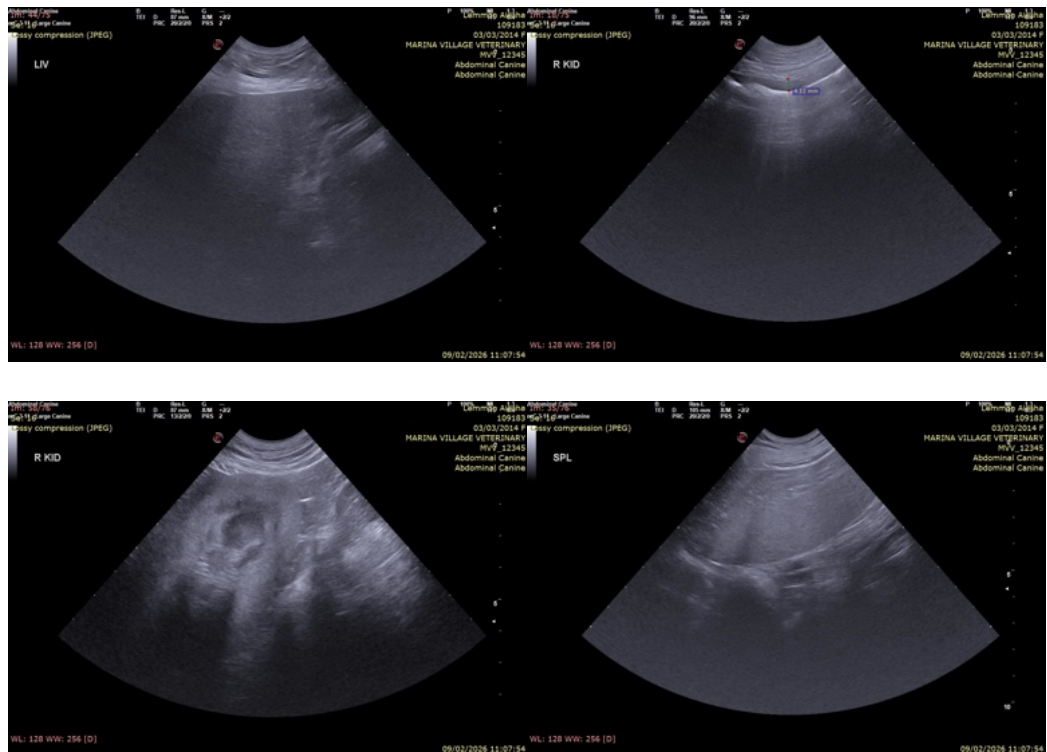
INVOICE

71406

DATE

2/9/26

- In the context of severe chronic allergic skin disease, medication-related polyuria and polydipsia should be considered, particularly if the patient is receiving glucocorticoids or other systemic therapies.
- Non-visualization of the adrenal glands limits assessment for hyperadrenocorticism; endocrine testing is recommended if clinically indicated.



The information and recommendations provided are based on the images presented by the referring veterinarian/sonographer. No evaluation can be communicated regarding pathology that was not visible in the image/video clips provided.

Thank you for this referral. If the clinical or image interpretation does not parallel your findings or if I can be of any further assistance please contact me.

Alicia Angosto Guerrero, DMV, PgDip, MSc.

MV Esp Ultrasound in Domestic and Wild Animals

info@SonoPath.com