

PATIENT

Baby Girl Lanigan

SPECIES

Canine

BREED

Chihuahua

SEX

Spayed female

AGE

14 years

WEIGHT

8.2 lbs

INTERPRETED BY

Dr. Alicia Angosto
Guerrero

IMAGING PERFORMED BY

Dr. Vincent Tavella

HOSPITAL NAME

Williamsburg VC

REFERRING VET

Dr. Tavella

INVOICE

71180

DATE

2/3/26

PRESENTING CLINICAL SIGNS

- Patient presented in October for wellness exam and senior labwork. Mildly elevated renal enzymes at that time. Owner elected to wait three months and recheck. Trending elevations noted.
- PE - Marked periodontal disease. Chem - AST: 10/25 - 75, 1/28 - 25 (15-66), ALP: 10/25 - 313, 1/28 - 491 (5-131) CBC - Thrombocytosis - persistently elevated UA: USF 1.050

ULTRASONOGRAPHIC EXAMINATION OF THE ABDOMEN

Urinary System

The urinary bladder is normally distended. The bladder wall is thin and smooth. Urine is anechoic. The bladder neck and proximal urethra appear normal. No uroliths or ultrasonographic evidence of inflammatory or neoplastic disease are identified.

The left kidney is normal in shape and size, measuring 3.41×2.03 cm, with a cortical thickness of 0.29 cm in the sagittal plane. The renal cortex is hyperechoic relative to the liver parenchyma. The corticomedullary ratio and corticomedullary distinction are preserved. No pyelectasia, nephrolithiasis, or hydronephrosis is observed.

The right kidney is normal in shape and size, measuring 4.01×1.89 cm. The renal cortex is hyperechoic relative to the liver parenchyma. One or more small cortical cysts, measuring only a few millimeters, are identified. The corticomedullary ratio and corticomedullary distinction are preserved. No pyelectasia, nephrolithiasis, or hydronephrosis is observed.

Adrenal Glands

The left adrenal gland appears mildly enlarged with a somewhat globoid configuration, measuring 0.60 cm at both the cranial and caudal poles.

The right adrenal gland is within expected size limits and maintains a more typical elongated morphology, measuring 0.52 cm at the cranial pole and 0.44 cm at the caudal pole.

Spleen

Splenic thickness is 1.05 cm. The splenic parenchyma demonstrates normal echogenicity and fine homogeneous echotexture. A small hypoechoic splenic nodule measuring 3.35×3.47 mm is identified. The splenic capsule is smooth and regular.

Liver

The liver is subjectively normal in size, with sharp margins and a regular contour. The hepatic parenchyma is homogeneous and isoechoic relative to the falciform fat, with normal echotexture. No hepatic lymphadenopathy is observed.



PATIENT

Baby Girl Lanigan

SPECIES

Canine

BREED

Chihuahua

SEX

Spayed female

AGE

14 years

WEIGHT

8.2 lbs

INTERPRETED BY

Dr. Alicia Angosto
Guerrero

IMAGING PERFORMED BY

Dr. Vincent Tavella

HOSPITAL NAME

Williamsburg VC

REFERRING VET

Dr. Tavella

INVOICE

71180

DATE

2/3/26

The gallbladder is normally distended. The wall is thin. The lumen contains a moderate amount of biliary sludge. No dilation of the cystic duct or common bile duct is identified.

Gastrointestinal

The stomach is empty and folded, with a wall thickness of 2.33 mm and preserved wall layering. The pyloric wall measures 4.24–4.71 mm, with a muscularis thickness of 1.51 mm.

The duodenum measures 2.76–3.26 mm in wall thickness. The jejunum measures 3.02 mm, with preserved wall layering. The ileocecal junction measures 2.66 mm. No ultrasonographic evidence of gastrointestinal inflammation, ileus, or foreign material is identified.

The colon wall measures 0.93 mm and contains formed fecal material within the descending segment.

Pancreas

The right pancreatic limb measures 8.27 mm. The pancreatic parenchyma is isoechoic relative to the adjacent omental fat. No ultrasonographic evidence of pancreatitis is identified.

Peritoneal Cavity

No abdominal effusion or ultrasonographic evidence of peritonitis is observed. Abdominal lymph nodes are not visualized; the surrounding regions appear unremarkable. The iliac trifurcation appears normal.

ULTRASONOGRAPHIC FINDINGS

PRIMARY FINDINGS

- Bilateral renal cortical hyperechogenicity consistent with chronic renal change. Small right renal cortical cysts.
- Borderline bilateral adrenal enlargement.

SECONDARY FINDINGS

- Moderate biliary sludge.
- Small hypoechoic splenic nodule.

INTERPRETATION OF THE FINDINGS & FURTHER RECOMMENDATIONS

Bilateral renal cortical hyperechogenicity with preserved corticomedullary distinction is most consistent with chronic renal change, which correlates with the patient's age and previously noted renal parameter trends. The small right renal cortical cysts are considered incidental age-related findings.

Mild asymmetric adrenal change is present, characterized by a mildly globoid left adrenal gland with a relatively normal-appearing right adrenal gland. In conjunction with the progressive elevation in



PATIENT

Baby Girl Lanigan

alkaline phosphatase and persistent thrombocytosis, these findings raise suspicion for functional adrenal hyperplasia or early hyperadrenocorticism; however, ultrasonography alone cannot establish this diagnosis.

SPECIES

Canine

The gallbladder contains a moderate amount of biliary sludge, a common finding in geriatric dogs that may be incidental but can also be associated with cholestasis, endocrine disease, or altered bile composition. No evidence of biliary obstruction is identified. A normal hepatic ultrasonographic appearance does not preclude early or functional hepatopathy, particularly in the context of endocrine or metabolic disease.

BREED

Chihuahua

The small hypochoic splenic nodule is most consistent with a benign incidental lesion such as nodular hyperplasia, particularly given its small size and lack of associated splenomegaly or lymphadenopathy.

SEX

Spayed female

Recommendations

- Correlate adrenal and hepatobiliary findings with endocrine testing (screening for hyperadrenocorticism), as clinically indicated, given progressive ALP elevation and mild bilateral adrenal enlargement.
- Continue monitoring renal function and urine parameters.

AGE

14 years

WEIGHT

8.2 lbs

INTERPRETED BY

Dr. Alicia Angosto
Guerrero

IMAGING PERFORMED BY

Dr. Vincent Tavella

HOSPITAL NAME

Williamsburg VC

REFERRING VET

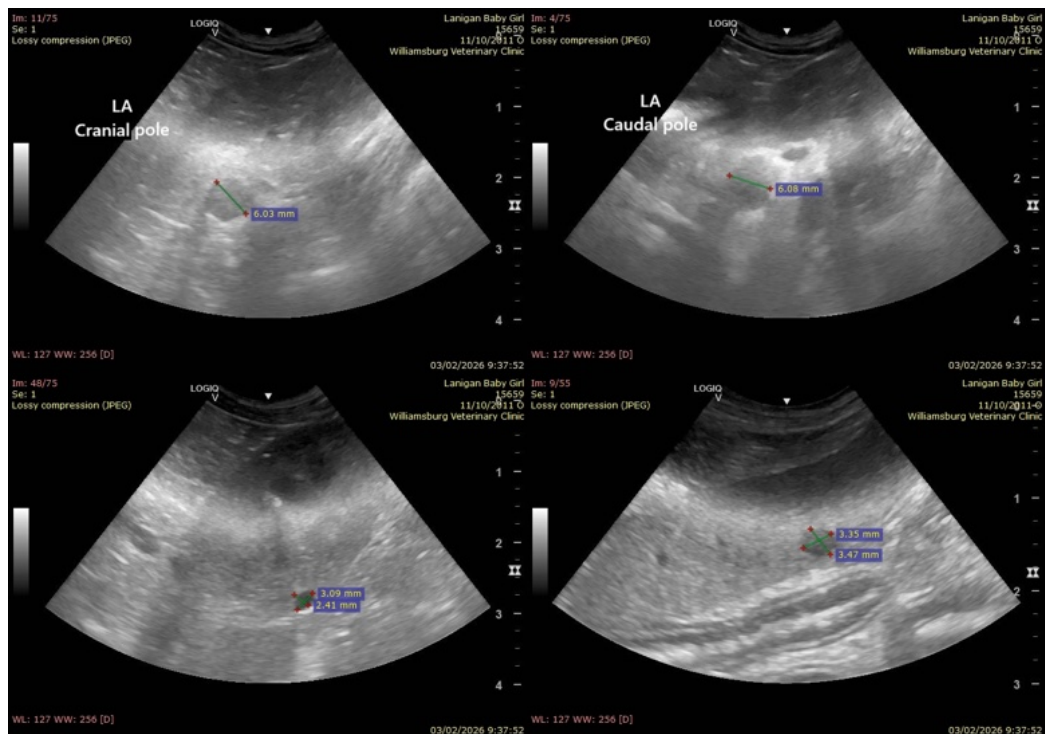
Dr. Tavella

INVOICE

71180

DATE

2/3/26





PATIENT

Baby Girl Lanigan

SPECIES

Canine

BREED

Chihuahua

SEX

Spayed female

AGE

14 years

WEIGHT

8.2 lbs

INTERPRETED BY

Dr. Alicia Angosto
Guerrero

IMAGING PERFORMED BY

Dr. Vincent Tavella

HOSPITAL NAME

Williamsburg VC

REFERRING VET

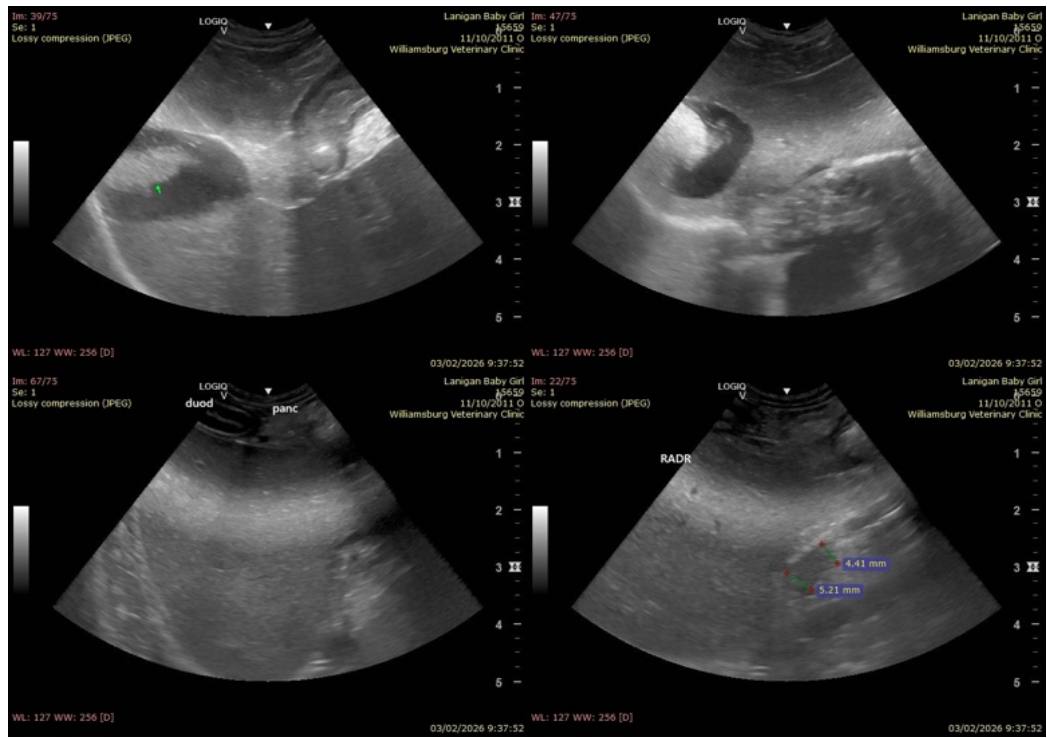
Dr. Tavella

INVOICE

71180

DATE

2/3/26



The information and recommendations provided are based on the images presented by the referring veterinarian/sonographer. No evaluation can be communicated regarding pathology that was not visible in the image/video clips provided.

Thank you for this referral. If the clinical or image interpretation does not parallel your findings or if I can be of any further assistance please contact me.

Alicia Angosto Guerrero, DMV, PgDip, MSc.

MV Esp Ultrasound in Domestic and Wild Animals

info@SonoPath.com