



## PATIENT

Kit Kat Reilley

## SPECIES

Feline

## BREED

Domestic Shorthair

## SEX

Spayed female

## AGE

6 years

## WEIGHT

14.11 lbs

## INTERPRETED BY

Dr. Alicia Angosto  
Guerrero

## IMAGING PERFORMED BY

Renee Ziegler Post

## HOSPITAL NAME

For Cats Only VC

## REFERRING VET

Dr. Renee Ziegler Post

## INVOICE

71988

## DATE

2/26/26

## PRESENTING CLINICAL SIGNS

- Chronic impacted anal glands

## ULTRASONOGRAPHIC EXAMINATION OF THE ABDOMEN

### *Urinary System*

The bladder lumen is normally distended, and the wall of the urinary bladder appears thin and smooth. The urine is predominantly anechoic with scant suspended echoes. Normal appearance of the bladder neck and proximal urethra. There are no calculi and no evidence of inflammatory or neoplastic changes.

The left kidney is normal in shape and size: 3.71 x 2.03 cm, and the thickness of the cortex is 0.34 cm, in the sagittal plane. The cortex is isoechoic compared to the liver parenchyma. The corticomedullary ratio is normal, and corticomedullary definition is preserved. There is no evidence of pyelectasia, nephrolithiasis, or hydronephrosis. Color Doppler shows a normal vascular pattern.

The right kidney is normal in shape and size: 3.90 x 1.75 cm, and the thickness of the cortex is 0.31 cm, in the sagittal plane. The cortex is isoechoic compared to the liver parenchyma. The corticomedullary ratio is normal, and corticomedullary definition is preserved. There is no evidence of pyelectasia, nephrolithiasis, or hydronephrosis. Color Doppler shows a normal vascular pattern.

### *Adrenal Glands*

Both adrenal glands show normal shape and echogenicity. Dorsoventral diameters measured in the sagittal plane: The left adrenal gland measures 0.28 cm at the cranial pole and 0.28 cm at the caudal pole. The right adrenal gland measures 0.24 cm at the cranial pole and 0.25 cm at the caudal pole.

### *Spleen*

Splenic thickness is 0.79 cm. The parenchyma demonstrates normal echogenicity and fine homogeneous echotexture without focal parenchymal abnormalities. The splenic capsule is smooth and regular.

### *Liver*

The liver is subjectively normal in size, with sharp edges and a regular contour. The hepatic parenchyma appears homogeneous and isoechoic relative to the surrounding fat, with normal echotexture. No hepatic lymphadenopathy is observed.

The gallbladder lumen is normally distended. The wall is thin, and the contents are primarily anechoic. No dilation of the cystic duct or common bile duct is observed.

### *Gastrointestinal*

The stomach is empty and folded, with mural thickness (1.40 mm) and preserved wall layering. The pylorus measures 2.91 mm.



## PATIENT

Kit Kat Reilley

## SPECIES

Feline

## BREED

Domestic Shorthair

## SEX

Spayed female

## AGE

6 years

## WEIGHT

14.11 lbs

## INTERPRETED BY

Dr. Alicia Angosto  
Guerrero

## IMAGING PERFORMED BY

Renee Ziegler Post

## HOSPITAL NAME

For Cats Only VC

## REFERRING VET

Dr. Renee Ziegler Post

## INVOICE

71988

## DATE

2/26/26

Duodenum: 1.38 mm. Jejunum: 2.47 mm. Mucosa: 1.34 mm. Submucosa: 0.58 mm. Muscularis propria: 0.53 mm. Ileum: 1.96 mm. Wall layering preserved. The individual mural layers are thin, which limits precise measurement; however, architecture appears normal. Ileocecal junction: 2.58 mm, muscularis 0.59 mm. No signs of inflammation, ileus, or foreign material are identified.

Colon: Ascending colon 0.79 mm, transverse colon 0.93 mm, and descending segment 1.43 mm. Wall layering preserved. The colon is predominantly empty and gas-filled, with a small amount of formed fecal material in the distal descending portion.

### ***Pancreas***

The evaluated pancreatic regions do not show ultrasonographic evidence of overt inflammation.

### ***Peritoneal Cavity***

No abdominal effusion or peritonitis is observed. Cranial mesenteric lymph nodes appear unremarkable. Ileocecal lymph nodes measure 2.08 mm in thickness, with normal shape and echogenicity. The iliac trifurcation appears normal.

### **ULTRASONOGRAPHIC FINDINGS**

No clinically significant ultrasonographic abnormalities identified.

### **INTERPRETATION OF THE FINDINGS & FURTHER RECOMMENDATIONS**

Abdominal ultrasound is within normal limits. No ultrasonographic abnormalities are identified to explain the history of chronic anal gland impaction. The colon is largely decompressed and gas-filled, without mural thickening or structural changes. Regional lymph nodes are normal in size and morphology.

There is no evidence of rectal mural disease, regional lymphadenopathy, or abdominal inflammatory process on this examination.

#### Recommendations

- Findings support a functional or localized perineal/anal sac disorder rather than intra-abdominal disease.
- Continued local management of anal sac disease is appropriate.
- If clinical signs change (tenesmus, hematochezia, palpable mass), targeted perineal imaging or rectal examination under sedation may be considered.



**PATIENT**

Kit Kat Reilley

**SPECIES**

Feline

**BREED**

Domestic Shorthair

**SEX**

Spayed female

**AGE**

6 years

**WEIGHT**

14.11 lbs

**INTERPRETED BY**

Dr. Alicia Angosto  
Guerrero

**IMAGING PERFORMED BY**

Renee Ziegler Post

**HOSPITAL NAME**

For Cats Only VC

**REFERRING VET**

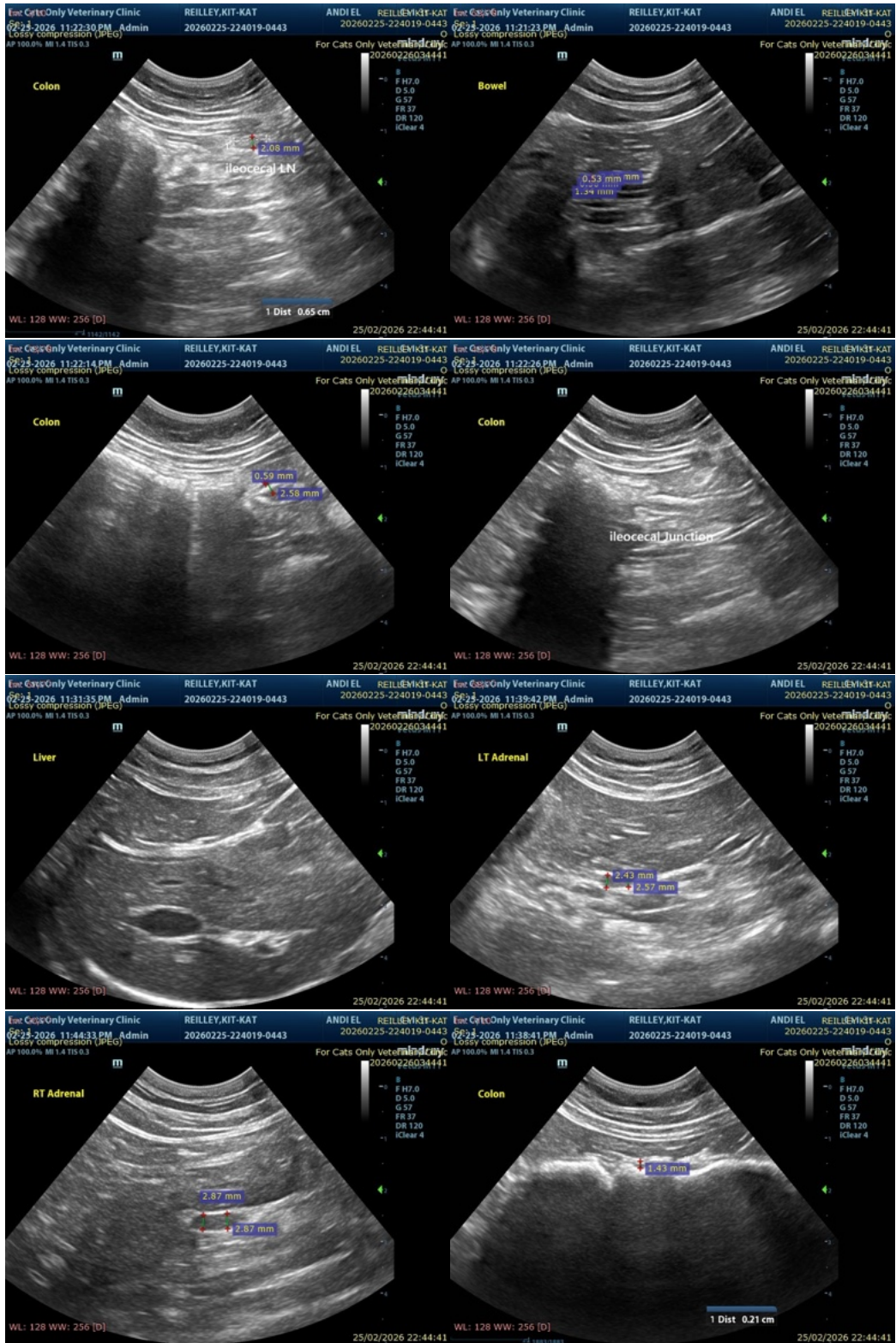
Dr. Renee Ziegler Post

**INVOICE**

71988

**DATE**

2/26/26





## PATIENT

Kit Kat Reilley

## SPECIES

Feline

## BREED

Domestic Shorthair

## SEX

Spayed female

## AGE

6 years

## WEIGHT

14.11 lbs

## INTERPRETED BY

Dr. Alicia Angosto  
Guerrero

## IMAGING PERFORMED BY

Renee Ziegler Post

## HOSPITAL NAME

For Cats Only VC

## REFERRING VET

Dr. Renee Ziegler Post

## INVOICE

71988

## DATE

2/26/26

The information and recommendations provided are based on the images presented by the referring veterinarian/sonographer. No evaluation can be communicated regarding pathology that was not visible in the image/video clips provided.

Thank you for this referral. If the clinical or image interpretation does not parallel your findings or if I can be of any further assistance please contact me.

Alicia Angosto Guerrero, DMV, PgDip, MSc.

MV Esp Ultrasound in Domestic and Wild Animals

[info@SonoPath.com](mailto:info@SonoPath.com)