



## PATIENT

Doozer Dusi

## SPECIES

Canine

## BREED

Shih Tzu

## SEX

Neutered male

## AGE

9 years

## WEIGHT

15.3 lbs

## INTERPRETED BY

Dr. Alicia Angosto  
Guerrero

## IMAGING PERFORMED BY

Devon Papa CVT

## HOSPITAL NAME

Valley VS

## REFERRING VET

Dr. Riddlebaugh

## INVOICE

71936

## DATE

2/25/26

## PRESENTING CLINICAL SIGNS

- Elevated liver enzymes found on routine bloodwork October 2025. Perio disease present so scheduled dental; done November 2025. Liver enzymes checked two months later. Enzymes continued to increase despite dental cleaning. Started Denamarin. Checked again 1mo later, still increasing. UCCR pending.
- 10/9/2025: MCV 58.0 (61.6-73.5) RETIC-HGB 20.5 (22.3-29.6) ALKP 491 (23-212) 1/5/2026 (run on different machine, reference ranges will be different. Not fasted): ALKP 637 (20.0-150.0) GGT 9 (0.0-7.0) BA 47 (0.0-25.0) 2/10/2026 (fasted): ALKP 936 (20.0-150.0) ALT 146 (10.0-118.0) GGT 7 (0.0-7.0) BA 29 (0.0-25.0)

## ULTRASONOGRAPHIC EXAMINATION OF THE ABDOMEN

### Urinary System

The urinary bladder lumen is normally distended, and the wall appears thin and smooth. The urine is anechoic. The bladder neck and proximal urethra appear normal. No calculi are identified, and there is no evidence of inflammatory or neoplastic changes.

The left kidney is normal in shape and size: 3.99 x 2.34 cm, and the cortical thickness is 0.41 cm in the sagittal plane. The cortex is isoechoic compared to the liver parenchyma. The corticomedullary ratio is normal, and corticomedullary definition is preserved. There is no evidence of pyelectasia, nephrolithiasis, or hydronephrosis. Color Doppler demonstrates a normal vascular pattern.

The right kidney is normal in shape and size: 4.16 x 2.35 cm, and the cortical thickness is 0.39 cm in the sagittal plane. The cortex is isoechoic compared to the liver parenchyma. The corticomedullary ratio is normal, and corticomedullary definition is preserved. There is no evidence of pyelectasia, nephrolithiasis, or hydronephrosis. Color Doppler demonstrates a normal vascular pattern.

### Adrenal Glands

Both adrenal glands show normal shape and echogenicity. Dorsoventral diameters measured in the sagittal plane: The left adrenal gland measures 0.35 cm at the cranial pole and 0.37 cm at the caudal pole. The right adrenal gland: cranial pole not visualized; caudal pole measures 0.43 cm.

### Spleen

Splenic thickness is 1.56 cm. The parenchyma demonstrates normal echogenicity and fine homogeneous echotexture without focal abnormalities. The splenic capsule is smooth and regular.

### Liver

The liver is subjectively normal in size, with sharp edges and a regular contour. The parenchyma appears uniform and isoechoic compared to the falciform fat, with normal echotexture. No ultrasonographic attenuation of the ultrasound beam is observed. No hepatic lymphadenopathy is identified.



## PATIENT

Doozer Dusi

The gallbladder lumen is moderately distended. The wall is thin, and the contents are predominantly anechoic with a very small amount of biliary sludge. No dilation of the cystic duct or common bile duct is observed.

## SPECIES

Canine

### *Gastrointestinal*

## BREED

Shih Tzu

The stomach is empty and folded, with mural thickness of 1.62 mm and preserved wall layering. Pylorus: 3.71 mm. Duodenum: 3.67 mm. Jejunum: 3.55 mm, with preserved wall layering. No evidence of inflammation, ileus, or foreign material is identified.

Colon: 0.91–1.09 mm, with formed feces throughout all segments.

## SEX

Neutered male

### *Pancreas*

## AGE

9 years

Right limb: 7.95 mm in thickness. Left limb: 6.89 mm in thickness. The pancreatic parenchyma is isoechoic relative to the adjacent omental fat. No sonographic evidence of active inflammation or neoplastic disease is identified.

## WEIGHT

15.3 lbs

### *Peritoneal Cavity*

## INTERPRETED BY

Dr. Alicia Angosto  
Guerrero

No sonographic evidence of abdominal effusion, peritonitis, or lymphadenomegaly is identified. The iliac trifurcation appears normal.

## ULTRASONOGRAPHIC FINDINGS

No structural hepatic abnormalities are identified.

## IMAGING PERFORMED BY

Devon Papa CVT

## INTERPRETATION OF THE FINDINGS & FURTHER RECOMMENDATIONS

## HOSPITAL NAME

Valley VS

The liver is sonographically unremarkable in size, contour, and echotexture. No irregular margins, nodular disease, parenchymal heterogeneity, attenuation changes, or biliary obstruction is identified. The gallbladder contains minimal sludge without wall thickening or ductal dilation. These findings do not support obstructive cholestasis or structural infiltrative hepatic disease.

## REFERRING VET

Dr. Riddlebaugh

The adrenal glands are within normal size limits for a dog of this size (all measurements <0.5 cm). There is no ultrasonographic evidence of adrenal enlargement suggestive of pituitary-dependent or adrenal-dependent hyperadrenocorticism at this time.

## INVOICE

71936

Overall, this ultrasound examination does not identify a structural hepatic cause for the progressive cholestatic enzyme elevation. In small-breed dogs, particularly Shih Tzus, a normal-appearing liver with rising ALP and mildly increased bile acids most commonly supports a functional or metabolic hepatopathy rather than overt structural disease.

## DATE

2/25/26

### Recommendations

- If liver enzyme values continue to increase or bile acids worsen, hepatic sampling may be considered to obtain a definitive diagnosis.



**PATIENT**

Doozer Dusi

**SPECIES**

Canine

**BREED**

Shih Tzu

**SEX**

Neutered male

**AGE**

9 years

**WEIGHT**

15.3 lbs

**INTERPRETED BY**

Dr. Alicia Angosto Guerrero

**IMAGING PERFORMED BY**

Devon Papa CVT

**HOSPITAL NAME**

Valley VS

**REFERRING VET**

Dr. Riddlebaugh

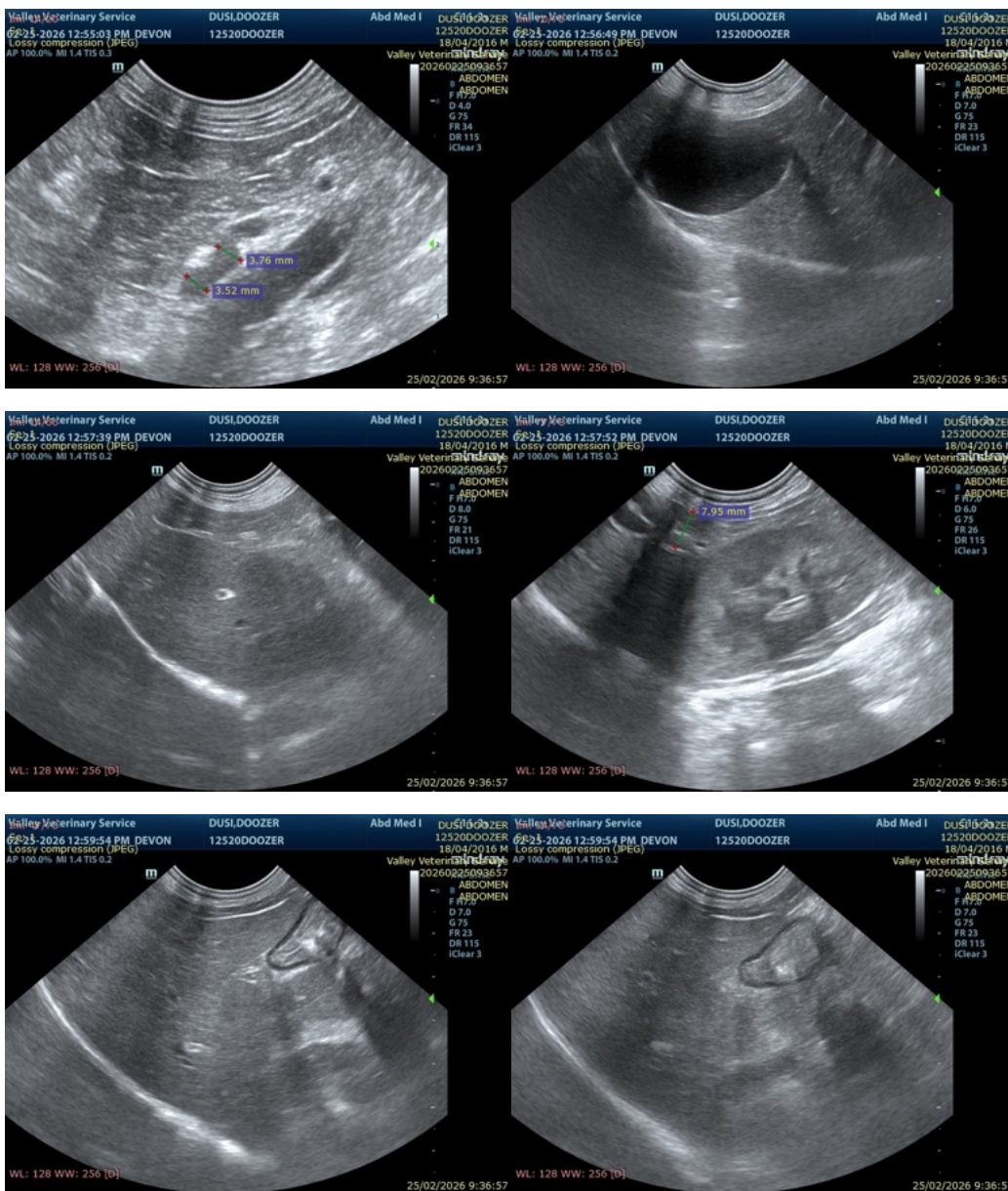
**INVOICE**

71936

**DATE**

2/25/26

- Serial biochemical monitoring is recommended to assess progression and guide further diagnostic decision-making.





## PATIENT

Doozer Dusi

## SPECIES

Canine

## BREED

Shih Tzu

## SEX

Neutered male

## AGE

9 years

## WEIGHT

15.3 lbs

## INTERPRETED BY

Dr. Alicia Angosto  
Guerrero

## IMAGING PERFORMED BY

Devon Papa CVT

## HOSPITAL NAME

Valley VS

## REFERRING VET

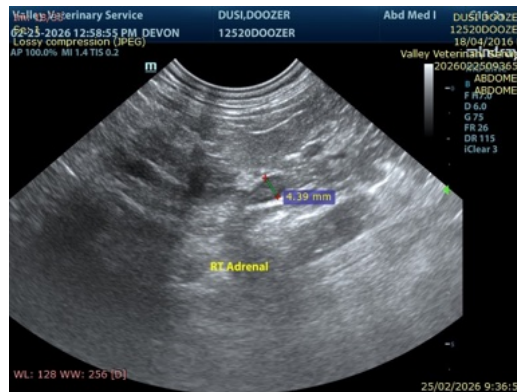
Dr. Riddlebaugh

## INVOICE

71936

## DATE

2/25/26



The information and recommendations provided are based on the images presented by the referring veterinarian/sonographer. No evaluation can be communicated regarding pathology that was not visible in the image/video clips provided.

Thank you for this referral. If the clinical or image interpretation does not parallel your findings or if I can be of any further assistance please contact me.

Alicia Angosto Guerrero, DMV, PgDip, MSc.

MV Esp Ultrasound in Domestic and Wild Animals

[info@SonoPath.com](mailto:info@SonoPath.com)