



PATIENT

Party Mix Montgomery

SPECIES

Feline

BREED

Domestic Shorthair

SEX

Spayed female

AGE

13 ½ years

WEIGHT

4.82 kg

INTERPRETED BY

Dr. Alicia Angosto
Guerrero

IMAGING PERFORMED BY

Danielle RVT

HOSPITAL NAME

Orchard VC

REFERRING VET

Dr. Antonopoulos

INVOICE

71791

DATE

2/23/26

PRESENTING CLINICAL SIGNS

- PU/PD
- Senior wellness check
- CBC: -all values within normal limits Chemistry: -moderate hyperproteinemia characterized by mild hyperglobulinemia -moderately elevated amylase -all other values within normal limits Urinalysis: -2+ proteinuria -inactive sediment; -all other values within normal limits USG 1.028 - moderately concentrated sample

ULTRASONOGRAPHIC EXAMINATION OF THE ABDOMEN

Urinary System

The bladder lumen is moderately distended, and the wall of the urinary bladder appears thin and smooth. The urine is anechoic. Normal appearance of the bladder neck and proximal urethra. There are no calculi and no sonographic evidence of inflammatory or neoplastic changes.

The left kidney measures 3.33 x 2.54 cm and appears mildly rounded in contour. Cortical thickness measures 0.49 cm in the sagittal plane. The cortex is isoechoic compared to the liver parenchyma. In the pelvic region, small punctate hyperechoic foci with mild distal acoustic shadowing are observed, compatible with pelvic mineralization or small nephroliths. No renal pelvic dilation is identified. Color Doppler demonstrates normal vascular pattern.

The right kidney measures 3.81 x 2.56 cm, with cortical thickness measuring 0.52 cm in the sagittal plane. The cortex is isoechoic compared to the liver parenchyma, and corticomedulary definition is preserved. There is no evidence of pyelectasia, nephrolithiasis, or hydronephrosis. Color Doppler demonstrates normal vascular pattern.

Adrenal Glands

Both adrenal glands demonstrate normal shape and echogenicity. Dorsoventral diameters measured in the sagittal plane: the left adrenal gland measures 0.31 cm at the cranial pole and 0.30 cm at the caudal pole. The right adrenal gland measures 0.28 cm at the cranial pole and 0.25 cm at the caudal pole.

Spleen

Splenic thickness is 0.87 cm. The parenchyma demonstrates normal echogenicity and fine homogeneous echotexture. Splenic vasculature appears normal.

Liver

The liver is subjectively normal in size, with sharp edges and a regular contour. The hepatic parenchyma is uniform and isoechoic compared to the falciform fat, with normal echotexture. A single, well-defined, round, multicystic hepatic nodule measuring approximately 1.07 x 0.63 cm is identified at the caudal



PATIENT

Party Mix Montgomery

SPECIES

Feline

BREED

Domestic Shorthair

SEX

Spayed female

AGE

13 ½ years

WEIGHT

4.82 kg

INTERPRETED BY

Dr. Alicia Angosto
Guerrero

IMAGING PERFORMED BY

Danielle RVT

HOSPITAL NAME

Orchard VC

REFERRING VET

Dr. Antonopoulos

INVOICE

71791

DATE

2/23/26

margin of the left medial hepatic lobe, immediately ventral to the pylorus. The lesion does not distort the hepatic capsule. No hepatic lymphadenopathy is observed.

The gallbladder lumen is normally distended. The wall is thin. A moderate amount of organized mineralized sediment is present near the gallbladder neck and proximal cystic duct. The common bile duct appears normal in diameter.

Gastrointestinal

The stomach is empty and folded, with mural thickness measuring 1.46 mm and preserved wall layering. The pylorus measures 2.37 mm with minimal residual digested ingesta. The duodenum measures 1.64 mm. The jejunum measures 2.17 mm, with mucosa 1.28 mm, submucosa 0.48 mm, and muscularis propria 0.36 mm. The ileum measures 1.87 mm, with mucosa 0.56 mm, submucosa 0.65 mm, and muscularis propria 0.42 mm, with preserved wall layering. The ileocecal junction measures 2.62 mm, with muscularis measuring 1.37 mm. No signs of inflammation, ileus, or foreign material are identified. The ascending colon measures 0.94–1.14 mm with minimal fecal material in the descending segment.

Pancreas

All pancreatic regions appear normal with no sonographic evidence of overt inflammation.

Peritoneal Cavity

No abdominal effusion or peritonitis is observed. Cranial mesenteric lymph nodes measure 3.37–2.98 mm in thickness and appear normal in morphology. Ileocecal lymph nodes are small and within normal limits. No sonographic evidence of lymphadenomegaly is identified. The iliac trifurcation appears normal.

ULTRASONOGRAPHIC FINDINGS

PRIMARY FINDINGS

- Small non-obstructive mineral foci in the left renal pelvis.
- Cortical thickness measurements at the upper end of normal in both kidneys.

SECONDARY FINDINGS

- Small multicystic hepatic nodule (incidental).
- Mineralized biliary sediment near the gallbladder neck.

INTERPRETATION OF THE FINDINGS & FURTHER RECOMMENDATIONS

Renal size is within accepted feline reference ranges. Cortical thickness measurements of 0.49 cm and 0.52 cm are at the upper end of normal for cats but remain within published reference limits. Small



PATIENT

Party Mix Montgomery

SPECIES

Feline

BREED

Domestic Shorthair

SEX

Spayed female

AGE

13 ½ years

WEIGHT

4.82 kg

INTERPRETED BY

Dr. Alicia Angosto
Guerrero

IMAGING PERFORMED BY

Danielle RVT

HOSPITAL NAME

Orchard VC

REFERRING VET

Dr. Antonopoulos

INVOICE

71791

DATE

2/23/26

mineralized foci within the left renal pelvis are compatible with non-obstructive nephrolithiasis or pelvic mineralization. No pelvic dilation is present.

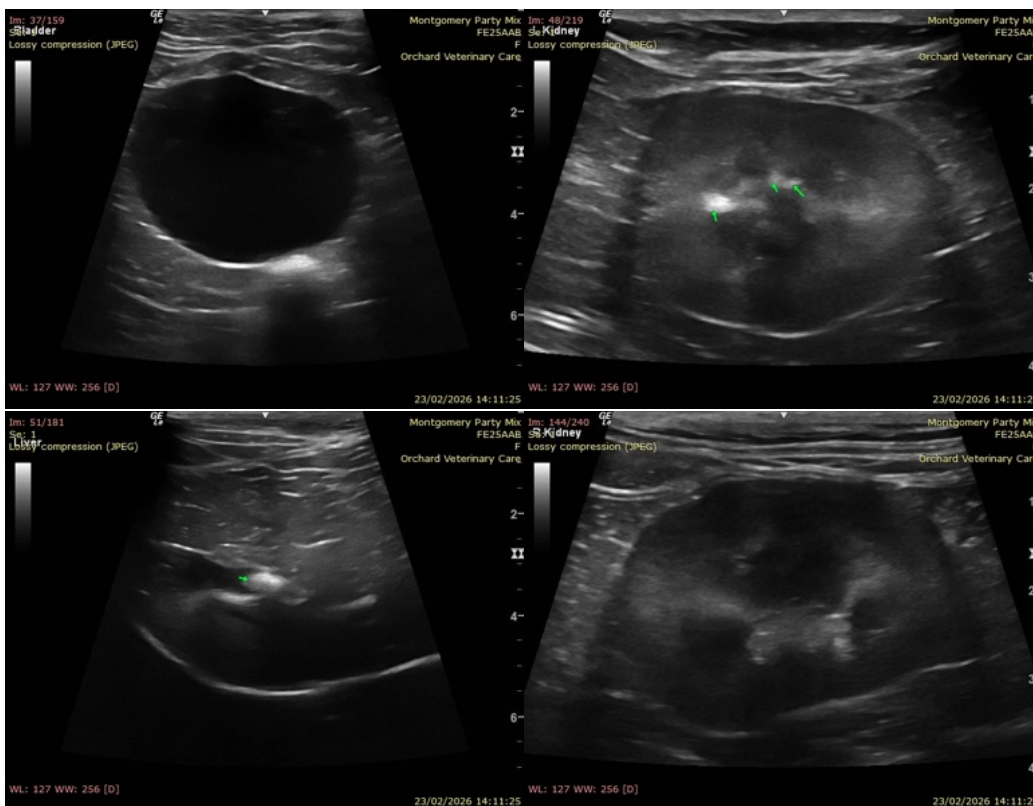
Given the history of PU/PD, moderate proteinuria with inactive sediment, and USG of 1.028, early renal disease – potentially glomerular in nature – cannot be excluded. However, there is currently no ultrasonographic evidence of advanced chronic kidney disease.

The single small multicystic hepatic nodule is well-defined, non-invasive, and does not distort surrounding architecture. In a 13-year-old cat, this most likely represents a benign biliary cystadenoma, cystic hyperplasia, or other benign cystic hepatobiliary lesion. There are no features suggestive of aggressive or infiltrative hepatic disease.

Organized mineralized sediment within the gallbladder neck likely represents biliary sludge with mineralization. In the absence of ductal dilation or wall thickening, obstructive biliary disease is not supported.

Recommendations

- Correlation with UPC and blood pressure is strongly recommended to evaluate for early renal or glomerular disease.
- SDMA assessment if not already performed.
- Recheck renal values and urinalysis in 2–3 months.
- Measurement of total T4 is recommended in light of the patient's age and history of PU/PD.





PATIENT

Party Mix Montgomery

SPECIES

Feline

BREED

Domestic Shorthair

SEX

Spayed female

AGE

13 ½ years

WEIGHT

4.82 kg

INTERPRETED BY

Dr. Alicia Angosto
Guerrero

IMAGING PERFORMED BY

Danielle RVT

HOSPITAL NAME

Orchard VC

REFERRING VET

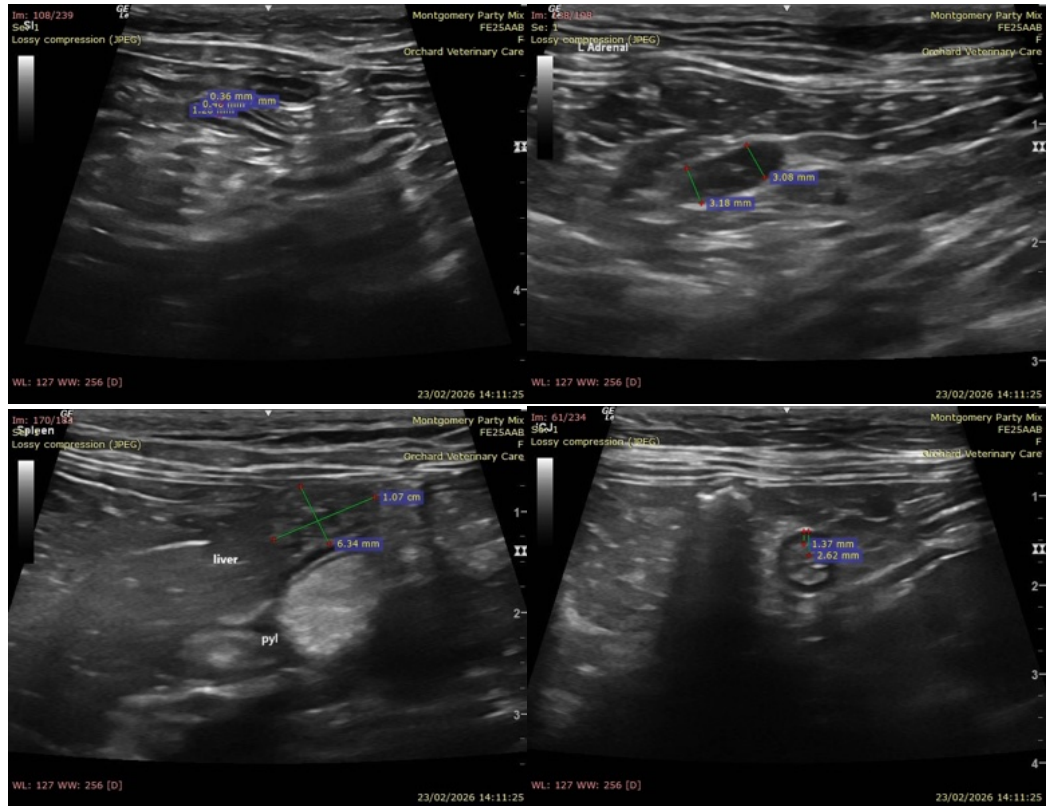
Dr. Antonopoulos

INVOICE

71791

DATE

2/23/26



The information and recommendations provided are based on the images presented by the referring veterinarian/sonographer. No evaluation can be communicated regarding pathology that was not visible in the image/video clips provided.

Thank you for this referral. If the clinical or image interpretation does not parallel your findings or if I can be of any further assistance please contact me.

Alicia Angosto Guerrero, DMV, PgDip, MSc.

MV Esp Ultrasound in Domestic and Wild Animals

info@SonoPath.com