



## PATIENT

Leo Hoagland

## SPECIES

Feline

## BREED

DSH

## SEX

NM

## AGE

9.7 years

## WEIGHT

12.05 lbs

## INTERPRETED BY

Alicia Angosto  
Guerrero, DMV,  
PgDip, MSc.

## IMAGING PERFORMED BY

Dr. Pamela Bay

## HOSPITAL NAME

For Cats Only  
Veterinary Clinic

## REFERRING VET

Dr. Pamela Bay

## INVOICE

11318

## DATE

2/13/2026

## PRESENTING CLINICAL SIGNS

- Not eating, adr.

## ULTRASONOGRAPHIC EXAMINATION OF THE ABDOMEN

### Urinary System

The urinary bladder is normally distended. The wall appears thin and smooth. The urine is predominantly anechoic with scant suspended echoes. The bladder neck and proximal urethra appear normal. No calculi or mural abnormalities are identified.

The left kidney measures 3.74×2.74 cm in the sagittal plane, with a cortical thickness of 0.46 cm. The cortex is mildly hyperechoic relative to the spleen. Corticomedullary ratio and definition are preserved. No pyelectasia, nephrolithiasis, or hydronephrosis is identified. Doppler color demonstrates normal vascular flow.

The right kidney measures 4.10×2.80 cm in the sagittal plane, with a cortical thickness of 0.45 cm. The cortex is mildly hyperechoic relative to the liver. Corticomedullary ratio and definition are preserved. No pyelectasia, nephrolithiasis, or hydronephrosis is identified. Doppler color demonstrates normal vascular flow.

### Adrenal Glands

The left adrenal gland measures 0.30 cm at the cranial pole and 0.34 cm at the caudal pole.

The right adrenal gland was not visualized.

The left adrenal measurements fall within normal feline reference ranges (generally ≤0.45 cm dorsoventral thickness).

### Spleen

Splenic thickness measures 0.95 cm. The parenchyma is homogeneous with normal echogenicity and fine echotexture. No focal lesions are identified.

### Liver

The liver is subjectively normal in size, with sharp margins and regular contour. The parenchyma is uniform and isoechoic relative to the falciform fat. No hepatic lymphadenopathy is observed.

The gallbladder is normally distended. The wall is thin. The contents are anechoic. No dilation of the cystic duct or common bile duct is identified.

### Gastrointestinal

The stomach is empty and folded. Wall layering is preserved. The pylorus measures 3.47 mm and contains scant residual ingesta.

The duodenum measures 1.10 mm.

The jejunum measures 1.63 mm.

The ileum measures 1.40 mm.

Wall layering is preserved throughout.



## PATIENT

The ileocecal junction was not visualized.

Leo Hoagland

The colon measures 0.74 mm (transverse) and 1.10 mm (descending), with formed feces present in all evaluated segments.

## SPECIES

No obstruction, mural mass, ileus, or intraluminal foreign material is identified.

Feline

## Pancreas

## BREED

The evaluated pancreatic regions do not show ultrasonographic evidence of overt inflammation or focal mass.

DSH

## Free Abdomen

## SEX

No abdominal effusion or peritonitis is observed. Cranial mesenteric and ileocecal lymph nodes are not visualized, and the surrounding regions appear unremarkable. The iliac trifurcation region is normal.

NM

## AGE

## PRIMARY FINDINGS

9.7 years

- Mild bilateral renal cortical hyperechogenicity.

## WEIGHT

## INTERPRETATION OF THE FINDINGS & FURTHER RECOMMENDATIONS

12.05 lbs

Abdominal ultrasound does not identify a structural abnormality to explain anorexia in this patient. The liver, biliary system, gastrointestinal tract, and pancreas appear within normal ultrasonographic limits. There is no evidence of mechanical obstruction, infiltrative intestinal disease, pancreatitis, or abdominal mass.

## INTERPRETED BY

Alicia Angosto  
Guerrero, DMV,  
PgDip, MSc.

The kidneys demonstrate mild bilateral cortical hyperechogenicity with preserved architecture. In a 9–10-year-old cat, this may represent early chronic renal change; however, in the absence of azotemia or inappropriate urine concentration, this finding may be incidental. Clinical pathology correlation is recommended.

## IMAGING PERFORMED BY

Importantly, a normal abdominal ultrasound does not exclude early or functional pancreatitis, hepatic cholangiohepatitis or lipidosis in early stages, metabolic or systemic illness, or toxin exposure.

Dr. Pamela Bay

## Recommendations

## HOSPITAL NAME

- Correlation with complete bloodwork.

For Cats Only  
Veterinary Clinic

## REFERRING VET

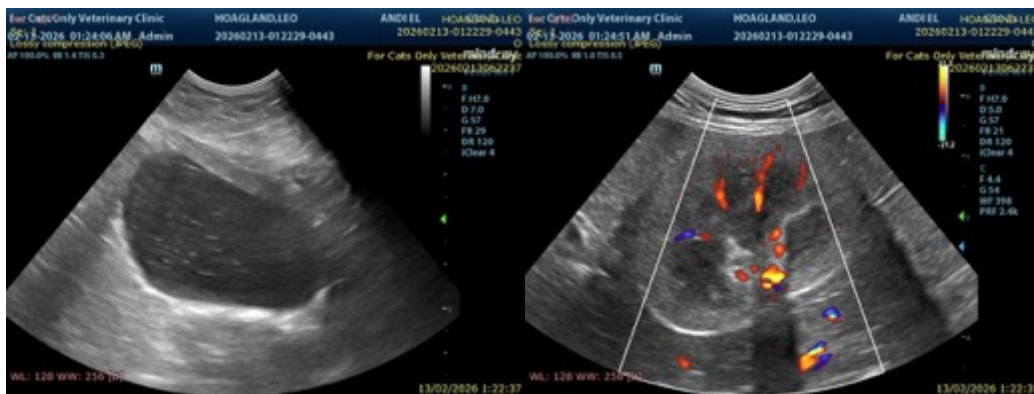Dr. Pamela Bay

## INVOICE

11318

## DATE

2/13/2026





**PATIENT**

Leo Hoagland

**SPECIES**

Feline

**BREED**

DSH

**SEX**

NM

**AGE**

9.7 years

**WEIGHT**

12.05 lbs

**INTERPRETED BY**

Alicia Angosto  
Guerrero, DMV,  
PgDip, MSc.

**IMAGING PERFORMED BY**

Dr. Pamela Bay

**HOSPITAL NAME**

For Cats Only  
Veterinary Clinic

**REFERRING VET**

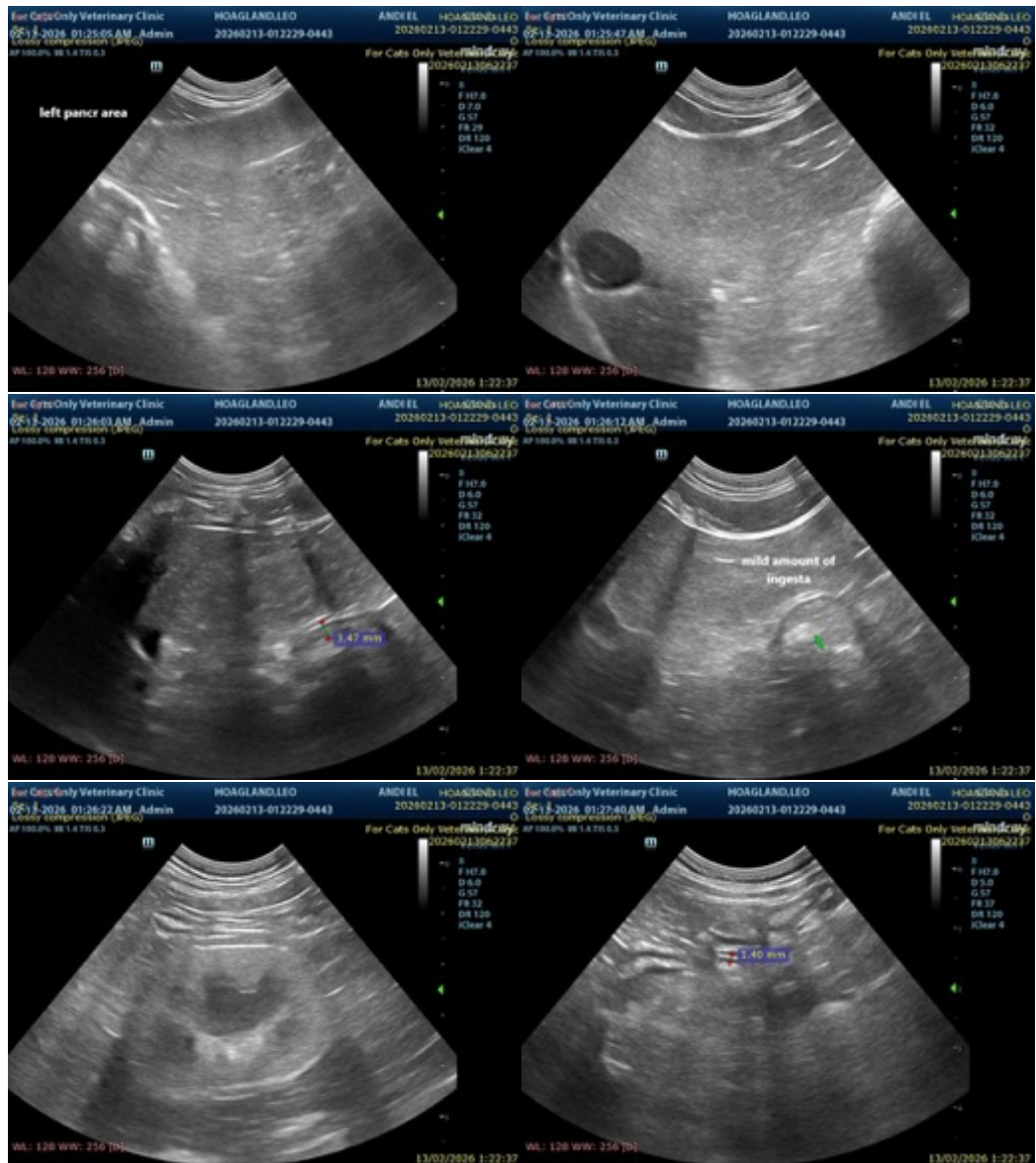
Dr. Pamela Bay

**INVOICE**

11318

**DATE**

2/13/2026



The information and recommendations provided are based on the images presented by the referring veterinarian/sonographer. No evaluation can be communicated regarding pathology that was not visible in the image/video clips provided.

Thank you for this referral. If the clinical or image interpretation does not parallel your findings or if I can be of any further assistance please contact me.

Alicia Angosto Guerrero, DMV, PgDip, MSc.

[info@SonoPath.com](mailto:info@SonoPath.com)