



PATIENT

Roka McKinney

SPECIES

Canine

BREED

Labrador Retriever Mix

SEX

Spayed female

AGE

6 years

WEIGHT

44.5 lbs

INTERPRETED BY

Dr. Alicia Angosto
Guerrero

IMAGING PERFORMED BY

Brandon

HOSPITAL NAME

Dillsburg VC

REFERRING VET

Dr. Pryor

INVOICE

71469

DATE

2/10/26

PRESENTING CLINICAL SIGNS

- Intermittent vomiting. stomach wall appeared thickened on abdominal radiographs.
- ALT 132, K 3.8, rest of cbc/chem WNL

ULTRASONOGRAPHIC EXAMINATION OF THE ABDOMEN

Urinary System

The urinary bladder lumen is normally distended. The urinary bladder wall is thin and smooth. Urine is anechoic. The bladder neck and proximal urethra have a normal ultrasonographic appearance. No uroliths are identified.

Left kidney: Normal in shape and size, measuring 6.45×3.54 cm in the sagittal plane. Cortical thickness measures 0.59 cm. The renal cortex is isoechoic relative to the liver parenchyma. Corticomedullary ratio and corticomedullary definition are preserved. No pyelectasia, nephrolithiasis, or hydronephrosis.

Right kidney: Normal in shape and size, measuring 6.50×3.40 cm in the sagittal plane. Cortical thickness measures 0.53 cm. The renal cortex is isoechoic relative to the liver parenchyma. Corticomedullary ratio and corticomedullary definition are preserved. No pyelectasia, nephrolithiasis, or hydronephrosis.

Adrenal Glands

The left adrenal gland was not consistently visualized in the available video clips. Static images suggest measurements of approximately 0.39 cm and 0.37 cm; however, these may be slightly underestimated due to incomplete visualization.

The right adrenal gland measures 0.71 cm at the cranial pole and 0.57 cm at the caudal pole (0.76 cm and 0.59 cm at the static images).

Spleen

Splenic thickness measures 2.26 cm. The splenic parenchyma demonstrates normal echogenicity and homogeneous echotexture without focal abnormalities.

Liver

The liver is subjectively normal in size, with sharp margins and regular contour.

Within the region of the left hepatic lobes, a focal, roughly rounded region measuring 3.20×3.13 cm is identified. This area is mildly hypoechoic relative to the adjacent hepatic parenchyma. Internal architecture appears similar to surrounding tissue, without evidence of capsular distortion or clear mass effect. No additional focal hepatic lesions are identified.

The gallbladder is normally distended. The wall is thin. Contents are anechoic. No dilation of the cystic duct or common bile duct is identified.



PATIENT

Roka McKinney

SPECIES

Canine

BREED

Labrador Retriever Mix

SEX

Spayed female

AGE

6 years

WEIGHT

44.5 lbs

INTERPRETED BY

Dr. Alicia Angosto
Guerrero

IMAGING PERFORMED BY

Brandon

HOSPITAL NAME

Dillsburg VC

REFERRING VET

Dr. Pryor

INVOICE

71469

DATE

2/10/26

Gastrointestinal

The stomach is empty and folded. Gastric wall thickness measures 4.47 mm with preserved layering.

The pylorus measures between 5.93–6.94 mm. The duodenum measures 3.52 mm. The jejunum measures 3.06 mm. The ileum measures 2.12 mm. Wall layering is preserved throughout. No obstruction, focal mass, or foreign material is identified.

The colon measures 0.74 mm in thickness and contains formed feces within the descending segment.

Pancreas

The evaluated pancreatic regions do not show ultrasonographic evidence of inflammation or mass effect.

Peritoneal Cavity

No abdominal effusion is observed.

A right gastric lymph node measuring 7.64×9.44 mm is identified and demonstrates normal shape and echogenicity.

The iliac trifurcation is normal.

ULTRASONOGRAPHIC FINDINGS

- Solitary focal hypoechoic hepatic region.
- Gastric and pyloric wall thickness at the upper end of normal.

INTERPRETATION OF THE FINDINGS & FURTHER RECOMMENDATIONS

This examination identifies a solitary, mildly hypoechoic focal hepatic region measuring 3.20×3.13 cm, without capsular distortion or overt mass effect. The lesion's preserved internal architecture and lack of distortion suggest that this may represent: Nodular hyperplasia, focal hepatocellular change (vacuolar change), regenerative nodule, or early neoplasia (less likely but cannot be excluded). The absence of additional lesions, normal regional lymph nodes, and lack of vascular invasion reduce suspicion for aggressive metastatic or primary hepatic malignancy; however, ultrasound cannot definitively differentiate benign nodular hyperplasia from neoplasia. ALT elevation is mild and may or may not be related to this focal hepatic finding.

The gastrointestinal tract does not demonstrate obstructive disease or focal mass to explain the history of intermittent vomiting. Gastric wall thickness is at the upper end of normal limits. The pyloric wall thickness is also at the upper end of normal; however, wall layering is preserved and no focal mass effect is identified. A right gastric lymph node is visualized and measured within normal limits for size and echogenicity. These findings may reflect mild gastropathy. Early or low-grade inflammatory conditions



PATIENT

Roka McKinney

SPECIES

Canine

BREED

Labrador Retriever Mix

SEX

Spayed female

AGE

6 years

WEIGHT

44.5 lbs

INTERPRETED BY

Dr. Alicia Angosto
Guerrero

IMAGING PERFORMED BY

Brandon

HOSPITAL NAME

Dillsburg VC

REFERRING VET

Dr. Pryor

INVOICE

71469

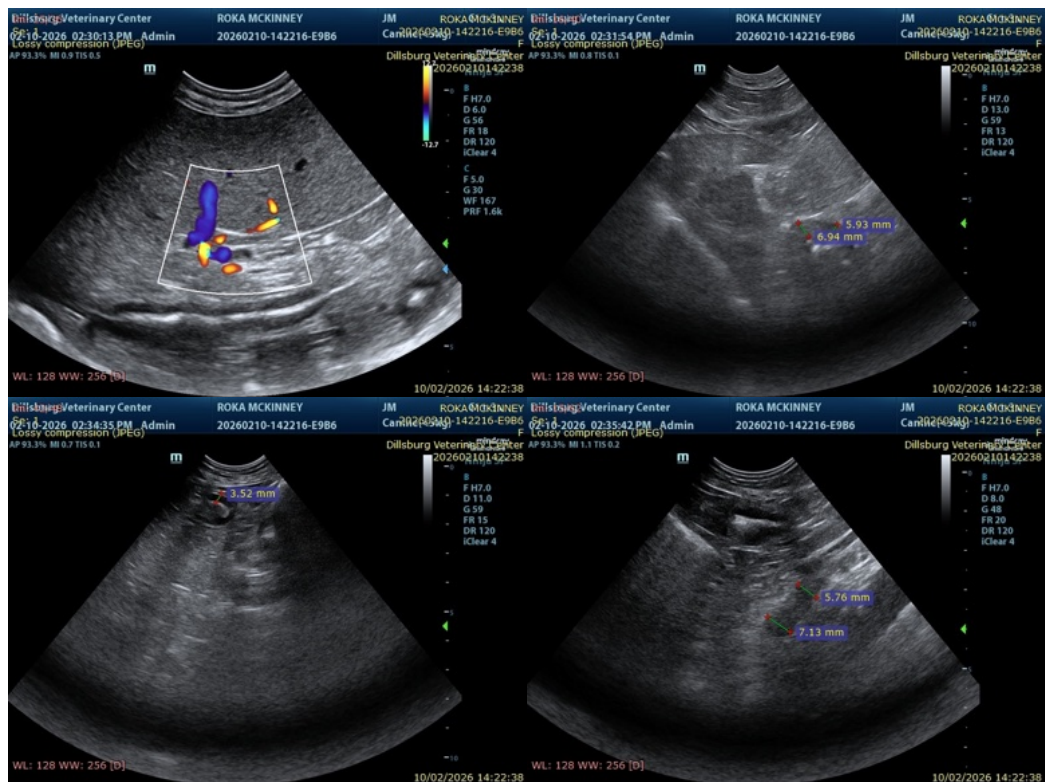
DATE

2/10/26

(chronic gastritis, lymphocytic gastritis) cannot be excluded based on ultrasound alone, as mucosal inflammatory changes may occur without overt structural alteration.

Recommendations

- Consider ultrasound-guided fine-needle aspiration of the focal hepatic lesion for cytologic evaluation to further characterize its nature.
- Alternatively, if sampling is deferred, recommend follow-up abdominal ultrasound in 6–8 weeks to assess for interval change in size, echogenicity, or definition.
- Continue to monitor liver enzyme activity (particularly ALT) to evaluate for biochemical progression.
- Empirical gastric therapy.
- If vomiting persists despite medical management, progression to upper gastrointestinal endoscopy with mucosal biopsies should be considered to evaluate for chronic gastritis or other mucosal inflammatory disease not detectable on ultrasound.





PATIENT

Roka McKinney

SPECIES

Canine

BREED

Labrador Retriever Mix

SEX

Spayed female

AGE

6 years

WEIGHT

44.5 lbs

INTERPRETED BY

Dr. Alicia Angosto
Guerrero

IMAGING PERFORMED BY

Brandon

HOSPITAL NAME

Dillsburg VC

REFERRING VET

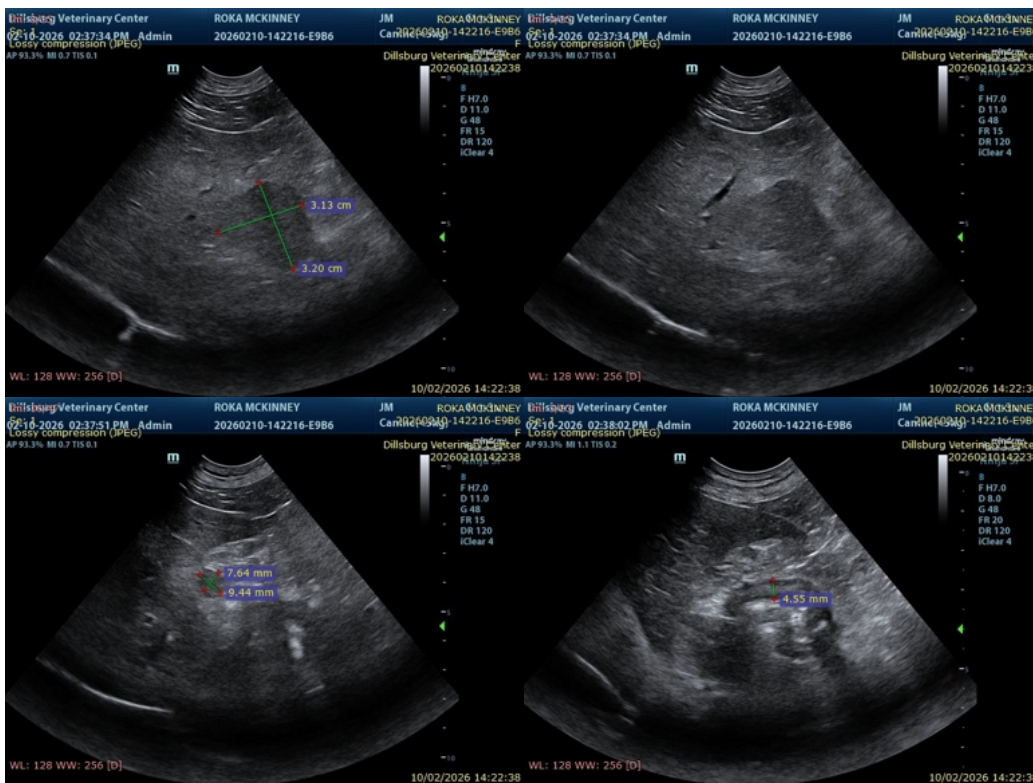
Dr. Pryor

INVOICE

71469

DATE

2/10/26



The information and recommendations provided are based on the images presented by the referring veterinarian/sonographer. No evaluation can be communicated regarding pathology that was not visible in the image/video clips provided.

Thank you for this referral. If the clinical or image interpretation does not parallel your findings or if I can be of any further assistance please contact me.

Alicia Angosto Guerrero, DMV, PgDip, MSc.

MV Esp Ultrasound in Domestic and Wild Animals

info@SonoPath.com