

## PATIENT

Molly Demarco

## SPECIES

Canine

## BREED

Boxer

## SEX

Spayed female

## AGE

9 years

## WEIGHT

80 lbs

## INTERPRETED BY

Dr. Alicia Angosto  
Guerrero

## IMAGING PERFORMED BY

Brandon

## HOSPITAL NAME

Dillsburg VC

## REFERRING VET

Dr. Pryor

## INVOICE

71449

## DATE

2/10/26

## PRESENTING CLINICAL SIGNS

- Pre-op ECG for dental cleaning showed ventricular arrhythmia (isolated VPC's) and a short pause caused by sinus arrest or second degree AV block. Rule out non-cardiac causes such as splenic disease, pancreatitis, hepatic disease and GI disease.
- CBC/chem WNL and Accuplex negx4

## ULTRASONOGRAPHIC EXAMINATION OF THE ABDOMEN

### *Urinary System*

The urinary bladder lumen is normally distended. The urinary bladder wall is thin and smooth. Urine is anechoic. The bladder neck and proximal urethra have a normal ultrasonographic appearance. No uroliths are identified. There is no ultrasonographic evidence of inflammatory or neoplastic changes.

Left kidney: Normal in shape and size, measuring 5.00×3.84 cm in the sagittal plane. Cortical thickness measures 0.68 cm. The renal cortex is isoechoic relative to the liver parenchyma. Corticomedullary ratio and corticomedullary definition are preserved. No evidence of pyelectasia, nephrolithiasis, or hydronephrosis. Doppler evaluation shows normal perfusion.

Right kidney: Normal in shape and size, measuring 6.43×3.92 cm in the sagittal plane. Cortical thickness measures 0.65 cm. The renal cortex is isoechoic relative to the liver parenchyma. Corticomedullary ratio and corticomedullary definition are preserved. No evidence of pyelectasia, nephrolithiasis, or hydronephrosis. Doppler evaluation shows normal perfusion.

### *Adrenal Glands*

Both adrenal glands demonstrate normal shape and echogenicity. Left adrenal gland: 0.53 cm (cranial pole), 0.57 cm (caudal pole). Right adrenal gland: 0.51 cm (cranial pole), 0.58 cm (caudal pole).

### *Spleen*

Splenic thickness measures 1.91 cm. The splenic parenchyma demonstrates normal echogenicity and fine homogeneous echotexture without focal abnormalities. The splenic capsule is smooth and regular. Splenic vasculature appears normal.

### *Liver*

The liver is subjectively normal in size, with sharp margins and a regular contour. The hepatic parenchyma is homogeneous and isoechoic relative to the falciform fat, with normal echotexture. No focal hepatic lesions or hepatic lymphadenopathy are identified.

The gallbladder lumen is normally distended. The wall is thin. The contents are predominantly anechoic. No dilation of the cystic duct or common bile duct is identified.



## PATIENT

Molly Demarco

## SPECIES

Canine

## BREED

Boxer

## SEX

Spayed female

## AGE

9 years

## WEIGHT

80 lbs

## INTERPRETED BY

Dr. Alicia Angosto  
Guerrero

## IMAGING PERFORMED BY

Brandon

## HOSPITAL NAME

Dillsburg VC

## REFERRING VET

Dr. Pryor

## INVOICE

71449

## DATE

2/10/26

## ***Gastrointestinal***

The stomach is mildly distended and contains small amounts of ingesta. Gastric wall thickness measures 2.81 mm with preserved layering.

The duodenum measures 3.03 mm. The jejunum measures 0.41 cm (4.1 mm), with preserved wall layering. No ultrasonographic evidence of inflammation, ileus, obstruction, or mass lesions is identified.

The colon measures 0.81 mm in wall thickness and contains formed feces within the descending segment.

## ***Pancreas***

The evaluated pancreatic regions do not show ultrasonographic evidence of inflammation, mass effect, or peripancreatic fat changes.

## ***Peritoneal Cavity***

No abdominal effusion or signs of peritonitis are observed. No abdominal lymphadenopathy is identified. The iliac trifurcation appears normal.

## **ULTRASONOGRAPHIC FINDINGS**

No clinically significant abdominal abnormalities identified.

## **INTERPRETATION OF THE FINDINGS & FURTHER RECOMMENDATIONS**

This abdominal ultrasound examination is unremarkable. No evidence of splenic mass, splenic torsion, splenic nodular disease, pancreatitis, hepatobiliary disease, gastrointestinal pathology, or abdominal effusion is identified. There are no ultrasonographic abnormalities that would reasonably account for ventricular arrhythmias.

In the context of normal biochemical testing and the absence of abdominal pathology, the detected ventricular arrhythmia is unlikely to be secondary to abdominal disease. Given the signalment (Boxer) and the nature of the arrhythmia, a primary cardiac etiology—such as arrhythmogenic right ventricular cardiomyopathy (ARVC)—remains a leading differential consideration.

### Recommendations

- No abdominal cause for the ventricular arrhythmia is identified on this examination.
- Cardiology consultation is recommended for further evaluation of ventricular arrhythmia, including consideration of 24-hour Holter monitoring and echocardiography.



**PATIENT**

Molly Demarco

**SPECIES**

Canine

**BREED**

Boxer

**SEX**

Spayed female

**AGE**

9 years

**WEIGHT**

80 lbs

**INTERPRETED BY**

Dr. Alicia Angosto  
Guerrero

**IMAGING  
PERFORMED BY**

Brandon

**HOSPITAL NAME**

Dillsburg VC

**REFERRING VET**

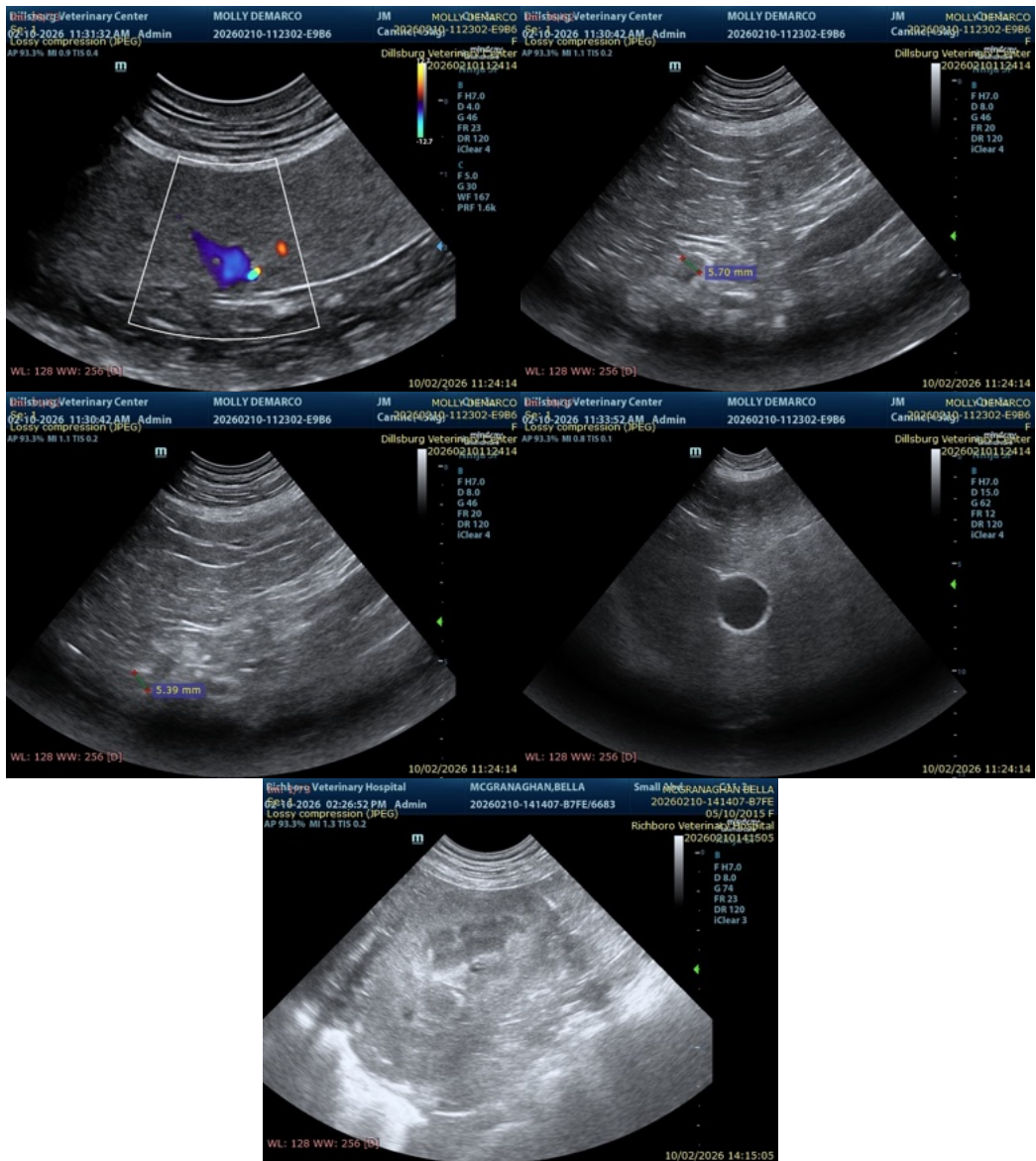
Dr. Pryor

**INVOICE**

71449

**DATE**

2/10/26



The information and recommendations provided are based on the images presented by the referring veterinarian/sonographer. No evaluation can be communicated regarding pathology that was not visible in the image/video clips provided.

Thank you for this referral. If the clinical or image interpretation does not parallel your findings or if I can be of any further assistance please contact me.

Alicia Angosto Guerrero, DMV, PgDip, MSc.

MV Esp Ultrasound in Domestic and Wild Animals

[info@SonoPath.com](mailto:info@SonoPath.com)