



## PATIENT

Henry Akard

## SPECIES

Canine

## BREED

Welsh Terrier

## SEX

Neutered male

## AGE

9 years

## WEIGHT

24.3 lbs

## INTERPRETED BY

Dr. Alicia Angosto  
Guerrero

## IMAGING PERFORMED BY

Dr. Cassidy Stranzl

## HOSPITAL NAME

Dakota VC

## REFERRING VET

Dr. Stranzl

## INVOICE

69458

## DATE

12/9/25

## PRESENTING CLINICAL SIGNS

History: Elevated SDMA, USG 1.018, patient is urinating and drinking more, patient is on Proin for urinary incontinence.

## ULTRASONOGRAPHIC EXAMINATION OF THE ABDOMEN

### *Urinary System*

The bladder lumen is very distended, and the wall of the urinary bladder appears thin and smooth. The urine is anechoic. Normal appearance of the proximal urethra and vesicoureteral junction. There are no calculi and no evidence of inflammatory or neoplastic changes.

The left kidney is normal in shape and size: 4.39×2.71 cm, and the thickness of the cortex is 0.42 cm in the sagittal plane. The right kidney is normal in shape and size: 4.15×2.54 cm, and the thickness of the cortex is cm in the sagittal plane. Both kidneys show renal cortices that are slightly increased in echogenicity compared to the liver parenchyma. The corticomedullary ratio is normal and the corticomedullary definition is preserved. There is no evidence of pyelectasia, nephroliths, or hydronephrosis. Color Doppler shows a normal pattern.

### *Adrenal Glands*

Both adrenal glands show normal shape and echogenicity. The left adrenal gland measures 0.56 cm at the cranial pole and 0.58 cm at the caudal pole (maximum values from three measurements). The right adrenal gland measures 0.51 cm at the cranial pole and 0.47 cm at the caudal pole.

### *Spleen*

Splenic thickness is 1.81 cm. The parenchyma demonstrates normal echogenicity and a fine homogeneous echotexture without focal parenchymal abnormalities. The splenic capsule is smooth and regular.

### *Liver*

The liver is subjectively normal in size, with sharp edges and a regular contour. The liver parenchyma looks uniform and is isoechoic compared to the falciform fat, with a normal echotexture. No hepatic lymphadenopathy is observed.

The gallbladder lumen is normally distended. The wall is thin and the contents are primarily anechoic. No evident dilation of the cystic duct or common bile duct is observed.

### *Gastrointestinal*



## PATIENT

Henry Akard

The stomach is mildly distended with food material, with mural thickness of 3.23 mm and preserved wall layering. The duodenal wall measures 3.04 mm and appears to have a slight hyperechoic mucosal striation pattern.

## SPECIES

Canine

Jejunum: 2.87–3.14 mm, with normal wall layering.

Colon: 0.85 mm, with small amounts of formed feces in the descending segment.

## BREED

Welsh Terrier

### **Pancreas**

The areas examined do not show clear signs of inflammation.

## SEX

Neutered male

### **Peritoneal Cavity**

No abdominal effusion or peritonitis is observed. The cranial mesenteric lymph nodes are not visualized, but surrounding regions appear unremarkable. The iliac trifurcation is normal.

## AGE

9 years

## WEIGHT

24.3 lbs

## ULTRASONOGRAPHIC FINDINGS

### PRIMARY FINDINGS

- Mild, diffuse increase in renal cortical echogenicity.

### SECONDARY FINDINGS

- Mild duodenal mucosal hyperechoic striations.

## INTERPRETED BY

Dr. Alicia Angosto  
Guerrero

## INTERPRETATION OF THE FINDINGS & FURTHER RECOMMENDATIONS

Both kidneys are normal in size and shape, with preserved corticomedullary definition and no evidence of pyelectasia, calculi, or hydronephrosis. The only renal abnormality is a mild, diffuse increase in cortical echogenicity, which is a nonspecific but common ultrasonographic feature of early CKD, tubular/interstitial change, or age-related fibrosis. There is no ultrasonographic evidence of acute kidney injury, chronic end-stage changes, or post-renal obstruction.

Overall, the imaging findings do not reveal a structural cause for the patient's PU/PD but instead support early renal dysfunction as the most likely explanation, consistent with the elevated SDMA and poorly concentrated urine. Other metabolic or endocrine causes of PU/PD are not ruled out by ultrasound and should be considered if renal disease does not fully explain the clinical picture.

### Recommendations

- Correlate renal findings with serial laboratory monitoring.
- Consider blood pressure measurement and evaluation for proteinuria (UPC).
- Mild duodenal mucosal hyperechoic striations are nonspecific and may reflect transient irritation; no specific imaging follow-up is required unless clinical signs persist.

## IMAGING PERFORMED BY

Dr. Cassidy Stranzl

## HOSPITAL NAME

Dakota VC

## REFERRING VET

Dr. Stranzl

## INVOICE

69458

## DATE

12/9/25



**PATIENT**

Henry Akard

**SPECIES**

Canine

**BREED**

Welsh Terrier

**SEX**

Neutered male

**AGE**

9 years

**WEIGHT**

24.3 lbs

**INTERPRETED BY**

Dr. Alicia Angosto Guerrero

**IMAGING PERFORMED BY**

Dr. Cassidy Stranzl

**HOSPITAL NAME**

Dakota VC

**REFERRING VET**

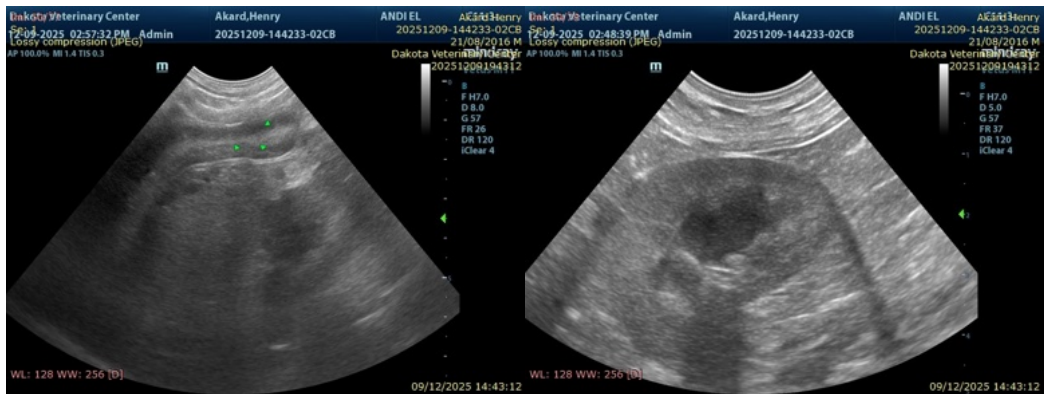
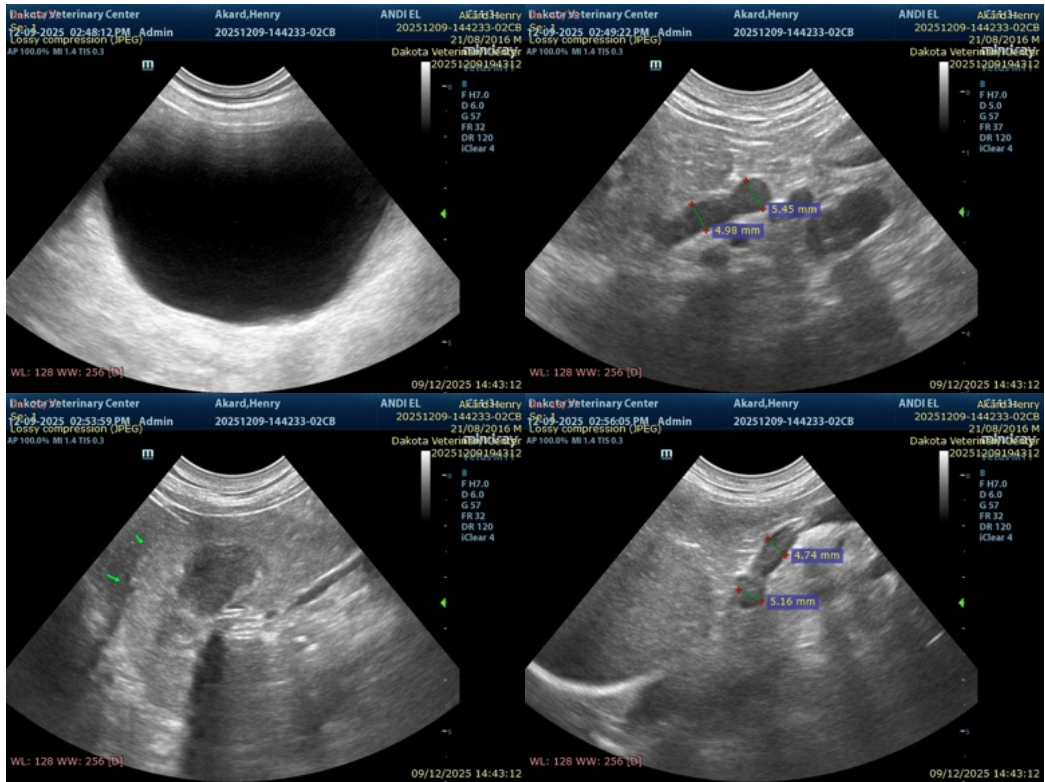
Dr. Stranzl

**INVOICE**

69458

**DATE**

12/9/25



The information and recommendations provided are based on the images presented by the referring veterinarian/sonographer. No evaluation can be communicated regarding pathology that was not visible in the image/video clips provided.

Thank you for this referral. If the clinical or image interpretation does not parallel your findings or if I can be of any further assistance please contact me.

Alicia Angosto Guerrero, DMV, PgDip, MSc.

MV Esp Ultrasound in Domestic and Wild Animals



**PATIENT**

[info@SonoPath.com](mailto:info@SonoPath.com)

Henry Akard

**SPECIES**

Canine

**BREED**

Welsh Terrier

**SEX**

Neutered male

**AGE**

9 years

**WEIGHT**

24.3 lbs

**INTERPRETED BY**

Dr. Alicia Angosto  
Guerrero

**IMAGING  
PERFORMED BY**

Dr. Cassidy Stranzl

**HOSPITAL NAME**

Dakota VC

**REFERRING VET**

Dr. Stranzl

**INVOICE**

69458

**DATE**

12/9/25