



## PATIENT

Teddy O'Connor

## SPECIES

Canine

## BREED

Havanese

## SEX

Neutered male

## AGE

9 years

## WEIGHT

20 lbs

## INTERPRETED BY

Dr. Alicia Angosto  
Guerrero

## IMAGING PERFORMED BY

Dr. Scott

## HOSPITAL NAME

Wyckoff VH

## REFERRING VET

Dr. Scott

## INVOICE

69698

## DATE

12/30/25

## PRESENTING CLINICAL SIGNS

History: Recent lymphoma diagnosis- peripheral lymph nodes  
CBC/chem WNL severe erythematous lesion on inguinal region

## ULTRASONOGRAPHIC EXAMINATION OF THE ABDOMEN

### Urinary System

The urinary bladder is normally distended. The bladder wall is thin and smooth. The urine is predominantly anechoic with scant suspended echogenic material. The bladder neck and proximal urethra appear normal. No uroliths are identified, and there is no ultrasonographic evidence of inflammatory or neoplastic disease.

The left kidney is normal in shape and size, measuring 4.58×2.65 cm, with a cortical thickness of 0.51 cm in the sagittal plane. The renal cortex is isoechoic relative to the liver parenchyma. The corticomedullary ratio is normal, and corticomedullary definition is preserved. There is no evidence of pyelectasia, nephrolithiasis, or hydronephrosis.

The right kidney is normal in shape and size, measuring 4.86×2.78 cm, with a cortical thickness of 0.55 cm in the sagittal plane. The renal cortex is isoechoic relative to the liver parenchyma. The corticomedullary ratio is normal, and corticomedullary definition is preserved. There is no evidence of pyelectasia, nephrolithiasis, or hydronephrosis.

The prostate measures 1.33 × 1.06 cm and is homogeneous and hypoechoic, compatible with prostatic atrophy secondary to prior orchiectomy.

### Adrenal Glands

Both adrenal glands have normal shape and echogenicity. The left adrenal gland measures 0.47 cm at the cranial pole and 0.48 cm at the caudal pole. The right adrenal gland measures 0.49 cm at the cranial pole and 0.45 cm at the caudal pole.

### Spleen

Splenic thickness measures 0.86 cm. The splenic parenchyma has normal echogenicity and a fine, homogeneous echotexture without focal parenchymal abnormalities. The splenic capsule is smooth and regular.

### Liver

The liver is subjectively increased in size, with a regular contour. The hepatic parenchyma is uniform and isoechoic relative to the falciform fat, with a normal echotexture. No hepatic lymphadenopathy is observed.



## PATIENT

Teddy O'Connor

The gallbladder lumen is moderately to markedly distended. The gallbladder wall is thin, and the contents are primarily anechoic with a moderate amount of biliary sludge. No dilation of the cystic duct or common bile duct is observed.

## SPECIES

Canine

### *Gastrointestinal*

## BREED

Havanese

The stomach is semi-empty and folded, with a small amount of ingesta present. Gastric wall thickness measures 1.66 mm, with preserved wall layering. The pyloric wall measures 3.70 mm. The duodenum measures 2.71 mm. The jejunum measures between 2.44 and 3.09 mm. The colonic wall measures 0.81 mm, with formed fecal material present in the descending colon.

## SEX

Neutered male

### *Pancreas*

## AGE

9 years

The pancreatic parenchyma is isoechoic relative to the adjacent omental fat. No ultrasonographic evidence of active pancreatitis is identified.

## WEIGHT

20 lbs

### *Peritoneal Cavity*

No abdominal effusion or evidence of peritonitis is observed. The cranial mesenteric lymph node measures 1.8×1.03 cm. The portal lymph node measures 0.96×0.98 cm. The aortic (sublumbar) lymph nodes measure 1.69×1.04 cm. The medial iliac lymph nodes measure approximately 0.7–0.9 cm. These lymph nodes are rounded and hypoechoic.

## INTERPRETED BY

Dr. Alicia Angosto  
Guerrero

## ULTRASONOGRAPHIC FINDINGS

### IMAGING PERFORMED BY

Dr. Scott

#### PRIMARY FINDINGS

- Multifocal abdominal lymphadenomegaly (cranial mesenteric, portal, sublumbar, and medial iliac lymph nodes), rounded and hypoechoic.

### HOSPITAL NAME

Wyckoff VH

#### SECONDARY FINDINGS

- Subjective hepatomegaly without focal parenchymal abnormalities.
- Moderate biliary sludge within a distended gallbladder.

### REFERRING VET

Dr. Scott

## INVOICE

69698

## DATE

12/30/25

## INTERPRETATION OF THE FINDINGS & FURTHER RECOMMENDATIONS

Abdominal ultrasonography reveals multifocal abdominal lymphadenomegaly, characterized by enlarged, rounded, hypoechoic cranial mesenteric, portal, sublumbar (aortic), and medial iliac lymph nodes. This lymph node distribution and morphology are highly consistent with abdominal involvement by multicentric lymphoma, representing systemic disease rather than reactive lymphadenopathy, particularly in the context of a confirmed lymphoma diagnosis.



## PATIENT

Teddy O'Connor

## SPECIES

Canine

## BREED

Havanese

## SEX

Neutered male

## AGE

9 years

## WEIGHT

20 lbs

## INTERPRETED BY

Dr. Alicia Angosto  
Guerrero

## IMAGING PERFORMED BY

Dr. Scott

## HOSPITAL NAME

Wyckoff VH

## REFERRING VET

Dr. Scott

## INVOICE

69698

## DATE

12/30/25

The liver is subjectively enlarged but maintains normal echogenicity and echotexture, with no focal lesions or hepatic lymphadenopathy identified. Hepatomegaly in this setting may be reactive, related to systemic disease, steroid exposure (if applicable), or early infiltrative change below the sensitivity of ultrasound. Ultrasound cannot reliably exclude diffuse hepatic lymphomatous infiltration in the absence of focal changes.

The gallbladder contains a moderate amount of biliary sludge without ductal dilation, most consistent with benign biliary stasis.

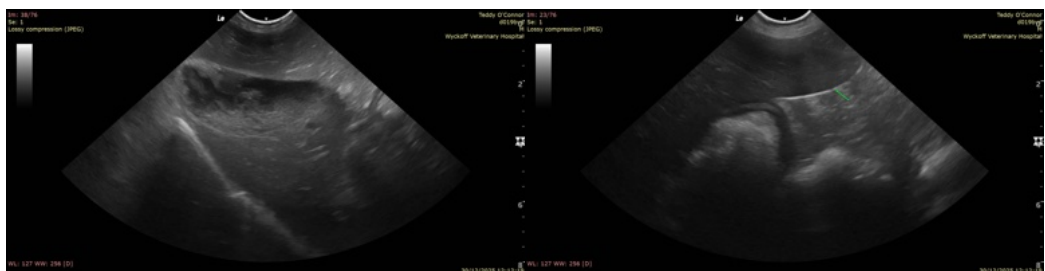
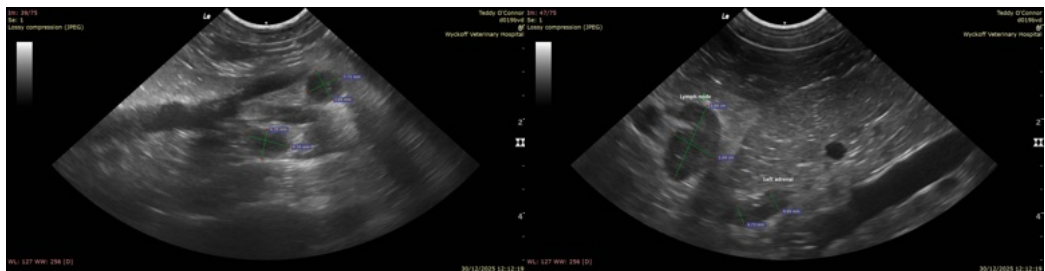
Prostatic atrophy is an expected finding in a neutered male dog.

Overall, the primary ultrasonographic abnormality is abdominal lymph node involvement, consistent with systemic lymphoma in the setting of disease relapse following a prior remission.

### Recommendations

- Complete oncologic staging: consider integration with cytology/histopathology of peripheral nodes and thoracic imaging to define disease stage accurately.
- Baseline and follow-up monitoring: Monitor liver enzymes and bilirubin over time, particularly if chemotherapy or corticosteroids are initiated, given hepatomegaly and biliary sludge.

This interpretation should be correlated with clinical progression and oncologic management decisions, recognizing the limitations of ultrasound in detecting diffuse or early infiltrative disease.





## PATIENT

Teddy O'Connor

## SPECIES

Canine

## BREED

Havanese

## SEX

Neutered male

## AGE

9 years

## WEIGHT

20 lbs

## INTERPRETED BY

Dr. Alicia Angosto  
Guerrero

## IMAGING PERFORMED BY

Dr. Scott

## HOSPITAL NAME

Wyckoff VH

## REFERRING VET

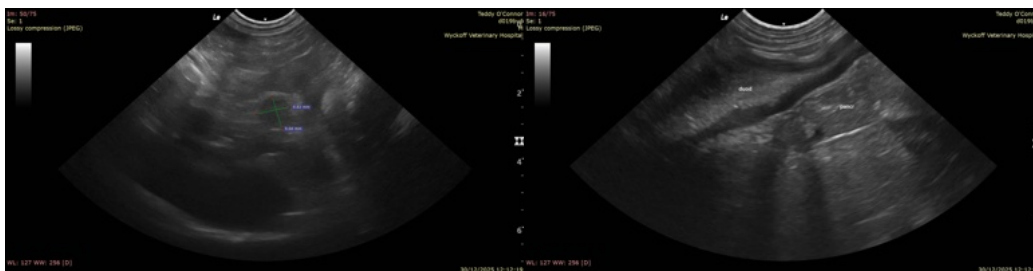
Dr. Scott

## INVOICE

69698

## DATE

12/30/25



The information and recommendations provided are based on the images presented by the referring veterinarian/sonographer. No evaluation can be communicated regarding pathology that was not visible in the image/video clips provided.

Thank you for this referral. If the clinical or image interpretation does not parallel your findings or if I can be of any further assistance please contact me.

Alicia Angosto Guerrero, DMV, PgDip, MSc.

MV Esp Ultrasound in Domestic and Wild Animals

[info@SonoPath.com](mailto:info@SonoPath.com)