



PATIENT

Edison Asher

SPECIES

Feline

BREED

American Shorthair

SEX

Neutered male

AGE

14 years

WEIGHT

8.5 lbs

INTERPRETED BY

Dr. Alicia Angosto
Guerrero

IMAGING PERFORMED BY

Emma Flott

HOSPITAL NAME

Portland Veterinary
Wellness Center

REFERRING VET

Dr. Mary-Ann Onuta

INVOICE

69726

DATE

12/30/25

PRESENTING CLINICAL SIGNS

History: Weight loss over last 4-5 months. Recent BW showed elevated WBC. AUS for normal senior screen and to further workup elevated WBC. Recent chemistry was wnl. T4 wnl. Patient has hx of chronic keratitis
Abnormal PE/Chem/CBC/UA Results: CBC - leukocytosis (23,000), neutrophilia (19,000), monocytosis, thrombocytopenia (91,000) UA - isosthenuria, USG 1.019

ULTRASONOGRAPHIC EXAMINATION OF THE ABDOMEN

Urinary System

The urinary bladder is normally distended. The bladder wall is thin and smooth. The urine is anechoic. The bladder neck and proximal urethra appear normal. No uroliths are identified, and there is no ultrasonographic evidence of inflammatory or neoplastic disease.

The left kidney is normal in shape and size, measuring 4.31×2.27 cm, with a cortical thickness of 0.34 cm in the sagittal plane. The right kidney is normal in shape and size, measuring 4.49×2.08 cm, with a cortical thickness of 0.32 cm in the sagittal plane. In both kidneys, the renal cortex is mildly increased in echogenicity, resulting in increased corticomedullary distinction. The corticomedullary ratio is normal, and corticomedullary definition is preserved. There is no evidence of pyelectasia, nephrolithiasis, or hydronephrosis. Color Doppler evaluation demonstrates a normal vascular pattern.

Adrenal Glands

Both adrenal glands have normal shape and echogenicity. The left adrenal gland measures 0.37 cm at the cranial pole and 0.38 cm at the caudal pole. The right adrenal gland measures 0.34 cm at the cranial pole and 0.37 cm at the caudal pole.

Spleen

Splenic thickness measures 0.88 cm. The splenic parenchyma has normal echogenicity and a fine, homogeneous echotexture without focal parenchymal abnormalities. The splenic capsule is smooth and regular.

Liver

The liver is subjectively normal in size, with sharp margins and a regular contour. The hepatic parenchyma is uniform and isoechoic relative to the falciform fat, with a normal echotexture. No hepatic lymphadenopathy is observed.

The gallbladder lumen is normally distended. The gallbladder wall is thin, and the contents are primarily anechoic. The cystic duct measures 4.26 mm, and the common bile duct measures approximately 2.20–2.30 mm.



PATIENT

Edison Asher

SPECIES

Feline

BREED

American Shorthair

SEX

Neutered male

AGE

14 years

WEIGHT

8.5 lbs

INTERPRETED BY

Dr. Alicia Angosto
Guerrero

IMAGING PERFORMED BY

Emma Flott

HOSPITAL NAME

Portland Veterinary
Wellness Center

REFERRING VET

Dr. Mary-Ann Onuta

INVOICE

69726

DATE

12/30/25

Gastrointestinal

The stomach is empty and mildly folded, with a mural thickness of 1.94 mm and preserved wall layering. The pyloric wall measures 3.67 mm. The duodenum measures 2.28 mm. The jejunum measures 2.59 mm, with the following wall layer measurements: mucosa 1.24 mm, submucosa 0.68 mm, and muscularis propria 0.51 mm. The ileum measures 3.37 mm, with mucosa 0.86 mm, submucosa 0.70 mm, and muscularis propria 1.85 mm; wall layering is preserved.

One intestinal segment demonstrates marked focal wall thickening up to 1.07 cm, with complete loss of normal wall layering. The affected segment extends for more than 5 cm in length; however, exact length cannot be accurately measured, as it does not fully fit within the imaging field. The precise intestinal segment cannot be definitively identified due to lack of clear continuity on the recorded clips, but involvement of the transverse colon or ileum is suspected.

The ileocecal junction measures 3.51 mm, with a muscularis thickness of 1.34 mm. No evidence of gastrointestinal obstruction, ileus, or foreign material is identified. The colonic wall measures 0.79 mm, with formed fecal material present in the descending colon.

Pancreas

The pancreas measures approximately 5.30–6.16 mm in thickness, with regular margins. The pancreatic parenchyma is hypoechoic relative to the adjacent omental fat. The pancreatic duct measures 1.49 mm in diameter. No ultrasonographic evidence of active inflammation or neoplastic disease is identified.

Peritoneal Cavity

No abdominal effusion or evidence of peritonitis is observed. The cranial mesenteric and ileocecal lymph nodes are not visualized. The iliac trifurcation appears normal.

ULTRASONOGRAPHIC FINDINGS

PRIMARY FINDINGS

- Severe focal intestinal wall thickening (up to 1.07 cm) with complete loss of wall layering, extending over >5 cm, suspected ileal or transverse colonic involvement.
- Diffuse ileal wall thickening with marked muscularis hypertrophy, with preserved wall layering

SECONDARY FINDINGS

- Mild bilateral renal cortical hyperechogenicity with preserved corticomedullary definition.



PATIENT

Edison Asher

SPECIES

Feline

BREED

American Shorthair

SEX

Neutered male

AGE

14 years

WEIGHT

8.5 lbs

INTERPRETED BY

Dr. Alicia Angosto
Guerrero

IMAGING PERFORMED BY

Emma Flott

HOSPITAL NAME

Portland Veterinary
Wellness Center

REFERRING VET

Dr. Mary-Ann Onuta

INVOICE

69726

DATE

12/30/25

INTERPRETATION OF THE FINDINGS & FURTHER RECOMMENDATIONS

Abdominal ultrasonography identifies a focal, severe intestinal wall lesion characterized by marked segmental thickening (>1 cm) with complete loss of wall layering, extending over a length greater than 5 cm. This ultrasonographic appearance is highly concerning for an infiltrative or neoplastic intestinal process, most notably intestinal lymphoma or adenocarcinoma.

The absence of regional lymphadenopathy does not exclude intestinal neoplasia, as nodal involvement may be minimal or not sonographically apparent, particularly in cats. Likewise, lack of obstruction does not diminish concern, as feline intestinal lymphoma commonly presents without mechanical obstruction.

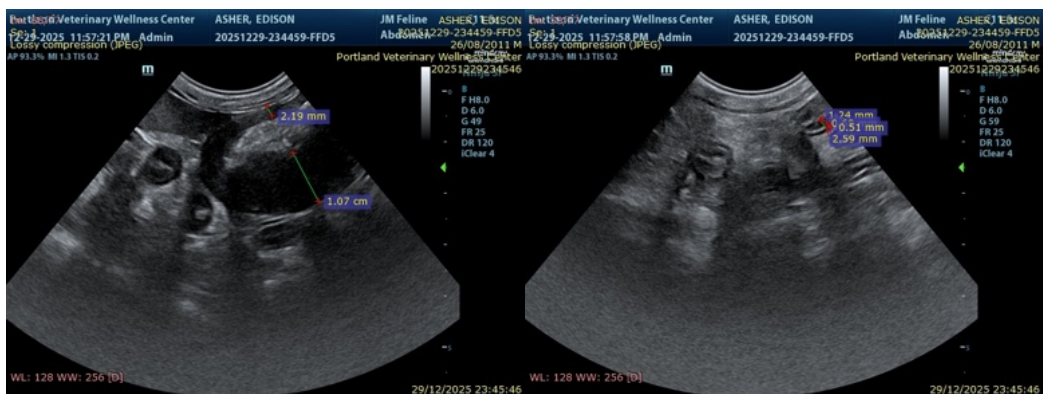At the level of the ileum, the intestinal wall is diffusely thickened with clear hypertrophy of the muscularis propria. The muscularis measures approximately 1.85 mm, while the mucosa measures approximately 0.86 mm, resulting in a muscularis-to-mucosa ratio of approximately 2.1:1. Wall layering remains preserved in this segment. In cats, marked muscularis thickening with preserved layering and an increased muscularis-to-mucosa ratio is a common finding in cases of chronic inflammatory enteropathy and intestinal lymphoma.

Renal findings are most consistent with early or age-related chronic kidney changes, which correlate with the documented isosthenuria.

The pancreas appears hypoechoic with mild ductal visibility but lacks secondary inflammatory changes; these findings are nonspecific and likely age-related, and there is no imaging evidence to support pancreatitis as a cause of the current clinical picture.

Recommendations

- Obtain a definitive diagnosis of the focal intestinal lesion: Consider ultrasound-guided FNA of the focal intestinal lesion as an initial, minimally invasive diagnostic step. If cytology is non-diagnostic or inconsistent with the degree of ultrasonographic abnormality, full-thickness intestinal biopsies is strongly recommended for definitive diagnosis.
- If fine-needle aspiration is non-diagnostic: Before intestinal biopsies proceed with pre-surgical staging and stabilization, including thoracic imaging and repeat abdominal assessment to evaluate for metastatic disease prior to surgery. Repeat a complete blood count to reassess leukocytosis and thrombocytopenia and to better evaluate anesthetic and surgical risk.
- Renal monitoring.





PATIENT

Edison Asher

SPECIES

Feline

BREED

American Shorthair

SEX

Neutered male

AGE

14 years

WEIGHT

8.5 lbs

INTERPRETED BY

Dr. Alicia Angosto
Guerrero

IMAGING PERFORMED BY

Emma Flott

HOSPITAL NAME

Portland Veterinary
Wellness Center

REFERRING VET

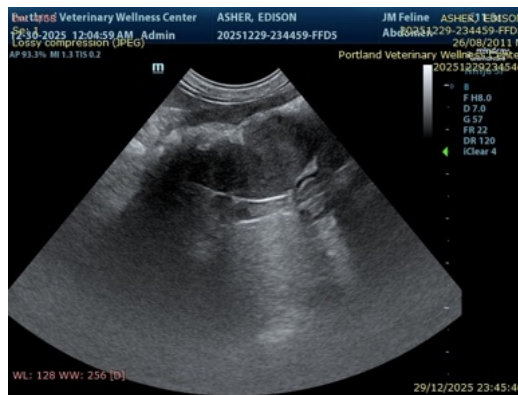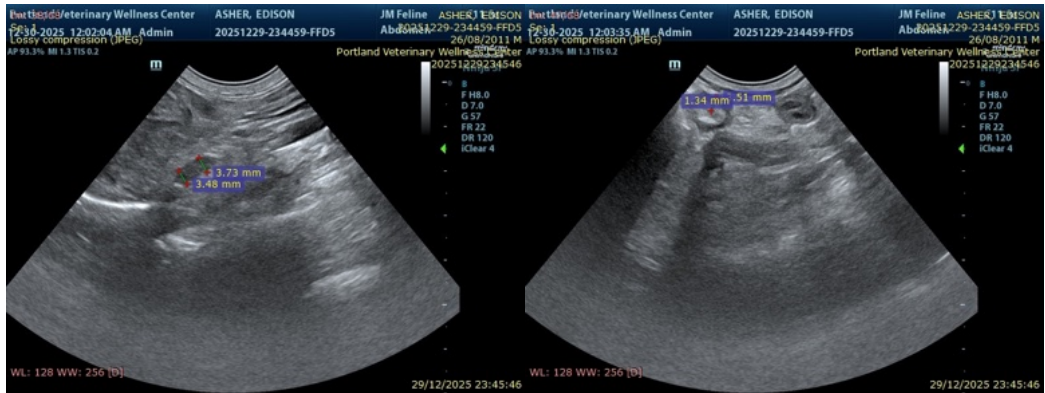
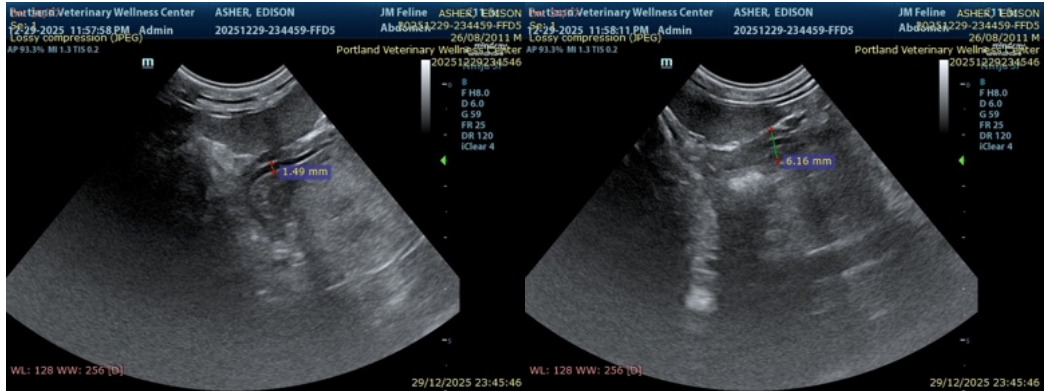
Dr. Mary-Ann Onuta

INVOICE

69726

DATE

12/30/25



The information and recommendations provided are based on the images presented by the referring veterinarian/sonographer. No evaluation can be communicated regarding pathology that was not visible in the image/video clips provided.

Thank you for this referral. If the clinical or image interpretation does not parallel your findings or if I can be of any further assistance please contact me.

Alicia Angosto Guerrero, DMV, PgDip, MSc.



PATIENT

MV Esp Ultrasound in Domestic and Wild Animals

Edison Asher

info@SonoPath.com

SPECIES

Feline

BREED

American Shorthair

SEX

Neutered male

AGE

14 years

WEIGHT

8.5 lbs

INTERPRETED BY

Dr. Alicia Angosto
Guerrero

IMAGING PERFORMED BY

Emma Flott

HOSPITAL NAME

Portland Veterinary
Wellness Center

REFERRING VET

Dr. Mary-Ann Onuta

INVOICE

69726

DATE

12/30/25