



## PATIENT

Jingles Maroney

## SPECIES

Feline

## BREED

Domestic Shorthair

## SEX

Neutered male

## AGE

12 years

## WEIGHT

4.63 kg

## INTERPRETED BY

Dr. Alicia Angosto  
Guerrero

## IMAGING PERFORMED BY

Patrick Hennigan

## HOSPITAL NAME

Mattydale AH

## REFERRING VET

Dr. Hennigan

## INVOICE

69489

## DATE

12/22/25

## PRESENTING CLINICAL SIGNS

History: Presented on October 23rd for a wellness exam. Incidental weight loss of 2.5 pounds in 6 months. Bloodwork revealed a TT4 of 3.6 and a fT4 (ed) was added on which came back high at 66.2. Patient was started on methimazole. Recheck TT4 December 10th was 1.0 but patient has lost an additional 2 pounds. Patient is down an additional 1 pound and 2 ounces today.  
Abnormal PE/Chem/CBC/UA Results: CBC/Chem - wnl 10/23/25 TT4 = 3.6, Ft4 = 66 (10-50)  
12/10/25 TT4 = 1.0

## ULTRASONOGRAPHIC EXAMINATION OF THE ABDOMEN

### *Urinary System*

The urinary bladder lumen is normally distended, and the bladder wall appears thin and smooth. The urine is anechoic. The bladder neck and proximal urethra have a normal appearance. No uroliths or ultrasonographic evidence of inflammatory or neoplastic disease are identified.

The left kidney measures 3.31 × 2.29 cm, with a cortical thickness of 0.42 cm in the sagittal plane. The renal cortex is mildly increased in echogenicity relative to the liver parenchyma, resulting in increased corticomedullary distinction. Very mild pyelectasia is present (approximately 1.13 mm). No nephrolithiasis or hydronephrosis is identified. Color Doppler evaluation demonstrates a normal perfusion pattern.

The right kidney is mildly smaller and irregular in contour, measuring 3.26 × 2.47 cm, with reduced cortical thickness (approximately 0.37 cm). The renal cortex is hyperechoic relative to the liver parenchyma, with decreased corticomedullary definition. No pyelectasia, nephrolithiasis, or hydronephrosis is identified.

### *Adrenal Glands*

The left adrenal gland is visualized and measures 0.31 cm at the cranial pole and 0.33 cm at the caudal pole. The right adrenal gland is not clearly visualized.

### *Spleen*

Splenic thickness measures approximately 0.55 cm. The splenic parenchyma demonstrates normal echogenicity and a fine, homogeneous echotexture without focal parenchymal abnormalities. The splenic capsule is smooth and regular.

### *Liver*

The liver is subjectively normal in size, with sharp margins and a regular contour. The hepatic parenchyma is uniform and isoechoic relative to the falciform fat, with a normal echotexture. No hepatic lymphadenopathy is identified.



## PATIENT

Jingles Maroney

## SPECIES

Feline

## BREED

Domestic Shorthair

## SEX

Neutered male

## AGE

12 years

## WEIGHT

4.63 kg

## INTERPRETED BY

Dr. Alicia Angosto  
Guerrero

## IMAGING PERFORMED BY

Patrick Hennigan

## HOSPITAL NAME

Mattydale AH

## REFERRING VET

Dr. Hennigan

## INVOICE

69489

## DATE

12/22/25

The gallbladder lumen is moderately distended. The gallbladder wall is thin, and the contents are primarily anechoic with a very small amount of biliary sludge. The common bile duct measures approximately 3.62 mm proximally, tapering distally to approximately 0.89 mm, and is considered within acceptable limits for a geriatric cat.

### *Gastrointestinal*

The stomach is empty and folded, with preserved wall layering and a mural thickness of approximately 1.51 mm. The pylorus measures approximately 2.62 mm and contains a minimal amount of luminal fluid.

The duodenum measures approximately 1.88 mm. The jejunum measures between 1.42 and 1.79 mm, with preserved wall layering (mucosa 0.96 mm, submucosa 0.46 mm, muscularis propria 0.24 mm). The ileum measures approximately 1.63 mm, with preserved wall layering (mucosa 0.49 mm, submucosa 0.58 mm, muscularis propria 0.62 mm). The ileocecal junction is not clearly visualized.

No ultrasonographic evidence of inflammation, ileus, or intraluminal foreign material is identified.

The colon measures approximately 1.23 mm in wall thickness and contains formed fecal material within the descending segment.

### *Pancreas*

The right limb and body of the pancreas measure approximately 5.17 mm, and the left limb measures approximately 4.71 mm. Pancreatic parenchyma is isoechoic relative to the adjacent omental fat. The pancreatic duct measures 1.01 mm. No ultrasonographic evidence of pancreatitis or pancreatic neoplasia is identified.

### *Peritoneal Cavity*

No abdominal effusion or ultrasonographic evidence of peritonitis is identified. Cranial mesenteric and ileocecal lymph nodes are not visualized, and the surrounding mesentery appears unremarkable. The iliac trifurcation is normal.

## ULTRASONOGRAPHIC FINDINGS

### PRIMARY FINDINGS

- Asymmetric renal changes, more pronounced in the right kidney (reduced size, cortical thinning, increased echogenicity, decreased corticomedullary definition).
- Renal cortical hyperechogenicity in the left kidney with very mild pyelectasia.

### SECONDARY FINDINGS

- Minimal biliary sludge with mild prominence of the proximal common bile duct, without evidence of biliary obstruction.



## PATIENT

Jingles Maroney

## SPECIES

Feline

## BREED

Domestic Shorthair

## SEX

Neutered male

## AGE

12 years

## WEIGHT

4.63 kg

## INTERPRETED BY

Dr. Alicia Angosto  
Guerrero

## IMAGING PERFORMED BY

Patrick Hennigan

## HOSPITAL NAME

Mattydale AH

## REFERRING VET

Dr. Hennigan

## INVOICE

69489

## DATE

12/22/25

## INTERPRETATION OF THE FINDINGS & FURTHER RECOMMENDATIONS

Abdominal ultrasonography identifies asymmetric chronic renal changes, more pronounced in the right kidney, characterized by reduced size, cortical thinning, increased cortical echogenicity, and decreased corticomedullary definition. The left kidney demonstrates milder changes, including increased cortical echogenicity and very mild pyelectasia. Although serum renal values are currently within reference limits, these findings are most consistent with chronic renal disease at a structural stage.

The gastrointestinal tract demonstrates normal wall thickness and preserved layering throughout, without focal masses, diffuse infiltrative changes, or lymphadenopathy. Similarly, the pancreas appears normal, and no pancreatic or peripancreatic disease is identified.

The liver and biliary system are largely unremarkable, aside from a very small amount of biliary sludge and a mildly prominent proximal common bile duct, which tapers distally and is considered within acceptable limits for a geriatric cat.

Taken together, the ultrasonographic findings do not identify a primary gastrointestinal or abdominal neoplastic process to explain the continued weight loss. In this clinical context—namely, a cat with previously uncontrolled hyperthyroidism now biochemically regulated on methimazole—the persistent and progressive weight loss raises concern for systemic or metabolic consequences, including unmasking or progression of chronic kidney disease, possible overtreatment or intolerance to methimazole, or age-related sarcopenia and reduced caloric assimilation. Importantly, structural renal disease may now be contributing to ongoing weight loss despite normalized TT4, a phenomenon well described following control of hyperthyroidism in cats.

### Recommendations

- Close monitoring of renal function, including serial creatinine, SDMA, urinalysis with UPC and urine specific gravity, given the presence of structural renal disease despite currently normal laboratory values.
- Reassessment of thyroid management.
- Dietary and nutritional evaluation, including caloric intake and protein adequacy, with consideration for early renal-supportive strategies if renal parameters trend upward.
- Clinical monitoring for gastrointestinal signs, with further GI investigation (GI panel) reserved for cases in which appetite, vomiting, or diarrhea worsen, as no structural GI disease is identified at this time.
- Follow-up abdominal ultrasonography may be considered to monitor renal progression if clinically indicated.



## PATIENT

Jingles Maroney

## SPECIES

Feline

## BREED

Domestic Shorthair

## SEX

Neutered male

## AGE

12 years

## WEIGHT

4.63 kg

## INTERPRETED BY

Dr. Alicia Angosto Guerrero

## IMAGING PERFORMED BY

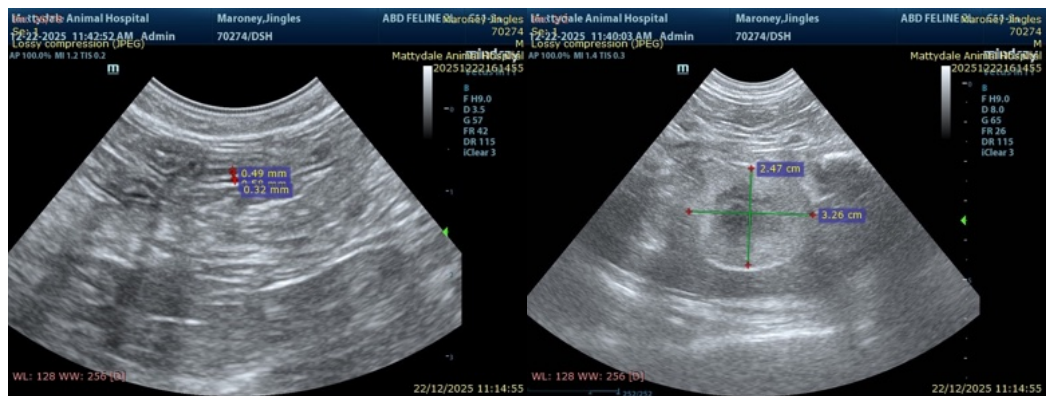
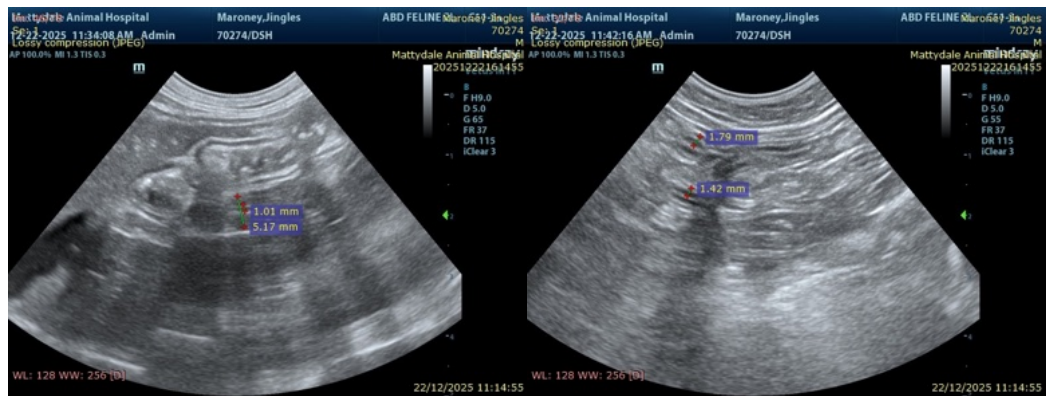
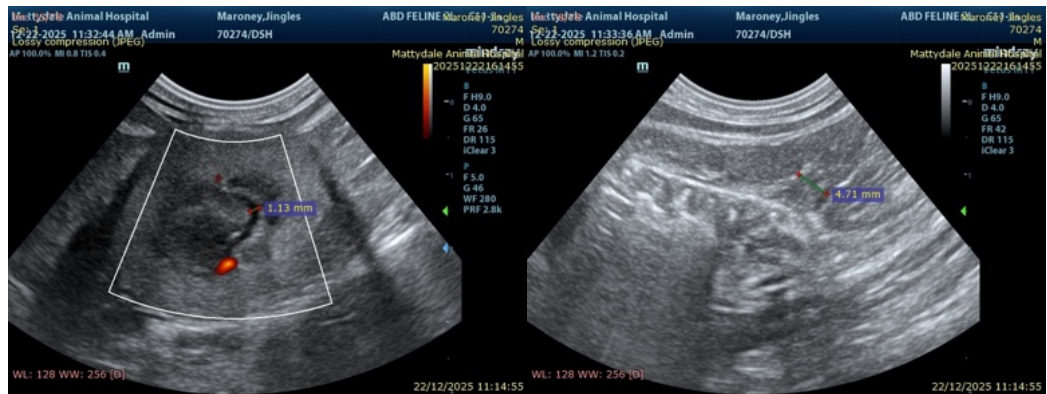Patrick Hennigan

## HOSPITAL NAME

Mattydale AH

## REFERRING VET

Dr. Hennigan



## INVOICE

69489

## DATE

12/22/25

The information and recommendations provided are based on the images presented by the referring veterinarian/sonographer. No evaluation can be communicated regarding pathology that was not visible in the image/video clips provided.

Thank you for this referral. If the clinical or image interpretation does not parallel your findings or if I can be of any further assistance please contact me.

Alicia Angosto Guerrero, DMV, PgDip, MSc.

MV Esp Ultrasound in Domestic and Wild Animals



## PATIENT

[info@SonoPath.com](mailto:info@SonoPath.com)

Jingles Maroney

## SPECIES

Feline

## BREED

Domestic Shorthair

## SEX

Neutered male

## AGE

12 years

## WEIGHT

4.63 kg

## INTERPRETED BY

Dr. Alicia Angosto  
Guerrero

## IMAGING PERFORMED BY

Patrick Hennigan

## HOSPITAL NAME

Mattydale AH

## REFERRING VET

Dr. Hennigan

## INVOICE

69489

## DATE

12/22/25