



PATIENT

Cali Zamora

SPECIES

Feline

BREED

Siamese

SEX

Spayed female

AGE

10 years

WEIGHT

14.73

INTERPRETED BY

Dr. Alicia Angosto
Guerrero

IMAGING PERFORMED BY

Dr. Jazmin Munoz
Gonzalez

HOSPITAL NAME

Oakridge VC

REFERRING VET

Dr. Jazmin Munoz
Gonzalez

INVOICE

69526

DATE

12/22/25

PRESENTING CLINICAL SIGNS

History: PC: Hematuria for a few days. P as always been a more nervous cat, in a multicat household.
Abnormal PE/Chem/CBC/UA Results: BW revealed mild leukocytosis 23.5 characterized by neutrophilia 20.06, monocytosis 0.541, and thrombocytosis 478, AST 148, cholesterol 90, ck 16,298, USG 1.040, 3+ urine protein, 75-100 RBC, TT4 2, FeLV/FIV/hw neg UMIC neg

ULTRASONOGRAPHIC EXAMINATION OF THE ABDOMEN

Urinary System

The urinary bladder lumen is normally distended, and the wall of the urinary bladder appears thickened at the ventral wall. Normal appearance of the bladder neck and proximal urethra. The urine appears mildly turbid, with a calculus measuring 0.88 cm.

The left kidney is normal in shape and size, measuring 3.81×1.96 cm, and the cortical thickness is 0.28 cm in the sagittal plane. The cortex is isoechoic compared to the liver parenchyma. The corticomedullary ratio is normal, and corticomedullary definition is preserved. There is no evidence of pyelectasia, nephroliths, or hydronephrosis. Color Doppler shows a normal pattern.

The right kidney is normal in shape and size, measuring 3.47×2.04 cm, and the cortical thickness is cm in the sagittal plane. The cortex is isoechogenic compared to the liver parenchyma. The corticomedullary ratio is normal, and corticomedullary definition is preserved. There is no evidence of pyelectasia, nephroliths, or hydronephrosis.

Adrenal Glands

Both adrenal glands show normal shape and echogenicity. The left adrenal gland measures 0.33 cm at the cranial pole and 0.30 cm at the caudal pole. The right adrenal gland measures 0.29 cm at the cranial pole and 0.25 cm at the caudal pole.

Spleen

Splenic thickness is 0.88 cm. The parenchyma demonstrates normal echogenicity and fine homogeneous echotexture without focal parenchymal abnormalities. The splenic capsule is smooth and regular.

Liver

The liver is subjectively normal in size, with sharp edges and a regular contour. The liver parenchyma appears uniform and isoechoic compared to the falciform fat, with a normal echotexture. No hepatic lymphadenopathy is observed.

The gallbladder lumen is normally distended. The wall is thin, and the contents are primarily anechoic with a small amount of biliary sludge. No evident dilation of the cystic duct or common bile duct is observed.



PATIENT

Cali Zamora

SPECIES

Feline

BREED

Siamese

SEX

Spayed female

AGE

10 years

WEIGHT

14.73

INTERPRETED BY

Dr. Alicia Angosto
Guerrero

IMAGING PERFORMED BY

Dr. Jazmin Munoz
Gonzalez

HOSPITAL NAME

Oakridge VC

REFERRING VET

Dr. Jazmin Munoz
Gonzalez

INVOICE

69526

DATE

12/22/25

Gastrointestinal

The stomach is empty and folded, with normal mural thickness (1.72 mm) and preserved wall layering. The pylorus measures 2.45 mm. Duodenum: 1.61 mm. Jejunum: 1.99 mm. Ileum: 1.65 mm, with normal wall layering. The ileocecal junction was not clearly visualized. No signs of obstruction, ileus, or foreign material are identified. Colon wall thickness is 0.75 mm, with formed feces in the descending segment.

Pancreas

The pancreas measures 6.75 mm. Pancreatic parenchyma is isoechoic to the adjacent omental fat. The diameter of the pancreatic duct is mm. No signs of active inflammation or neoplastic disease are evident.

Peritoneal Cavity

No abdominal effusion or peritonitis is observed. Cranial mesenteric lymph nodes and ileocecal lymph nodes are not visualized, but the surrounding regions appear unremarkable. The iliac trifurcation is normal.

ULTRASONOGRAPHIC FINDINGS

- Urinary bladder calculus measuring approximately 0.88 cm.
- Focal thickening of the ventral urinary bladder wall, consistent with cystitis.
- Mild turbidity of the urinary bladder contents.

INTERPRETATION OF THE FINDINGS & FURTHER RECOMMENDATIONS

A 0.88 cm urinary bladder calculus is identified, accompanied by focal thickening of the ventral urinary bladder wall, consistent with secondary inflammatory cystitis. These findings provide a clear anatomical explanation for the reported clinical hematuria and the marked microscopic hematuria observed on urinalysis. The absence of bacteriuria and a negative urine culture support a non-infectious inflammatory process, likely exacerbated by environmental stress factors in a nervous cat living in a multicat household.

The marked proteinuria identified on urinalysis is most consistent with a postrenal origin, attributable to inflammation and hemorrhage of the lower urinary tract, rather than primary renal disease. This interpretation is supported by the preserved renal size, architecture, and corticomedullary definition, as well as a well-concentrated urine specific gravity (1.040).

The marked elevation in CK and concurrent AST increase, in the absence of ultrasonographic hepatic abnormalities, are most consistent with skeletal muscle injury, rather than primary hepatocellular disease.

In summary, the ultrasonographic and clinical findings support a primary diagnosis of vesical urolithiasis with secondary inflammatory cystitis, resulting in hematuria and postrenal proteinuria, with no evidence of obstructive uropathy or active renal disease at this time.



PATIENT

Cali Zamora

SPECIES

Feline

BREED

Siamese

SEX

Spayed female

AGE

10 years

WEIGHT

14.73

INTERPRETED BY

Dr. Alicia Angosto
Guerrero

IMAGING PERFORMED BY

Dr. Jazmin Munoz
Gonzalez

HOSPITAL NAME

Oakridge VC

REFERRING VET

Dr. Jazmin Munoz
Gonzalez

INVOICE

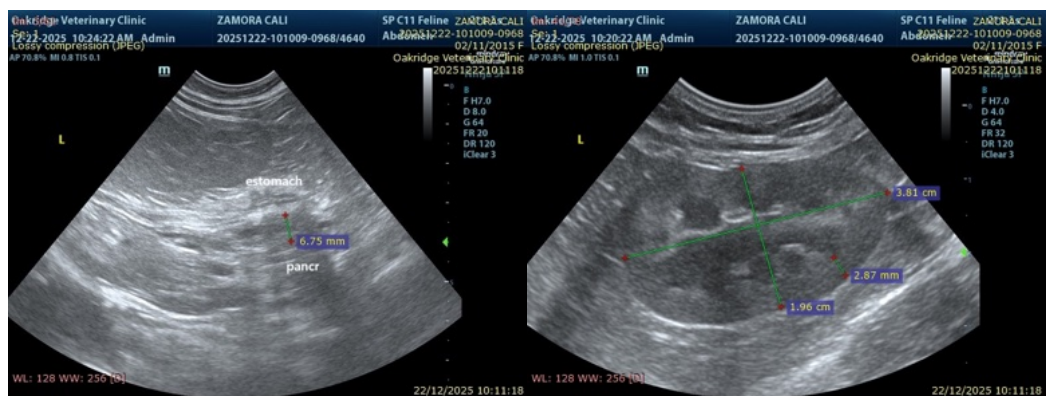
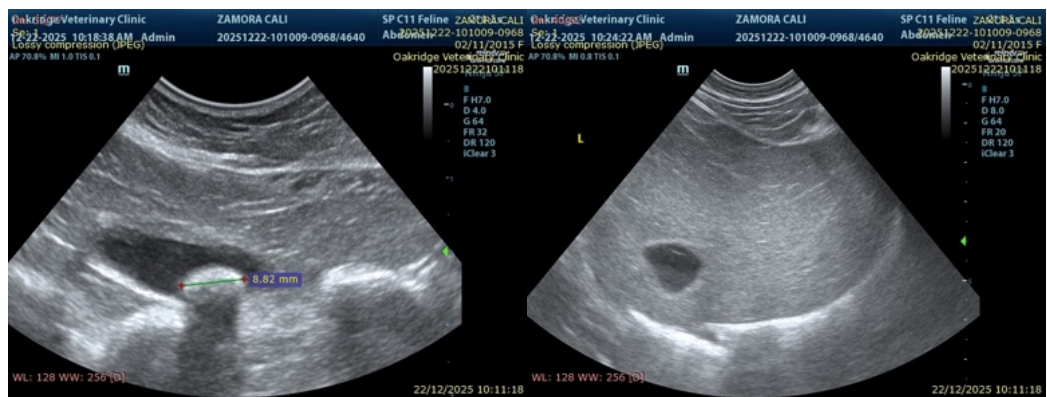
69526

DATE

12/22/25

Recommendations

- Analgesic and anti-inflammatory therapy as clinically indicated.
- In this case, attempting medical dissolution has a low probability of success and may prolong discomfort. Surgical removal provides a definitive solution and allows us to determine the stone type in order to prevent recurrence.
- Monitoring of renal parameters and follow-up urinalysis after resolution of lower urinary tract disease.



The information and recommendations provided are based on the images presented by the referring veterinarian/sonographer. No evaluation can be communicated regarding pathology that was not visible in the image/video clips provided.

Thank you for this referral. If the clinical or image interpretation does not parallel your findings or if I can be of any further assistance please contact me.

Alicia Angosto Guerrero, DMV, PgDip, MSc.

MV Esp Ultrasound in Domestic and Wild Animals

info@SonoPath.com