



PATIENT

Josey Roberts

SPECIES

Canine

BREED

Cattle Dog Lab Mix

SEX

Spayed female

AGE

12 years

WEIGHT

70 lbs

INTERPRETED BY

Dr. Alicia Angosto
Guerrero

IMAGING PERFORMED BY

Christina Wagner

HOSPITAL NAME

Angeles Clinic for
Animals

REFERRING VET

Dr. Wagner

INVOICE

69443

DATE

12/18/25

PRESENTING CLINICAL SIGNS

History: Spleen enlargement found on exam at another clinic. Ultrasound today. Owner reports pet is clinically well, incidental finding

Abnormal PE/Chem/CBC/UA Results: PE --cranial/mid abdominal organomegaly --SQ mass left lateral thorax/axillary region, approx 8 cm CBC,, chem pending

ULTRASONOGRAPHIC EXAMINATION OF THE ABDOMEN

Urinary System

The urinary bladder lumen is normally distended, and the bladder wall appears thin and smooth. The urine is anechoic. The bladder neck and proximal urethra appear normal. No uroliths or ultrasonographic evidence of inflammatory or neoplastic disease are identified.

The left kidney is normal in shape and size, measuring 6.15x4.02 cm, with a cortical thickness of 0.76 cm in the sagittal plane. The renal cortex is isoechoic relative to the liver parenchyma. The corticomedullary ratio and corticomedullary definition are preserved. No evidence of pyelectasia, nephrolithiasis, or hydronephrosis is observed. Color Doppler demonstrates a normal vascular pattern.

The right kidney is normal in shape and size, measuring 7.17x4.01 cm, with a cortical thickness of 0.65 cm in the sagittal plane. The renal cortex is isoechoic relative to the liver parenchyma. The corticomedullary ratio and corticomedullary definition are preserved. No evidence of pyelectasia, nephrolithiasis, or hydronephrosis is observed. Color Doppler demonstrates a normal vascular pattern.

Adrenal Glands

Both adrenal glands are identified. The left adrenal gland is enlarged at the cranial pole, measuring approximately 2.31x1.96 cm (another measurement: 2.34x2.01 cm). Cranial pole appears heterogeneous with a focal hyperechoic area. The caudal pole of the left adrenal gland measures approximately 0.64 cm. The right adrenal gland measures approximately 0.81-0.89 cm at the cranial pole and 0.52-0.58 cm (2 different measurements) at the caudal pole and appears within normal limits.

Spleen

Splenic thickness measures approximately 2.0 cm. The splenic margins are mildly rounded and the contour is slightly irregular in some areas. The splenic parenchyma demonstrates normal echogenicity with a mildly coarse echotexture. A small focal hypoechoic lesion measuring approximately 3.82x5.12 mm is identified. The splenic capsule is smooth and regular. Splenic vasculature appears normal.

Liver

The liver is subjectively enlarged, with rounded margins and a regular contour. The hepatic parenchyma is uniform and isoechoic relative to the falciform fat, with a normal echotexture. No hepatic lymphadenopathy is observed.



PATIENT

Josey Roberts

The gallbladder lumen is normally distended. The gallbladder wall demonstrates multiple small intraluminal projections consistent with mucinous gland hyperplasia. A moderate amount of biliary sludge is present. No dilation of the cystic duct or common bile duct is observed.

SPECIES

Canine

Gastrointestinal

BREED

Cattle Dog Lab Mix

The stomach is distended with ingesta and demonstrates preserved wall layering with a mural thickness of approximately 2.93 mm. The jejunum measures approximately 5.21 mm and demonstrates preserved wall layering. The ileocecal junction is not visualized. No evidence of gastrointestinal obstruction, ileus, or intraluminal foreign material is identified. The colon measures approximately 0.67 mm and contains formed fecal material within the descending segment.

SEX

Spayed female

AGE

12 years

Pancreas

The pancreas measures approximately 1.27 cm in thickness. The right pancreatic limb is visualized. The pancreatic parenchyma is isoechoic relative to the adjacent omental fat. No ultrasonographic evidence of pancreatitis or pancreatic neoplasia is identified.

WEIGHT

70 lbs

Peritoneal Cavity

INTERPRETED BY

Dr. Alicia Angosto
Guerrero

No abdominal effusion or signs of peritonitis are observed. Cranial mesenteric lymph nodes are not visualized, and the surrounding regions appear unremarkable. The iliac trifurcation is normal.

ULTRASONOGRAPHIC FINDINGS

IMAGING PERFORMED BY

Christina Wagner

PRIMARY FINDINGS

- Hepatomegaly with rounded margins.
- The splenic thickness is at the upper limit of normal for a dog of this size. The parenchyma shows a mildly coarse echotexture and a small focal hypoechoic lesion.
- Left adrenal gland enlargement with heterogeneous echotexture and focal hyperechoic area.
- Gallbladder mucinous gland hyperplasia with moderate biliary sludge.
-

HOSPITAL NAME

Angeles Clinic for
Animals

REFERRING VET

Dr. Wagner

INTERPRETATION OF THE FINDINGS & FURTHER RECOMMENDATIONS

INVOICE

69443

The spleen is enlarged, with mildly rounded margins and a mildly coarse echotexture. A small focal hypoechoic lesion is identified, most consistent with benign splenic nodular change, such as nodular hyperplasia or extramedullary hematopoiesis, particularly given the patient's age and lack of clinical signs. No ultrasonographic features suggest aggressive splenic neoplasia.

DATE

12/18/25

The liver is subjectively enlarged with rounded margins but maintains a uniform echotexture and normal echogenicity, without focal lesions or evidence of vascular abnormalities. In a clinically asymptomatic dog, this appearance is most consistent with a benign metabolic hepatopathy, such as vacuolar hepatopathy, rather than primary inflammatory or infiltrative liver disease. These changes may



PATIENT

Josey Roberts

SPECIES

Canine

BREED

Cattle Dog Lab Mix

SEX

Spayed female

AGE

12 years

WEIGHT

70 lbs

INTERPRETED BY

Dr. Alicia Angosto
Guerrero

IMAGING PERFORMED BY

Christina Wagner

HOSPITAL NAME

Angeles Clinic for
Animals

REFERRING VET

Dr. Wagner

INVOICE

69443

DATE

12/18/25

be age-related or secondary to subclinical endocrine influences. No sonographic features suggest clinically significant hepatic dysfunction at this time.

The gallbladder demonstrates mucinous gland hyperplasia with associated biliary sludge, a common incidental finding in older dogs that may be associated with chronic cholestasis or endocrinopathies. No evidence of biliary obstruction is identified.

The left adrenal gland demonstrates focal enlargement and heterogeneous echotexture at the cranial pole, with a discrete hyperechoic area, while the right adrenal gland remains within normal size and appearance. The absence of contralateral adrenal atrophy and lack of vascular invasion make a functional adrenal tumor less likely.

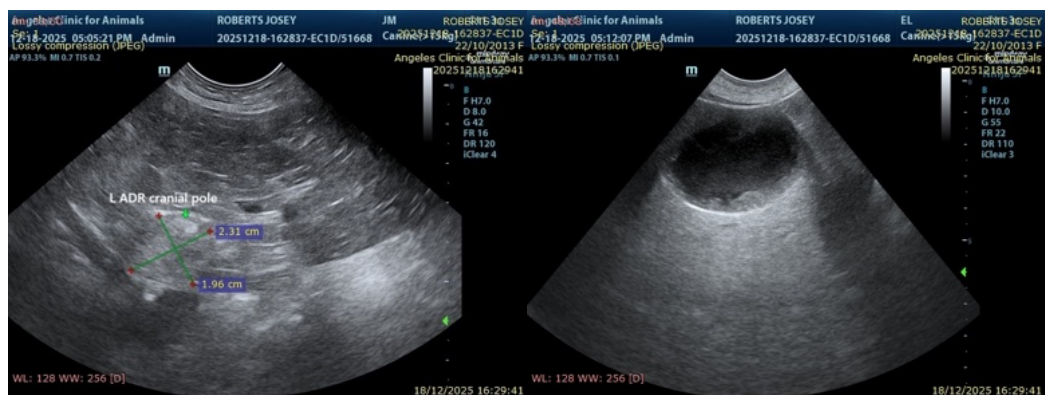These findings are most consistent with either:

- Bilateral adrenal hyperplasia with an incidental nodular change, or
- A non-functional adrenal nodule within an otherwise hyperplastic gland.

At this time, the ultrasonographic appearance alone does not support a definitive diagnosis of hyperadrenocorticism, and the adrenal changes should be interpreted in conjunction with clinical signs and endocrine testing, rather than assumed to be clinically significant.

Recommendations

- Correlation with pending laboratory results (CBC and serum biochemistry) is recommended to further assess hepatic and biliary findings and to help contextualize the ultrasonographic findings.
- Baseline endocrine evaluation: Screening for hyperadrenocorticism may be considered, given the left adrenal gland changes, although imaging findings alone do not support a definitive diagnosis of functional adrenal disease at this time.
- Independent evaluation of the subcutaneous axillary mass is recommended, as this lesion is likely unrelated to the abdominal findings.





PATIENT

Josey Roberts

SPECIES

Canine

BREED

Cattle Dog Lab Mix

SEX

Spayed female

AGE

12 years

WEIGHT

70 lbs

INTERPRETED BY

Dr. Alicia Angosto Guerrero

IMAGING PERFORMED BY

Christina Wagner

HOSPITAL NAME

Angeles Clinic for Animals

REFERRING VET

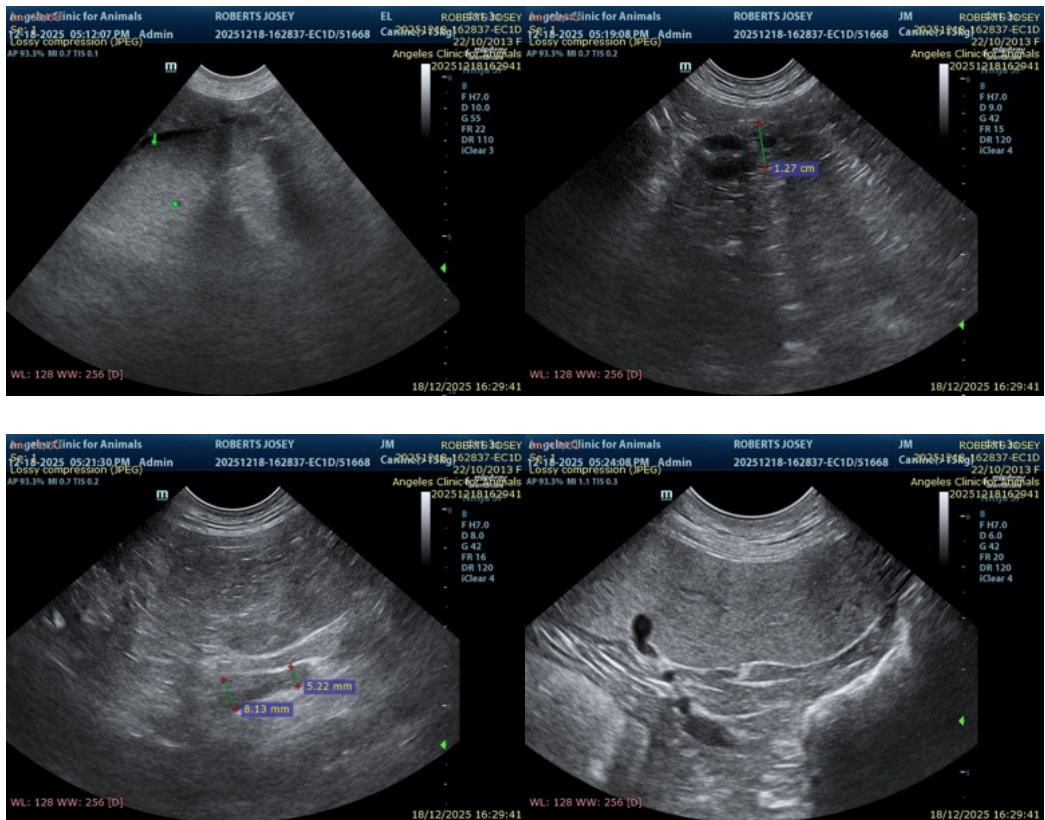
Dr. Wagner

INVOICE

69443

DATE

12/18/25



The information and recommendations provided are based on the images presented by the referring veterinarian/sonographer. No evaluation can be communicated regarding pathology that was not visible in the image/video clips provided.

Thank you for this referral. If the clinical or image interpretation does not parallel your findings or if I can be of any further assistance please contact me.

Alicia Angosto Guerrero, DMV, PgDip, MSc.

MV Esp Ultrasound in Domestic and Wild Animals

info@SonoPath.com