



PATIENT

Mrs Potts

SPECIES

Feline

BREED

Domestic Shorthair

SEX

Spayed female

AGE

3 years

WEIGHT

5.58 kg

INTERPRETED BY

Dr. Alicia Angosto
Guerrero

IMAGING PERFORMED BY

Dr. Corbeil

HOSPITAL NAME

Cochrane AC

REFERRING VET

Dr. Corbeil

INVOICE

69385

DATE

12/17/25

PRESENTING CLINICAL SIGNS

History: 2 month hx CHRONIC VOMITING (since owners adopted her from the shelter). Normal bloodwork and FeLV FIV snap negative. No weight loss (gaining weight/obese), normal appetite, normal fecal output, normal energy/activity level. Partial improvement switching to RC GI mod cal canned and kibble but then vomiting resumed. IBD vs pancreatitis vs neoplasia/lymphoma vs other

ULTRASONOGRAPHIC EXAMINATION OF THE ABDOMEN

Urinary System

The urinary bladder lumen is normally distended, and the bladder wall appears thin and smooth. The urine is predominantly anechoic with scant suspended echoes. The bladder neck and proximal urethra have a normal appearance. There are no calculi and no evidence of inflammatory or neoplastic changes.

The left kidney is normal in shape and size, measuring 4.12×2.48 cm, with a cortical thickness of 0.46 cm in the sagittal plane. The right kidney is normal in shape and size, measuring 4.43×2.39 cm, with a cortical thickness of 0.43 cm in the sagittal plane. Both kidneys: The renal cortex is mildly increased in echogenicity, resulting in increased corticomedullary distinction. No medullary rim sign, pyelectasia, nephroliths, or hydronephrosis are identified. Color Doppler demonstrates a normal perfusion pattern.

Adrenal Glands

The left adrenal gland was not clearly visualized for adequate evaluation. The right adrenal gland measures 0.42 cm at the cranial pole and 0.47 cm at the caudal pole.

Spleen

Splenic thickness is 1.09 cm. The splenic parenchyma demonstrates normal echogenicity and a fine, homogeneous echotexture without focal parenchymal abnormalities. The splenic capsule is smooth and regular.

Liver

The liver is subjectively normal in size, with sharp edges and a regular contour. The hepatic parenchyma appears uniform and isoechoic compared to the falciform fat, with a normal echotexture. No hepatic lymphadenopathy is observed.

The gallbladder lumen is normally distended. The wall is thin, and the contents are primarily anechoic. The common bile duct measures approximately 2.34 mm proximally, tapering to 1.17 mm distally.

Gastrointestinal

The stomach is empty and folded, with preserved wall layering and a mural thickness of approximately 1.67 mm. The pylorus measures approximately 2.51 mm and contains a minimal amount of fluid.



PATIENT

Mrs Potts

SPECIES

Feline

BREED

Domestic Shorthair

SEX

Spayed female

AGE

3 years

WEIGHT

5.58 kg

INTERPRETED BY

Dr. Alicia Angosto
Guerrero

IMAGING PERFORMED BY

Dr. Corbeil

HOSPITAL NAME

Cochrane AC

REFERRING VET

Dr. Corbeil

INVOICE

69385

DATE

12/17/25

The duodenum measures approximately 1.51 mm. The jejunum measures approximately 1.80–2.67 mm, with the following wall layer measurements: mucosa 1.67 mm, submucosa 0.72 mm, and muscularis propria 0.38 mm. The ileum measures approximately 1.62 mm, with preserved wall layering; mucosa measures 0.48 mm, submucosa 0.66 mm, and muscularis propria 0.31 mm. The ileocecal junction measures approximately 2.53 mm, with a muscularis thickness of 0.91 mm. No signs of obstruction, ileus, or foreign material are identified. Mild intraluminal gas is noted within the small intestine.

The colon wall measures approximately 0.79 mm in the ascending colon, 1.09 mm in the transverse colon, and 1.08 mm in the descending colon, with semi-soft fecal material in the lumen and more solid fecal content distally producing mild acoustic shadowing.

Pancreas

The pancreatic right limb measures approximately 4.90 mm, the body 5.27 mm, and the left limb 6.69 mm. Pancreatic parenchyma is isoechoic to the adjacent omental fat. The pancreatic duct measures approximately 0.71 mm. No sonographic evidence of active inflammation or neoplastic disease is identified.

Peritoneal Cavity

No abdominal effusion or peritonitis is observed. Cranial mesenteric, ileocecal, pancreaticoduodenal, and medial iliac lymph nodes are identified and are mildly prominent, measuring at the upper limits of normal, with preserved shape and echogenicity. These findings are most consistent with mild reactive or antigenic lymphoid stimulation. Surrounding fat appears unremarkable.

ULTRASONOGRAPHIC FINDINGS

PRIMARY FINDINGS

- Mild intraluminal gas within the small intestine.
- Borderline to mildly prominent abdominal lymph nodes with reactive appearance.

SECONDARY FINDINGS

- Mildly increased renal cortical echogenicity with preserved architecture.

INTERPRETATION OF THE FINDINGS & FURTHER RECOMMENDATIONS

The gastrointestinal tract demonstrates normal wall thickness and preserved layering throughout, including the stomach, small intestine, and colon. Intestinal wall measurements, including mucosal and muscular layers, fall within expected limits for a feline patient of this age, and muscularis-to-total wall thickness ratios remain within normal range, without evidence of muscular hypertrophy or disproportion suggestive of chronic inflammatory or infiltrative disease. Mild intraluminal gas within the small intestine is noted and is considered nonspecific, commonly associated with functional gastrointestinal disturbances.



PATIENT

Mrs Potts

SPECIES

Feline

BREED

Domestic Shorthair

SEX

Spayed female

AGE

3 years

WEIGHT

5.58 kg

INTERPRETED BY

Dr. Alicia Angosto
Guerrero

IMAGING PERFORMED BY

Dr. Corbeil

HOSPITAL NAME

Cochrane AC

REFERRING VET

Dr. Corbeil

INVOICE

69385

DATE

12/17/25

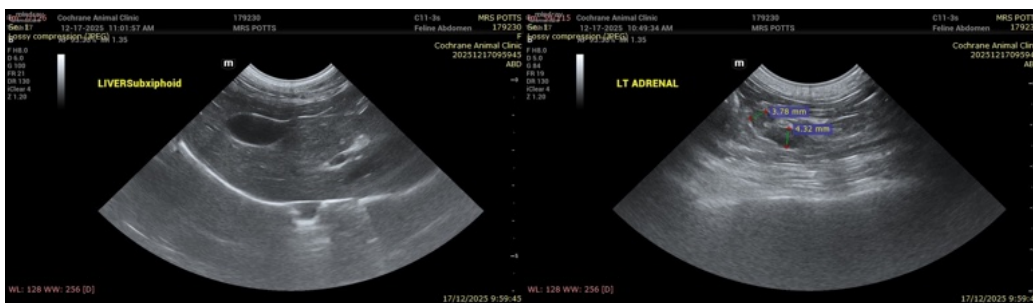
Renal findings include mildly increased renal cortical echogenicity with preserved corticomedullary architecture and normal renal size. In the absence of additional ultrasonographic abnormalities, such as medullary rim sign, pyelectasia, or renal contour irregularities, this finding is considered nonspecific and may reflect benign variation or mild lipid accumulation rather than clinically significant renal disease, particularly in a young, clinically stable cat without supportive laboratory abnormalities.

Abdominal lymph nodes, including the cranial mesenteric, ileocecal, pancreaticoduodenal, and medial iliac lymph nodes, are prominent but remain within upper normal to borderline size limits, with preserved shape and echogenicity. These findings are most consistent with mild reactive lymphoid stimulation rather than pathologic lymphadenopathy. No abdominal effusion or significant inflammatory fat changes are identified.

Overall, the ultrasonographic findings do not support intestinal lymphoma, other neoplasia, or advanced inflammatory bowel disease. Given the patient's young age, normal appetite, weight gain, normal energy level, and lack of systemic illness, the findings are most consistent with a functional or low-grade inflammatory gastrointestinal disorder, such as dietary intolerance, chronic gastritis, or mild inflammatory enteropathy, which may not be detectable on ultrasound.

Recommendations

- Empirical medical management (antiemetics or gastric acid-modulating therapy) may be considered as a therapeutic trial.
- Continue or initiate a strict dietary trial (novel protein or hydrolyzed diet) with complete dietary control for an adequate duration.
- If vomiting persists, consider a feline gastrointestinal panel (including feline pancreatic lipase, cobalamin, and folate) to further assess for subclinical disease.
- Invasive diagnostics (endoscopy or biopsies) are not indicated at this stage unless clinical signs progress, weight loss develops, or laboratory abnormalities emerge.





PATIENT

Mrs Potts

SPECIES

Feline

BREED

Domestic Shorthair

SEX

Spayed female

AGE

3 years

WEIGHT

5.58 kg

INTERPRETED BY

Dr. Alicia Angosto Guerrero

IMAGING PERFORMED BY

Dr. Corbeil

HOSPITAL NAME

Cochrane AC

REFERRING VET

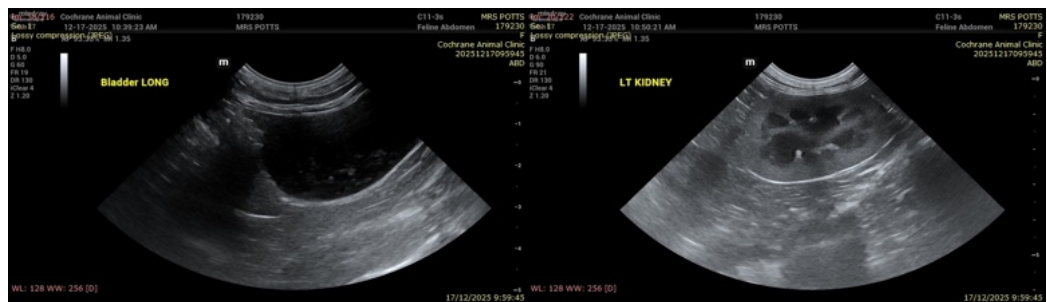
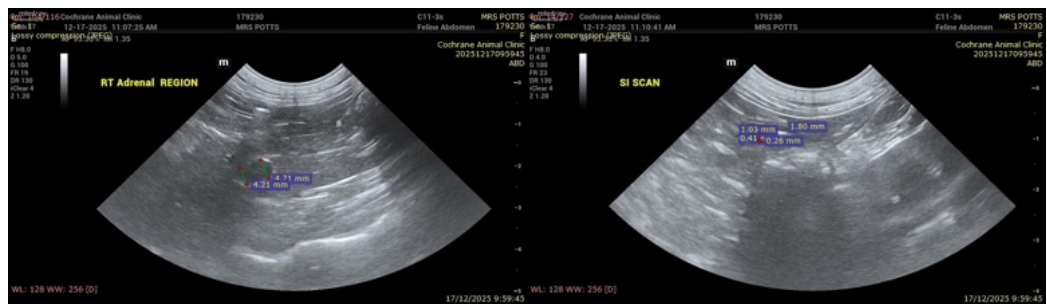
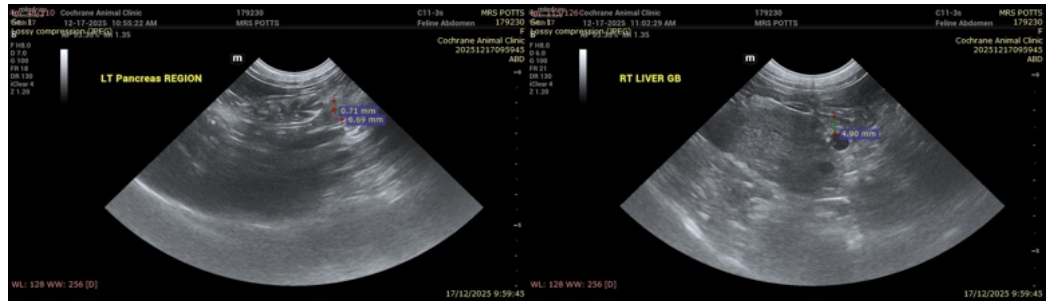
Dr. Corbeil

INVOICE

69385

DATE

12/17/25



The information and recommendations provided are based on the images presented by the referring veterinarian/sonographer. No evaluation can be communicated regarding pathology that was not visible in the image/video clips provided.

Thank you for this referral. If the clinical or image interpretation does not parallel your findings or if I can be of any further assistance please contact me.

Alicia Angosto Guerrero, DMV, PgDip, MSc.

MV Esp Ultrasound in Domestic and Wild Animals

info@SonoPath.com