



PATIENT

Dixie Messer

SPECIES

Feline

BREED

Domestic Shorthair

SEX

Neutered male

AGE

8 years

WEIGHT

5 kg

INTERPRETED BY

Dr. Alicia Angosto
Guerrero

IMAGING PERFORMED BY

Catherine Alexander,
LVT

HOSPITAL NAME

NorthStar VS

REFERRING VET

Dr. Phillips

INVOICE

69234

DATE

12/12/25

PRESENTING CLINICAL SIGNS

History: p presented for not eating since monday. pet will keep water down but not food. pet is not having diarrhea. stools are normal and urination is normal per o. pet is still having bowel movements. no pancreatitis on bloodwork and moderate dehydration noted. remaining bloodwork was normal
Radiographic Conclusions/Recommendations: 1. No evidence of mechanical obstruction or obvious intraluminal foreign material is confirmed radiographically. The top differentials would include gastroenteritis, metabolic disease, or acute on chronic enteropathy (IBD, LSA etc.). 2. Moderate to severe left degenerative nephropathy. 3. Soft tissue opacity nodular structure along the caudal lateral margin of the left kidney could represent a nodule associated with the tail of the spleen, left limb of the pancreas, or a regional lymph node. This needs to be further assessed with an ultrasound. 4. Normal thorax
Comments: Abdominal ultrasound is indicated.

ULTRASONOGRAPHIC EXAMINATION OF THE ABDOMEN

Urinary System

The urinary bladder lumen is poorly distended, and the bladder wall measures 2.01 mm and appears smooth. Due to underdistension, wall thickness may be overestimated. The urine is anechoic. The bladder neck and proximal urethra have a normal appearance. There are no calculi and no evidence of inflammatory or neoplastic changes.

The left kidney is small and irregular in shape, measuring 2.71 × 2.17 cm, with a cortical thickness of 0.34 cm in the sagittal plane. The renal cortex is increased in echogenicity, resulting in increased corticomedullary distinction. A triangular hyperechoic cortical lesion is identified, compatible with a renal infarct. There is no evidence of pyelectasia, nephroliths, or hydronephrosis.

The right kidney is normal in shape and size, measuring 4.12 × 2.32 cm, with a cortical thickness of 0.38 cm in the sagittal plane. The renal cortex is increased in echogenicity, resulting in increased corticomedullary distinction, with presence of a medullary rim sign. There is no evidence of pyelectasia, nephroliths, or hydronephrosis.

Adrenal Glands

The adrenal glands are not visualized.

Spleen

Splenic thickness is 0.63 cm. The parenchyma demonstrates normal echogenicity and a fine, homogeneous echotexture, with a homogeneous isoechoic nodule measuring 1.17 × 1.24 cm that deforms the splenic capsule.



PATIENT

Dixie Messer

SPECIES

Feline

BREED

Domestic Shorthair

SEX

Neutered male

AGE

8 years

WEIGHT

5 kg

INTERPRETED BY

Dr. Alicia Angosto
Guerrero

IMAGING PERFORMED BY

Catherine Alexander,
LVT

HOSPITAL NAME

NorthStar VS

REFERRING VET

Dr. Phillips

INVOICE

69234

DATE

12/12/25

Liver

The liver is subjectively normal in size, with sharp edges and a regular contour. The hepatic parenchyma appears uniform and isoechoic compared to the falciform fat, with a normal echotexture. No hepatic lymphadenopathy is observed.

The gallbladder lumen is normally distended. The wall is thin, and the contents are anechoic. No dilation of the cystic duct or common bile duct is observed.

Gastrointestinal

The stomach is empty and folded, with a mural thickness of 1.76 mm and preserved wall layering. The pylorus measurement is not available. The duodenum measures 1.69 mm.

The jejunum measures 2.14 mm in total wall thickness, with the following layer measurements: mucosa 0.96 mm, submucosa 0.74 mm, and muscularis propria 0.52 mm. The ileum measures 2.10 mm in total wall thickness, with the following layer measurements: mucosa 0.53 mm, submucosa 0.54 mm, and muscularis propria 0.49 mm. Wall layering is preserved. The ileocecal junction measures 3.16 mm, with a muscularis thickness of 0.93 mm.

The colon wall thickness measures 0.79 mm, with formed feces present in the descending segment.

Pancreas

The pancreas is not visualized; however, the evaluated regions do not show evidence of overt inflammatory changes.

Peritoneal Cavity

A very small amount of abdominal effusion is observed within the splenorenal recess. The ileocecal lymph nodes are normal. Cranial mesenteric lymph nodes are not visualized, but the surrounding regions appear unremarkable. The iliac trifurcation appears normal.

ULTRASONOGRAPHIC FINDINGS

- Markedly reduced size and irregular contour of the left kidney, and triangular hyperechoic cortical lesion.
- Increased renal cortical echogenicity bilaterally with increased corticomedullary distinction.
- Medullary rim sign in the right kidney.
- Homogeneous isoechoic splenic nodule deforming the splenic capsule.
- Very small volume of abdominal effusion within the splenorenal recess.



PATIENT

Dixie Messer

SPECIES

Feline

BREED

Domestic Shorthair

SEX

Neutered male

AGE

8 years

WEIGHT

5 kg

INTERPRETED BY

Dr. Alicia Angosto
Guerrero

IMAGING PERFORMED BY

Catherine Alexander,
LVT

HOSPITAL NAME

NorthStar VS

REFERRING VET

Dr. Phillips

INVOICE

69234

DATE

12/12/25

INTERPRETATION OF THE FINDINGS & FURTHER RECOMMENDATIONS

The markedly small and irregular left kidney, in combination with bilateral increased cortical echogenicity, supports chronic renal parenchymal disease, with the left kidney likely representing advanced chronic change or end-stage renal disease. The presence of a triangular hyperechoic cortical lesion is most consistent with a renal infarct, suggesting a prior vascular insult and contributing to asymmetric renal degeneration. The medullary rim sign in the right kidney further supports chronic renal pathology.

The splenic nodule, characterized as a well-defined, homogeneous, isoechoic lesion deforming the splenic capsule, is most consistent with a benign splenic nodular process, such as nodular hyperplasia or a benign stromal lesion. There are no ultrasonographic features suggestive of aggressive splenic disease; however, ultrasonography alone cannot definitively characterize the nature of the lesion.

The gastrointestinal tract appears structurally normal, with preserved wall layering and wall thickness measurements within expected limits throughout the stomach and intestines. There is no sonographic evidence of mechanical obstruction or overt infiltrative intestinal disease. A mild or early inflammatory enteropathy cannot be excluded, as low-grade gastrointestinal disease may be present without definitive ultrasonographic abnormalities.

A very small amount of abdominal effusion, confined to the splenorenal recess, is identified. Given its minimal volume and localized distribution, this finding is nonspecific and may represent a reactive or incidental change, potentially associated with underlying renal disease or focal splenic pathology. There are no additional ultrasonographic features to suggest septic, hemorrhagic, or neoplastic effusion at this time.

Overall, imaging findings support chronic kidney disease with asymmetric renal involvement, and renal dysfunction should be considered a significant contributing factor to the patient's current clinical presentation.

Recommendations

- Correlation with renal function parameters, including serial creatinine, SDMA, urine specific gravity, UPC and blood pressure measurement, is recommended to further characterize the severity and stage of renal disease.
- Monitor splenic lesion. If there is clinical concern or interval change on follow-up, sampling of the splenic lesion may be considered at the discretion of the attending clinician.
- If metabolic disease or acute on chronic enteropathy remains a clinical concern, further evaluation with a comprehensive gastrointestinal panel and thyroid testing may be considered to assess for functional or biochemical disease not detectable by imaging, including low-grade enteropathy or endocrine disease.



PATIENT

Dixie Messer

SPECIES

Feline

BREED

Domestic Shorthair

SEX

Neutered male

AGE

8 years

WEIGHT

5 kg

INTERPRETED BY

Dr. Alicia Angosto
Guerrero

IMAGING PERFORMED BY

Catherine Alexander,
LVT

HOSPITAL NAME

NorthStar VS

REFERRING VET

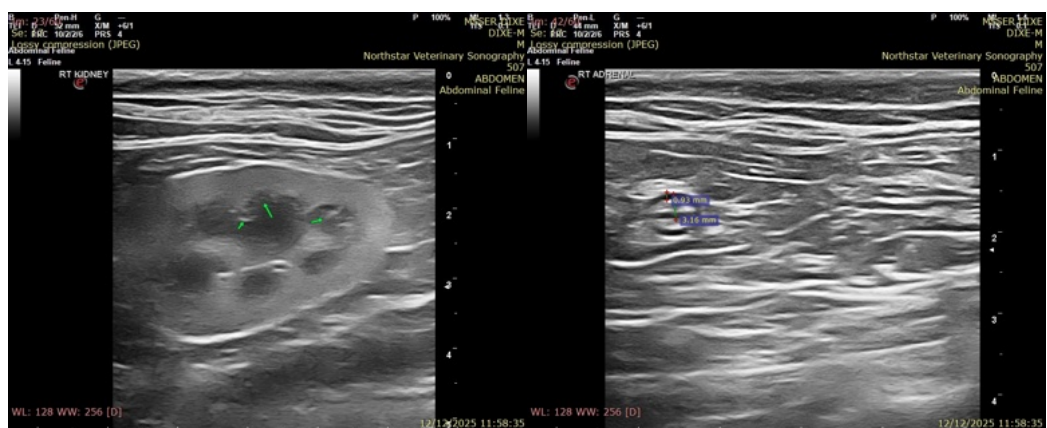
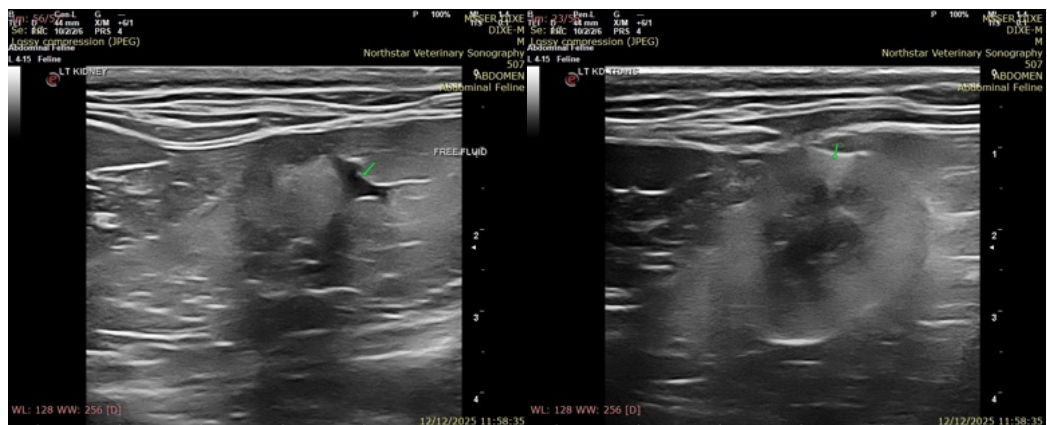
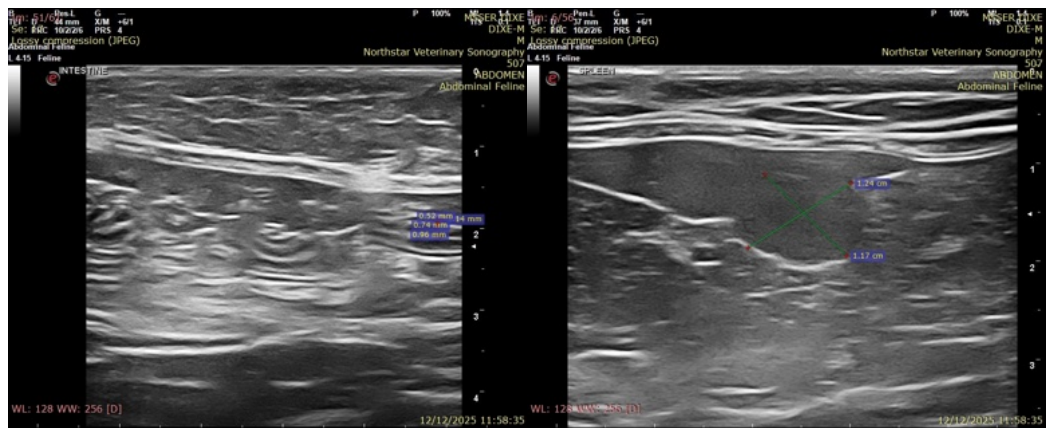
Dr. Phillips

INVOICE

69234

DATE

12/12/25



The information and recommendations provided are based on the images presented by the referring veterinarian/sonographer. No evaluation can be communicated regarding pathology that was not visible in the image/video clips provided.

Thank you for this referral. If the clinical or image interpretation does not parallel your findings or if I can be of any further assistance please contact me.



PATIENT

Alicia Angosto Guerrero, DMV, PgDip, MSc.

Dixie Messer

MV Esp Ultrasound in Domestic and Wild Animals

SPECIES

info@SonoPath.com

Feline

BREED

Domestic Shorthair

SEX

Neutered male

AGE

8 years

WEIGHT

5 kg

INTERPRETED BY

Dr. Alicia Angosto
Guerrero

**IMAGING
PERFORMED BY**

Catherine Alexander,
LVT

HOSPITAL NAME

NorthStar VS

REFERRING VET

Dr. Phillips

INVOICE

69234

DATE

12/12/25