

**PATIENT**

Einstein Pham

SPECIES

Canine

BREED

Corgi Cross

SEX

Neutered male

AGE

12 years

WEIGHT

11 kg

INTERPRETED BYDr. Alicia Angosto
Guerrero**IMAGING
PERFORMED BY**Catherine Alexander,
LVT**HOSPITAL NAME**NorthStar Veterinary
Sonography**REFERRING VET**

Dr. Robinson

INVOICE

69506

DATE

12/10/25

PRESENTING CLINICAL SIGNSHistory: Hypercalcemia, lymphoma
Abnormal PE/Chem/CBC/UA Results: Ca++ 1.43**ULTRASONOGRAPHIC EXAMINATION OF THE ABDOMEN****Urinary System**

The bladder lumen is normally distended, and the wall of the urinary bladder appears thin and smooth. The urine is anechoic. Normal appearance of the proximal urethra and vesicoureteral junction. There are no calculi and no evidence of inflammatory or neoplastic changes.

The left kidney is normal in shape and size: 5.07 x 2.51 cm, and the thickness of the cortex is 0.44 cm in the sagittal plane. The cortex is isoechoic compared to the liver parenchyma. The corticomedullary ratio is normal and the corticomedullary definition is preserved. There is no evidence of pyelectasia, nephroliths, or hydronephrosis.

The right kidney is normal in shape and size: 5.37 x 3.91 cm, and the thickness of the cortex is 0.43 cm in the sagittal plane. The cortex is isoechoic compared to the liver parenchyma. The corticomedullary ratio is normal and the corticomedullary definition is preserved. There is no evidence of pyelectasia, nephroliths, or hydronephrosis.

The prostate measured 2.20 x 0.9 cm, small, hypoechoic, homogeneous, compatible with atrophy after orchiectomy.

Adrenal Glands

Both adrenal glands show normal shape and echogenicity. The left adrenal gland measures 0.44 cm at the cranial pole and 0.44 cm at the caudal pole. The right adrenal gland measures 0.45 cm at the cranial pole and 0.46 cm at the caudal pole.

Spleen

Splenic thickness is 1.92 cm. The parenchyma demonstrates normal echogenicity, slightly hyperechoic compared to the liver parenchyma. With several 2–4 mm small 2x0.7 cm hyperechoic areas around the splenic hilum, compatible with areas of fibrosis, myelolipomas, or areas of hyperplasia. The splenic capsule is smooth and regular.

Liver

The liver is subjectively normal in size, with sharp edges and a regular contour. The liver parenchyma looks uniform and is isoechoic compared to the falciform fat, with a normal echotexture. No hepatic lymphadenopathy is observed.

The gallbladder lumen is normally distended. The wall is thin, and the contents show a considerable amount of biliary sludge. No evident dilation of the cystic duct or common bile duct is observed.



PATIENT

Einstein Pham

Gastrointestinal

SPECIES

Canine

BREED

Corgi Cross

SEX

Neutered male

AGE

12 years

WEIGHT

11 kg

INTERPRETED BY

Dr. Alicia Angosto
Guerrero

IMAGING PERFORMED BY

Catherine Alexander,
LVT

HOSPITAL NAME

NorthStar Veterinary
Sonography

REFERRING VET

Dr. Robinson

INVOICE

69506

DATE

12/10/25

The stomach is semidistended with partially digested food, some gas pattern, and mural thickness of 2.05 mm with preserved wall layering. The pylorus wall measures 4.67 mm.

Duodenum: 4.17 mm, with discrete hyperechoic punctate foci in the mucosa. Jejunum: 2.95 mm. Ileum: 2.23 mm. Normal wall layering. No signs of inflammation, ileus, or foreign material are identified.

Colon: ascending 2.17 mm, empty. Transverse 0.93 mm, descending 0.70 mm, with few formed feces in the lumen.

Pancreas

The pancreas measured 0.8 cm. The parenchyma of the pancreas is isoechoic to the adjacent omental fat. No signs of active inflammation or neoplastic disease are evident.

Peritoneal Cavity

No abdominal effusion or peritonitis is observed. Abdominal mesenteric lymph nodes are not visualized, but the surrounding regions appear unremarkable. The iliac trifurcation is normal.

ULTRASONOGRAPHIC FINDINGS

PRIMARY FINDINGS

- Spleen displays several small hyperechoic foci/areas.

SECONDARY FINDINGS

- Prostate is small, homogeneous, hypoechoic, consistent with post-orchietomy atrophy.

INTERPRETATION OF THE FINDINGS & FURTHER RECOMMENDATIONS

The abdominal ultrasound does not reveal any evidence of neoplasia, lymphadenopathy, or organ involvement that would explain this patient's hypercalcemia. While lymphoma remains a major differential given the clinical history, there are no ultrasonographic signs of active abdominal disease. Endocrine causes such as primary hyperparathyroidism, vitamin D intoxication, idiopathic hypercalcemia, or less likely hypoadrenocorticism should also be considered, and further hormonal testing is recommended to differentiate among these possibilities.

Differentials for the splenic findings include: Benign hyperplasia, fibrosis, myelolipoma, or less commonly: resolving infarcts. These findings do not resemble lymphomatous infiltration and are likely incidental, age-related changes.



PATIENT

Einstein Pham

SPECIES

Canine

BREED

Corgi Cross

SEX

Neutered male

AGE

12 years

WEIGHT

11 kg

INTERPRETED BY

Dr. Alicia Angosto
Guerrero

IMAGING PERFORMED BY

Catherine Alexander,
LVT

HOSPITAL NAME

NorthStar Veterinary
Sonography

REFERRING VET

Dr. Robinson

INVOICE

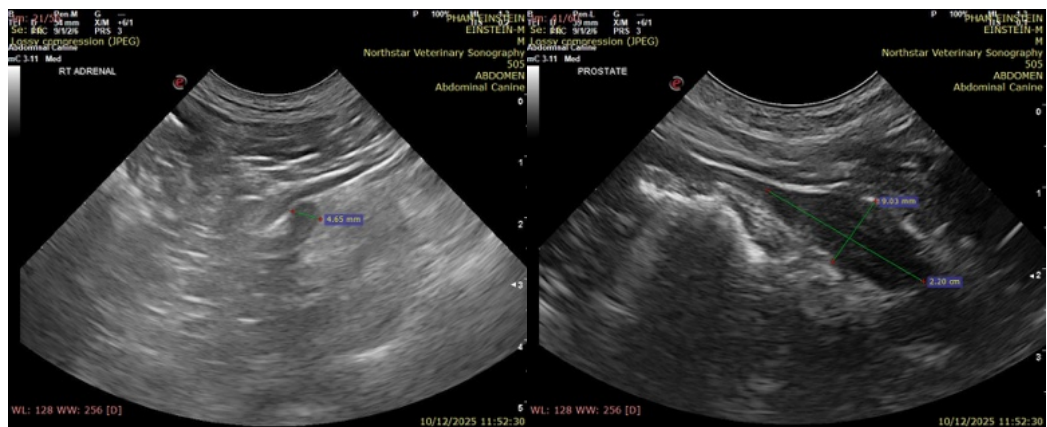
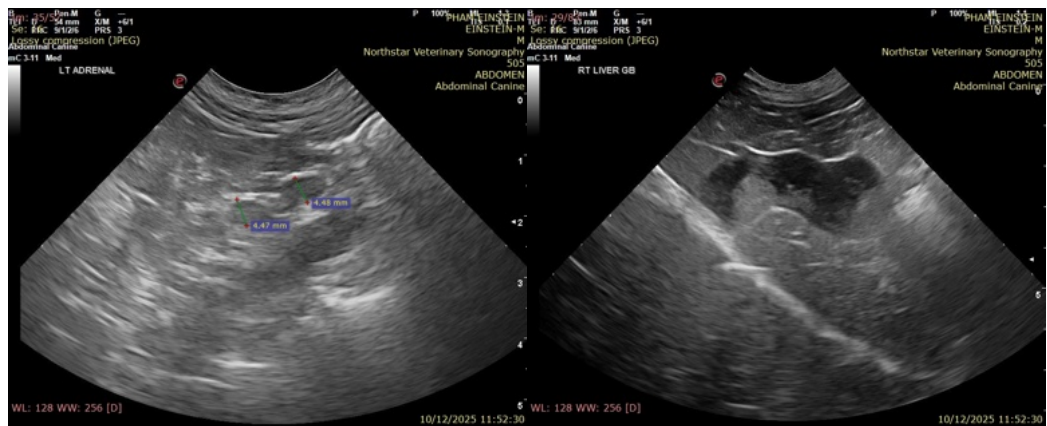
69506

DATE

12/10/25

Recommendations

- Evaluate PTH, PTHrP, and vitamin D metabolites to determine the source of hypercalcemia.
- Review whether lymphoma is confirmed, clinical suspicion, or past disease in remission.
- Consider thoracic imaging if lymphoma relapse or HHM is suspected.
- Cervical ultrasound if primary hyperparathyroidism is a concern.





PATIENT

Einstein Pham

SPECIES

Canine

BREED

Corgi Cross

SEX

Neutered male

AGE

12 years

WEIGHT

11 kg

INTERPRETED BY

Dr. Alicia Angosto
Guerrero

IMAGING PERFORMED BY

Catherine Alexander,
LVT

HOSPITAL NAME

NorthStar Veterinary
Sonography

REFERRING VET

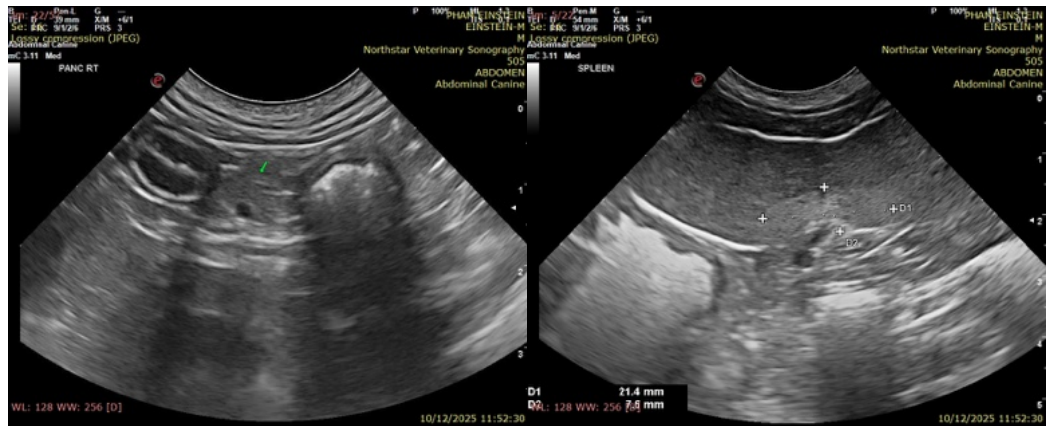
Dr. Robinson

INVOICE

69506

DATE

12/10/25



The information and recommendations provided are based on the images presented by the referring veterinarian/sonographer. No evaluation can be communicated regarding pathology that was not visible in the image/video clips provided.

Thank you for this referral. If the clinical or image interpretation does not parallel your findings or if I can be of any further assistance please contact me.

Alicia Angosto Guerrero, DMV, PgDip, MSc.

MV Esp Ultrasound in Domestic and Wild Animals

info@SonoPath.com