



## PATIENT

Clara Cholewa

## SPECIES

Canine

## BREED

Mix

## SEX

Spayed female

## AGE

9 years

## WEIGHT

61.5 lbs

## INTERPRETED BY

Dr. Alicia Angosto  
Guerrero

## IMAGING PERFORMED BY

Danielle Shemanski,  
DVM, MA

## HOSPITAL NAME

Western New York VS

## REFERRING VET

Dr. Walker

## INVOICE

69128

## DATE

11/26/25

## PRESENTING CLINICAL SIGNS

**History:** Clara presents for an abdominal ultrasound due to a history of elevated liver values, specifically alkaline phosphatase (ALP), discovered on routine blood work. The owner reports that the elevations have been noted for approximately 1.5 years. The ALP values have been trending upwards: - 2023: 352 - 2024: 736 - 2025: Current values, which prompted the visit. Clara has a history of seizures and has been on Zonisamide long-term for approximately 10 years. O has not had any observed seizures while on this medication. She receives Rimadyl very rarely, with the last dose being approximately 6 months ago. Concern for the long term effects of zonisamide on the liver  
**CLINICAL SIGNS:** none.  
**MEDICATIONS:** Zonisamide 100mg: 1 cap PO BID. Rimadyl 50mg: PO PRN (utilizes 2-3x per month). on an otc jt supplement and fish oil.

**Abnormal PE/Chem/CBC/UA Results:** ALKP level increased. 2023: 352 2024: 736 2025: 1021

## ULTRASONOGRAPHIC EXAMINATION OF THE ABDOMEN

### Urinary System

The bladder lumen is normally distended, and the urinary bladder wall appears thin and smooth. The urine is anechoic. Normal appearance of the proximal urethra and vesicoureteral junction. There are no calculi and no evidence of inflammatory or neoplastic changes.

The left kidney is normal in shape and size: 7.32 × 2.76 cm, with cortical thickness of 0.57 cm in the sagittal plane. The cortex is isoechoic compared to the liver parenchyma. The corticomedullary ratio is normal, and corticomedullary definition is preserved. There is no evidence of pyelectasia, nephroliths, or hydronephrosis. Color Doppler shows a normal pattern.

The right kidney is normal in shape and size: 7.50 × 2.23 cm, with cortical thickness of 0.56 cm in the sagittal plane. The cortex is isoechoic compared to the liver parenchyma. The corticomedullary ratio is normal, and corticomedullary definition is preserved. There is no evidence of pyelectasia, nephroliths, or hydronephrosis. Color Doppler shows a normal pattern.

### Adrenal Glands

Both adrenal glands show normal shape and echogenicity. Left adrenal gland: 0.53 cm (cranial pole), 0.62 cm (caudal pole). Right adrenal gland: 0.63 cm (cranial pole), 0.66 cm (caudal pole).

### Spleen

Splenic thickness is 2.46 cm. The parenchyma demonstrates normal echogenicity and a fine, homogeneous echotexture without focal parenchymal abnormalities. The splenic capsule is smooth and regular.



## PATIENT

Clara Cholewa

## SPECIES

Canine

## BREED

Mix

## SEX

Spayed female

## AGE

9 years

## WEIGHT

61.5 lbs

## INTERPRETED BY

Dr. Alicia Angosto  
Guerrero

## IMAGING PERFORMED BY

Danielle Shemanski,  
DVM, MA

## HOSPITAL NAME

Western New York VS

## REFERRING VET

Dr. Walker

## INVOICE

69128

## DATE

11/26/25

## Liver

The liver is subjectively normal in size, with sharp edges and a regular contour. The liver parenchyma appears uniform and isoechoic compared to the falciform fat, with a normal echotexture. No hepatic lymphadenopathy is observed.

The gallbladder lumen is normally distended. The wall is thin, and the contents are primarily anechoic with a small amount of biliary sludge. No evident dilation of the cystic duct or common bile duct is observed.

## Gastrointestinal

The stomach is empty and folded, with mural thickness of 3.19 mm and preserved wall layering.

Pylorus: 5.81 mm. Jejunum: 5.46 mm. Ileum: 2.98 mm. Normal wall layering throughout. The ileocecal junction was not visualized. No signs of obstruction, ileus, or foreign material are identified.

Colon: wall thickness 0.93 mm, containing formed feces.

## Pancreas

The right limb, body, and left limb appear normal. The pancreatic parenchyma is isoechoic to the adjacent omental fat. The pancreatic duct diameter was not measurable. No signs of active inflammation or neoplastic disease are evident.

## Peritoneal Cavity

No abdominal effusion or peritonitis is observed. Cranial mesenteric and ileocecal lymph nodes are not visualized, but surrounding regions appear unremarkable. The iliac trifurcation is normal.

## ULTRASONOGRAPHIC FINDINGS

- Very small amount of non-obstructive biliary sludge.
- Mild pyloric thickening.

## INTERPRETATION OF THE FINDINGS & FURTHER RECOMMENDATIONS

No ultrasonographic abnormalities are identified to explain the patient's progressively elevated ALP. The liver shows normal size, normal echogenicity, and normal parenchymal architecture, with no evidence of nodular change, biliary obstruction, infiltrative disease, portal abnormalities, or hepatic lymphadenopathy. A small amount of non-obstructive biliary sludge is present, which is commonly incidental in middle-aged to older dogs. The gallbladder wall is thin and normal.

The gastrointestinal tract is generally normal, aside from mild pyloric thickening that remains within acceptable limits and is not likely clinically significant in an asymptomatic patient.



## PATIENT

Clara Cholewa

## SPECIES

Canine

## BREED

Mix

## SEX

Spayed female

## AGE

9 years

## WEIGHT

61.5 lbs

## INTERPRETED BY

Dr. Alicia Angosto  
Guerrero

## IMAGING PERFORMED BY

Danielle Shemanski,  
DVM, MA

## HOSPITAL NAME

Western New York VS

## REFERRING VET

Dr. Walker

## INVOICE

69128

## DATE

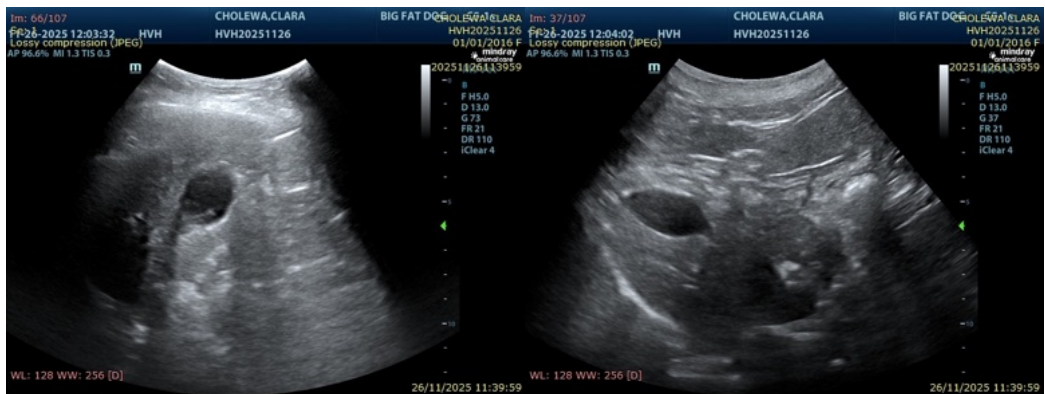
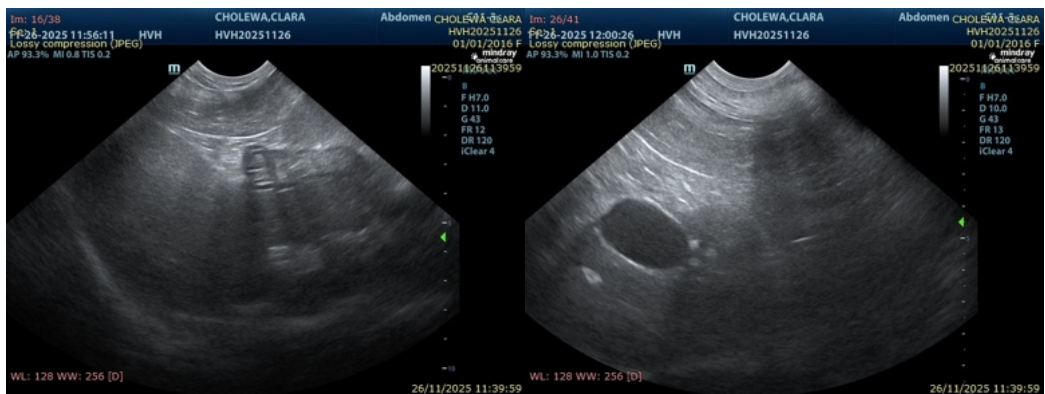
11/26/25

Findings are most consistent with medication-induced ALP elevation or benign steroid-like hepatopathy / enzyme induction, rather than true structural liver disease.

Other differentials include breed/individual metabolic variation, or early diffuse hepatopathy, but no ultrasonographic evidence supports clinically significant hepatobiliary pathology at this time.

### Recommendations

- Continue monitoring ALP trends as long as ALT, AST, GGT, bilirubin, and hepatic synthetic markers remain normal.
- If ALP continues to rise sharply or additional enzymes become abnormal, consider further workup (bile acid stimulation test or liver FNA).
- No change in zonisamide therapy is indicated based on ultrasound findings alone. If seizure control is excellent and the patient is asymptomatic, continuation is appropriate unless neurology or internal medicine advises otherwise.





## PATIENT

Clara Cholewa

## SPECIES

Canine

## BREED

Mix

## SEX

Spayed female

## AGE

9 years

## WEIGHT

61.5 lbs

## INTERPRETED BY

Dr. Alicia Angosto  
Guerrero

## IMAGING PERFORMED BY

Danielle Shemanski,  
DVM, MA

## HOSPITAL NAME

Western New York VS

## REFERRING VET

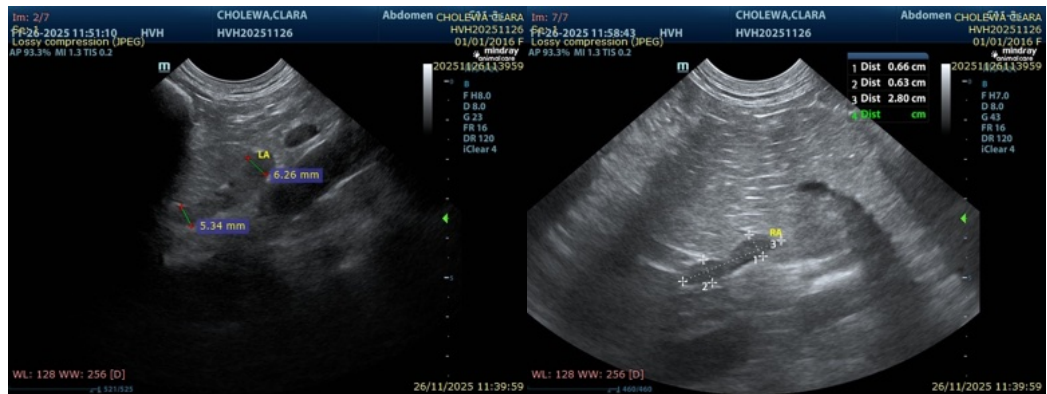
Dr. Walker

## INVOICE

69128

## DATE

11/26/25



The information and recommendations provided are based on the images presented by the referring veterinarian/sonographer. No evaluation can be communicated regarding pathology that was not visible in the image/video clips provided.

Thank you for this referral. If the clinical or image interpretation does not parallel your findings or if I can be of any further assistance please contact me.

Alicia Angosto Guerrero, DMV, PgDip, MSc.

MV Esp Ultrasound in Domestic and Wild Animals

[info@SonoPath.com](mailto:info@SonoPath.com)