



PATIENT

Baxter Nigro

SPECIES

Canine

BREED

Shih Tzu

SEX

Neutered male

AGE

14 years

WEIGHT

19 lbs

PRESENTING CLINICAL SIGNS

History: Large eye mass - met check
Abnormal PE/Chem/CBC/UA Results: Bloodwork pending

ULTRASONOGRAPHIC EXAMINATION OF THE ABDOMEN

Urinary System

The bladder lumen is normally distended, and the urinary bladder wall appears thin and smooth. The urine is primarily anechoic, although a small amount of dependent crystalline sediment is observed. The proximal urethra and vesicoureteral junction appear normal. There are no calculi and no evidence of inflammatory or neoplastic changes.

The left kidney is normal in shape and size, measuring 4.70 × 2.80 cm, with a cortical thickness of 0.40 cm in the sagittal plane. The cortex is isoechoic compared to the liver parenchyma. A 2.99 × 3.41 mm cortical cyst is present. The right kidney is normal in shape and size, measuring 4.62 × 2.54 cm, with a cortical thickness of 0.48 cm in the sagittal plane. The cortex is isoechoic compared to the liver parenchyma. A 1.59 × 1.71 cm cyst is present at the cranial pole. The corticomedullary ratio and corticomedullary definition are preserved. There is no evidence of pyelectasia or hydronephrosis, although early mineral deposition or crystal formation within the collecting system is visualized.

INTERPRETED BY

Dr. Alicia Angosto
Guerrero

Adrenal Glands

- The left adrenal gland measures 0.41 cm at the cranial pole and 0.87 cm at the caudal pole.
- The right adrenal gland measures 0.56 cm at the cranial pole and 0.53 cm at the caudal pole.

IMAGING PERFORMED BY

Dr. Stranzl

Spleen

HOSPITAL NAME

Dakota VC

Splenic thickness is 0.97 cm. The parenchyma demonstrates normal echogenicity and a fine, homogeneous echotexture, with multiple small myelolipomas, the largest measuring 0.32 × 0.58 cm. The splenic capsule is smooth and regular, and splenic vasculature appears normal.

REFERRING VET

Dr. Stranzl

Liver

INVOICE

69062

The liver is subjectively normal in size, with sharp edges and a regular contour. The hepatic parenchyma is uniform and isoechoic compared to the falciform fat, with a normal echotexture. No hepatic lymphadenopathy is observed.

DATE

11/25/25

The gallbladder lumen is normally distended. The wall is thin, and the luminal contents are primarily anechoic. No dilation of the cystic duct or common bile duct is identified.



PATIENT

Baxter Nigro

SPECIES

Canine

BREED

Shih Tzu

SEX

Neutered male

AGE

14 years

WEIGHT

19 lbs

INTERPRETED BY

Dr. Alicia Angosto
Guerrero

IMAGING PERFORMED BY

Dr. Stranzl

HOSPITAL NAME

Dakota VC

REFERRING VET

Dr. Stranzl

INVOICE

69062

DATE

11/25/25

Gastrointestinal

The stomach is empty and folded, with a mural thickness of 3.49 mm and preserved wall layering. The pylorus measures 4.68 mm. The duodenum measures 2.89 mm, and the jejunum 3.64 mm, both with normal wall layering. No signs of obstruction, ileus, or foreign material are identified. The transverse colon measures 1.44 mm with very soft fecal content. The descending colon measures 1.41 mm with a small amount of formed feces.

Pancreas

The pancreas measures 0.75 cm. Pancreatic parenchyma is isoechoic to the adjacent omental fat, with no signs of active inflammation or neoplastic disease.

Peritoneal Cavity

No abdominal effusion or peritonitis is observed. Cranial mesenteric lymph nodes are not visualized, but the surrounding regions appear unremarkable. The iliac trifurcation is normal.

ULTRASONOGRAPHIC FINDINGS

PRIMARY FINDINGS

- No abdominal metastases identified.
- The left adrenal gland shows asymmetric enlargement of the caudal pole (0.87 cm),
- Bilateral renal cortical cysts, benign in appearance.

SECONDARY FINDINGS

- Mild mineral sediment in renal pelvis, possibly early mineralization or increased excretion.
- Splenic myelolipomas, incidental.

INTERPRETATION OF THE FINDINGS & FURTHER RECOMMENDATIONS

Both kidneys contain cysts, which, despite the size of the right one, appear benign and incidental. There is no pyelectasia or hydronephrosis, though the renal pelvis and proximal collecting systems contain mild dependent hyperechoic mineral sediment, which may represent early nephrolithiasis or increased mineral excretion.

The left adrenal gland shows mild caudal pole enlargement with preserved shape and echogenicity. In the absence of clinical or laboratory evidence of hyperadrenocorticism, this change is most consistent with non-functional, age-related adrenal hyperplasia.

The spleen displays normal echotexture with several small, well-margined myelolipomas—an expected incidental finding in geriatric dogs.

Overall, no ultrasonographic evidence of abdominal metastasis is detected. The renal cysts, splenic myelolipomas, and biliary sludge are incidental age-related findings.



PATIENT

Baxter Nigro

SPECIES

Canine

BREED

Shih Tzu

SEX

Neutered male

AGE

14 years

WEIGHT

19 lbs

INTERPRETED BY

Dr. Alicia Angosto
Guerrero

IMAGING PERFORMED BY

Dr. Stranzl

HOSPITAL NAME

Dakota VC

REFERRING VET

Dr. Stranzl

INVOICE

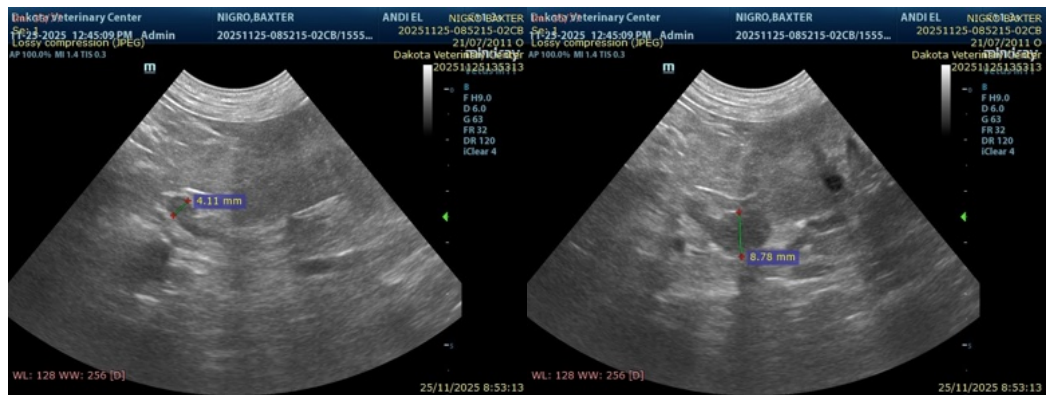
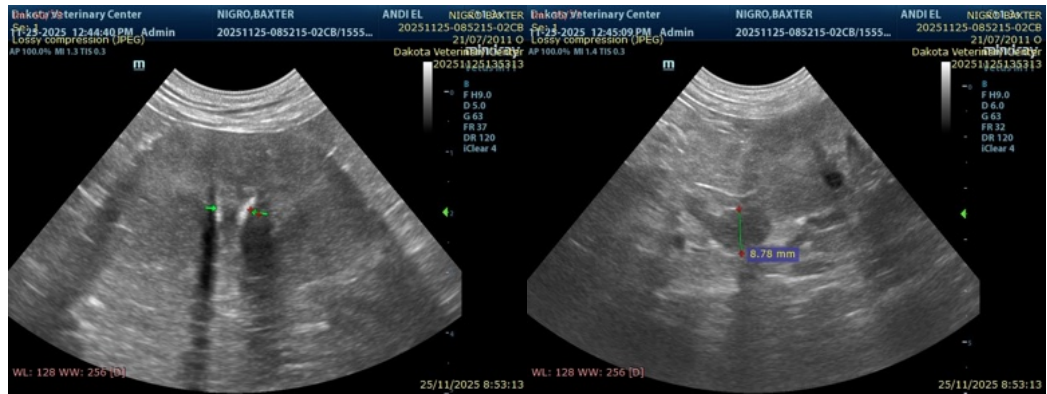
69062

DATE

11/25/25

Recommendations

- Thoracic imaging (3-view radiographs or CT) remains indicated to complete metastatic staging for the ocular mass.
- Consider periodic monitoring of renal findings, particularly the mineral sediment, depending on chemistry/UA results once available.
- Complete renal workup (including USG, UPC, blood pressure, SDMA.)
- If clinical signs compatible with hyperadrenocorticism arise in the future, endocrine testing would be recommended to determine hormonal activity.





PATIENT

Baxter Nigro

SPECIES

Canine

BREED

Shih Tzu

SEX

Neutered male

AGE

14 years

WEIGHT

19 lbs

INTERPRETED BY

Dr. Alicia Angosto Guerrero

IMAGING PERFORMED BY

Dr. Stranzl

HOSPITAL NAME

Dakota VC

REFERRING VET

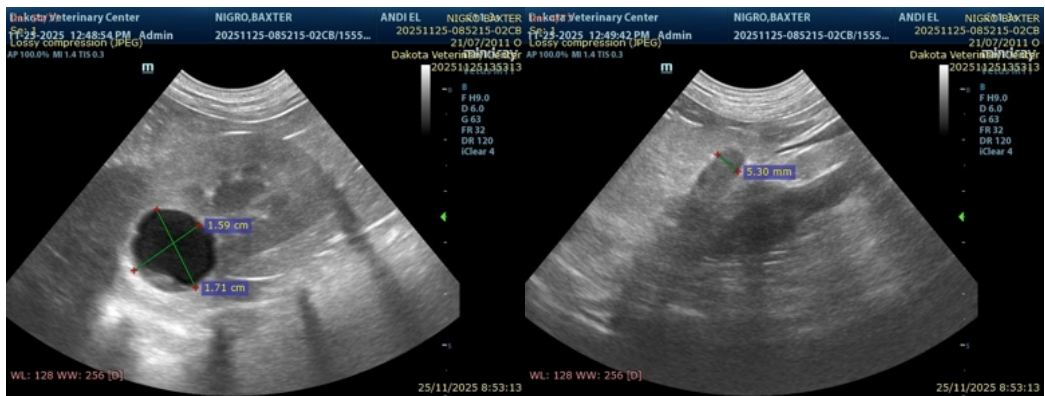
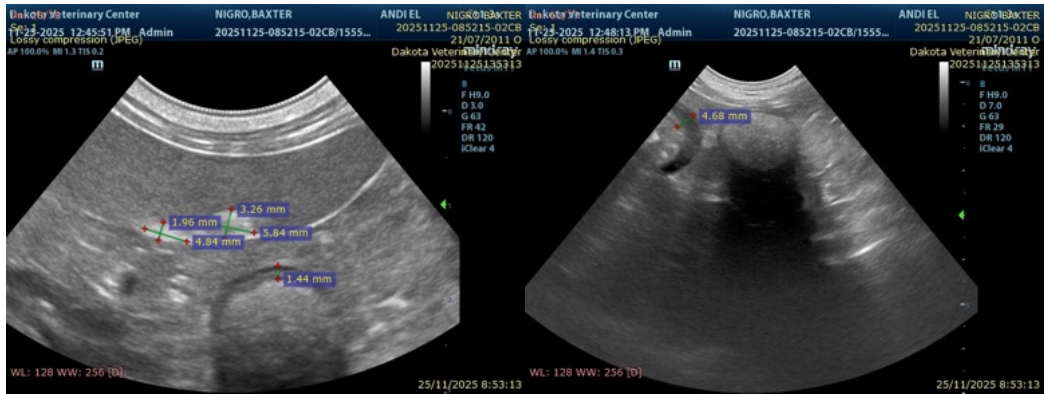
Dr. Stranzl

INVOICE

69062

DATE

11/25/25



The information and recommendations provided are based on the images presented by the referring veterinarian/sonographer. No evaluation can be communicated regarding pathology that was not visible in the image/video clips provided.

Thank you for this referral. If the clinical or image interpretation does not parallel your findings or if I can be of any further assistance please contact me.

Alicia Angosto Guerrero, DMV, PgDip, MSc.

MV Esp Ultrasound in Domestic and Wild Animals

info@SonoPath.com