



PATIENT

Kitty O'Neal

SPECIES

Feline

BREED

Domestic Shorthair

SEX

Spayed female

AGE

10 years

WEIGHT

6.9 lbs

INTERPRETED BY

Dr. Alicia Angosto
Guerrero

IMAGING PERFORMED BY

Dr. Holmes

HOSPITAL NAME

West Newton AC

REFERRING VET

Dr. Holmes

INVOICE

68981

DATE

11/24/25

PRESENTING CLINICAL SIGNS

History: History of weight loss of 1.2 lb since January 2025. Owner noticed changes in defecation over 1 month ago, starting with hard, small stools and transitioning to very soft, sticky stools that are difficult for her to pass. She strains frequently in the litterbox, producing only small amounts of feces that often get stuck to her hind end. About a week prior to the visit on 11/20/2025, she had a two-day episode of lethargy; her appetite was normal, but her water intake was decreased. Since then, her activity and appetite have returned to normal, but her overall water consumption is lower than it used to be. Her diet consists of Fancy Feast wet food and Purina Pro Plan 7+ Sensitive Stomach dry food; the dry food was gradually introduced about a month ago to address the initial hard stools. The patient has a history of a mammary tumor that was surgically removed approximately two years ago. In October, she was treated at another veterinary clinic for a suspected UTI with a B12 injection and a long-acting antibiotic injection.

Abnormal PE/Chem/CBC/UA Results: Right caudal mammary mass. No sign of mets in the chest. 11/20/2025: Total T4 = 3.3 (grey zone, T4 by ED pending), glucose = 233 (repeated today at 109), sodium = 146, ALP = 10, negative fecal, urine protein = 30 mg/ dL, urine glucose = 1000, leukocytes = 4 phf. No response to Provable and metronidazole with diarrhea last night and vomiting. Gave Cerenia, SQ fluids, and Depo injection today after ultrasound.

ULTRASONOGRAPHIC EXAMINATION OF THE ABDOMEN

Urinary System

The bladder lumen is normally distended, and the wall of the urinary bladder appears thin and smooth. The urine is anechoic. Normal appearance of the proximal urethra and vesicoureteral junction. There are no calculi and no evidence of inflammatory or neoplastic changes.

The left kidney is normal in shape and size: 3.66×2.11 cm, and the thickness of the cortex is 0.35 cm in the sagittal plane. The cortex is isoechoic compared to the liver parenchyma. The corticomedullary ratio is normal and the corticomedullary definition is preserved. There is no evidence of pyelectasia, nephroliths, or hydronephrosis. Color Doppler shows a normal pattern.

The right kidney is normal in shape and size: 3.44×1.89 cm, and the thickness of the cortex is 0.30 cm in the sagittal plane. The cortex is isoechoic compared to the liver parenchyma. The corticomedullary ratio is normal and the corticomedullary definition is preserved. There is no evidence of pyelectasia, nephroliths, or hydronephrosis. Color Doppler shows a normal pattern.

Adrenal Glands

Both adrenal glands show normal shape and echogenicity. The left adrenal gland measures 0.30 cm at the cranial pole and 0.34 cm at the caudal pole. The right adrenal gland measures 0.34 cm at the cranial pole and 0.31 cm at the caudal pole.

Spleen

Splenic thickness is 0.79 cm. The parenchyma demonstrates normal echogenicity and fine homogeneous echotexture without focal parenchymal abnormalities. The splenic capsule is smooth and regular. Splenic vasculature appears normal.



PATIENT

Kitty O'Neal

SPECIES

Feline

BREED

Domestic Shorthair

SEX

Spayed female

AGE

10 years

WEIGHT

6.9 lbs

INTERPRETED BY

Dr. Alicia Angosto
Guerrero

IMAGING PERFORMED BY

Dr. Holmes

HOSPITAL NAME

West Newton AC

REFERRING VET

Dr. Holmes

INVOICE

68981

DATE

11/24/25

Liver

The liver is subjectively normal in size, with sharp edges and a regular contour. The liver parenchyma looks uniform and is isoechoic compared to the falciform fat, with a normal echotexture. No hepatic lymphadenopathy is observed.

It appears that there is a duplicated gallbladder with two cystic ducts that then converge (this could be artifactual but does not seem to be). Both lumens are normally distended, the wall is thin, and the contents are primarily anechoic with a small amount of biliary sludge. No evident dilation of the common bile duct is observed.

Gastrointestinal

The stomach is empty and folded, with mural thickness (1.75 mm) and preserved wall layering. The pylorus (2.78 mm). Duodenum: 1.69 mm.

Jejunum: 1.72 mm. Mucosa: 0.75 mm. Submucosa: 0.47 mm. Muscularis propria: 0.29 mm. Ileum: 1.67-1.91 mm. Mucosa: 0.50 mm. Submucosa: 0.96 mm. Muscularis propria: 0.51 mm. Normal wall layering. The ileocecal junction was not visualized. No signs of obstruction, ileus, or foreign material are identified.

Colon: transverse 0.54 cm, scant content. Descending segment completely empty, the wall folded and not assessable.

Pancreas

The right limb (0.41 cm), body (0.59 cm), and left limb (0.53–0.54 cm) were visualized. The parenchyma of the pancreas is slightly hypoechoic to the adjacent omental fat. The diameter of the pancreatic duct is 0.53 mm. No signs of active inflammation or neoplastic disease are evident.

Peritoneal Cavity

No abdominal effusion or peritonitis is observed. Cranial mesenteric lymph nodes and ileocecal lymph nodes are not visualized, but the surrounding regions appear unremarkable. The iliac trifurcation is normal.

ULTRASONOGRAPHIC FINDINGS

PRIMARY FINDINGS

All visualized intestinal segments are within normal thickness ranges, with preserved wall layering. The jejunum shows a muscularis-to-mucosa ratio of approximately 0.39, and the ileum shows a muscularis-to-mucosa ratio of approximately 1.02, both considered acceptable for feline patients.

SECONDARY FINDINGS

Suspected congenital variant (duplicated gallbladder) with minimal biliary sludge.



PATIENT

Kitty O'Neal

SPECIES

Feline

BREED

Domestic Shorthair

SEX

Spayed female

AGE

10 years

WEIGHT

6.9 lbs

INTERPRETED BY

Dr. Alicia Angosto
Guerrero

IMAGING PERFORMED BY

Dr. Holmes

HOSPITAL NAME

West Newton AC

REFERRING VET

Dr. Holmes

INVOICE

68981

DATE

11/24/25

INTERPRETATION OF THE FINDINGS & FURTHER RECOMMENDATIONS

The pancreas is completely and clearly visualized, with all segments demonstrating normal dimensions and only mild parenchymal hypoechogenicity relative to the surrounding omental fat. There is no enlargement, ductal dilation, or peripancreatic inflammatory change, and the pancreatic duct remains within normal limits. Collectively, these features do not support active pancreatitis.

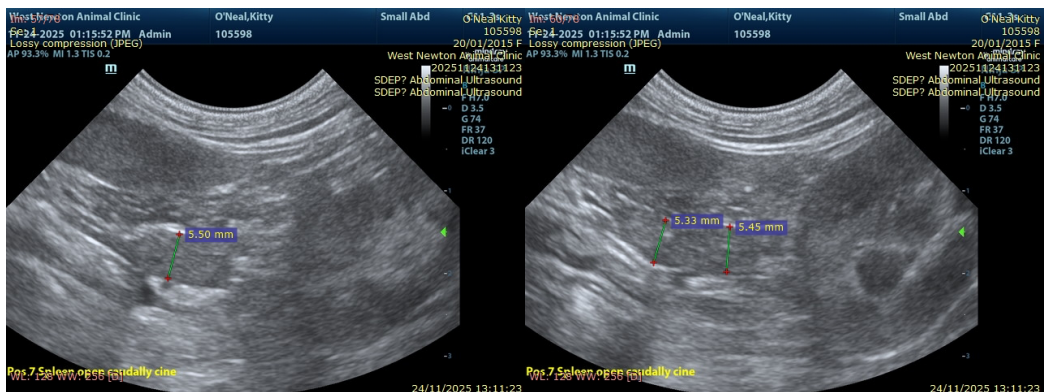
Given the history of weight loss, altered stool consistency, intermittent gastrointestinal signs, and the presence of ultrasonographically normal intestinal wall thickness and layering, a functional or mild inflammatory gastrointestinal disorder remains possible. Normal mural appearance does not exclude early inflammatory bowel disease or dysbiosis. Additionally, the ileocecal junction was not identified, limiting full assessment of this region.

Findings are consistent with a duplicated gallbladder. Although an artifactual appearance cannot be entirely excluded, this is considered less likely given the stable and reproducible visualization across multiple imaging planes. The suspected duplication is most compatible with an incidental congenital variant; however, periodic monitoring is advisable, as gallbladder duplication can occasionally predispose patients to biliary stasis.

The newly identified right caudal mammary mass, together with a prior history of mammary neoplasia, raises concern for either local recurrence or a new primary mammary tumor. No abdominal metastases are visualized on today's examination.

Recommendations

- If gastrointestinal signs become chronic or progressive, perform a GI panel (TLI, folate, cobalamin), as pancreatic function and small intestinal disease can overlap clinically despite normal imaging.
- Consider a spec fPL test if gastrointestinal signs persist or worsen, to help exclude subclinical or chronic pancreatitis not yet visible ultrasonographically.





PATIENT

Kitty O'Neal

SPECIES

Feline

BREED

Domestic Shorthair

SEX

Spayed female

AGE

10 years

WEIGHT

6.9 lbs

INTERPRETED BY

Dr. Alicia Angosto
Guerrero

IMAGING PERFORMED BY

Dr. Holmes

HOSPITAL NAME

West Newton AC

REFERRING VET

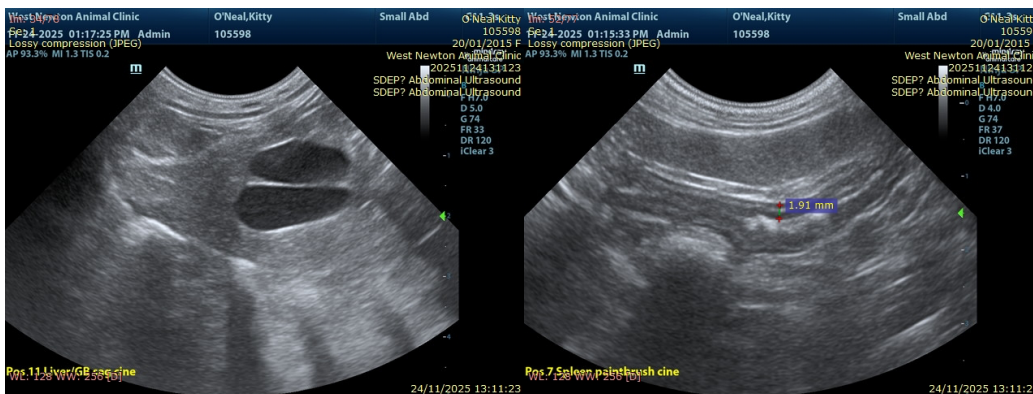
Dr. Holmes

INVOICE

68981

DATE

11/24/25



The information and recommendations provided are based on the images presented by the referring veterinarian/sonographer. No evaluation can be communicated regarding pathology that was not visible in the image/video clips provided.

Thank you for this referral. If the clinical or image interpretation does not parallel your findings or if I can be of any further assistance please contact me.

Alicia Angosto Guerrero, DMV, PgDip, MSc.

MV Esp Ultrasound in Domestic and Wild Animals

info@SonoPath.com