



PATIENT

Mister Dorian
Humenski

SPECIES

Lagomorpha

BREED

Lionhead

SEX

Neutered Male

AGE

6 Years 6 Months

WEIGHT

2.21 kg

INTERPRETED BY

Alicia Angosto
Guerrero, DMV,
PgDip, MSc.

IMAGING PERFORMED BY

Dallas Reynolds, LVT

HOSPITAL NAME

Lone Mountain Animal
Hospital

REFERRING VET

Dr. Lindsay Geiger

INVOICE

71858

DATE

11/15/25

PRESENTING CLINICAL SIGNS

P originally presented for hematuria on 10/29/25. UA results showed blood in urine, no infection. Hematuria resolved as of now, O still concerned and worried about cancer. BW mostly insignificant aside from ALP of 65. O does not feed a diet high in calcium and follows correct husbandry. P is asymptomatic and has normal energy, appetite, feces, etc. Xray report from 10/29 came back with: "mineralized areas in the bladder are most suggestive of poor formed uroliths. Other differentials include dystrophic bladder wall mineralization, fat saponification and prostatic pathology. An abdominal ultrasound examination to assess the ureters, kidneys and urinary bladder are recommended."

Abnormal PE/Chem/CBC/UA Results: ALP 65

ULTRASONOGRAPHIC EXAMINATION OF THE ABDOMEN

Urinary System

The bladder lumen is moderately distended. The wall of the urinary bladder appears thin and smooth. Abundant vesical sludge and mineral sediment, and a concretion of 3.19–3.59 mm, are present (like a calculus in formation). The urethra appears slightly dilated with sediment but no calculus or evident obstruction. There is no evidence of inflammatory or neoplastic changes.

The left kidney has a normal shape and size, measuring 2.73×1.45 cm, with a cortical thickness of 0.22 cm in the sagittal plane.

The right kidney has a normal shape and size, measuring 2.86×1.30 cm, with a cortical thickness of 0.22 cm in the sagittal plane.

The cortical is isoechoic in comparison to the normal liver parenchyma. The cortex-to-medulla ratio is within normal limits, and the corticomedullary differentiation is preserved. The renal sinus appears hyperechoic, as expected in rabbits. There is no evidence of pyelectasis, nephrolithiasis, or hydronephrosis, although there is a slight increase in the excretion of calcium crystals at the level of the collecting system.

Prostate

Prostatic and bulbourethral gland region appears normal, with no abnormalities observed.

Adrenal Glands

The adrenal glands are uniform in size and contour, with uniformly hypoechoic parenchyma. The left adrenal gland measures 0.32 cm at the cranial pole and 0.33 cm at the caudal pole. The right adrenal gland measures 0.24 cm at the cranial pole and 0.24 cm at the caudal pole.

Spleen

Partially observed: 3.14 cm, homogeneous.

Liver

The liver appears subjectively normal in size, structure, and contour. The parenchyma is uniform and hypoechoic compared to the spleen, with coarse echotexture and a highly contrasted image (possibly due to equipment settings). No hepatic lymphadenopathy is observed.



PATIENT

Mister Dorian
Humenski

SPECIES

Lagomorpha

BREED

Lionhead

SEX

Neutered Male

AGE

6 Years 6 Months

WEIGHT

2.21 kg

INTERPRETED BY

Alicia Angosto
Guerrero, DMV,
PgDip, MSc.

IMAGING PERFORMED BY

Dallas Reynolds, LVT

HOSPITAL NAME

Lone Mountain Animal
Hospital

REFERRING VET

Dr. Lindsay Geiger

INVOICE

71858

DATE

11/15/25

The gallbladder lumen is moderately distended. The wall is thin, and the luminal content appears primarily anechoic. The common bile duct is mildly dilated in its proximal part (2.51 cm), then appears normal.

Gastrointestinal

The stomach is distended with a food pattern. It exhibits a normally thickened wall (body: 0.09 cm, pylorus: 0.28 cm) and a normal layering pattern. The small intestine has a normal thickness (duodenum 0.08 cm, jejunum 0.06 cm) and presents intact wall layering. The lumen of the small intestine is empty, with no signs of ileus, tympanism, or obstruction. The cecum shows a very thin normal wall (0.05 cm) and completely normal contents. Appendix 1.91 mm, normal. The sacculus rotundus could not be visualized. The distal colon has normal wall thickness (0.53 mm) with soft material.

Pancreas

Not visualized due to artifacts generated by the digestive system.

Free Abdomen

The evaluation of the peritoneal cavity reveals no abdominal effusion, peritonitis, or lymphadenomegaly.

PRIMARY FINDINGS

- Abundant bladder sludge, mineral sediment, and a 3.19–3.59 mm concretion (not sure if one or two because there is different videos)
- Slightly dilated urethra with sediment, without evident obstruction.
- Mild increase in calcium crystal excretion in the renal collecting system.

INTERPRETATION OF THE FINDINGS & FURTHER RECOMMENDATIONS

The presence of abundant vesical sludge, mineral sediment, and a 3.19–3.59 mm mineral concretion(s) is consistent with incipient urolith formation, a common condition in rabbits even when husbandry and diet are appropriate.

The ultrasonographic findings, combined with the patient's history, laboratory data, and current clinical status, strongly support a diagnosis of bladder sludge syndrome with early mineral concretion (incipient urolith) rather than neoplastic disease or systemic pathology.

The ultrasonographic appearance does not support the suspicion of bladder wall mineralization, fat saponification, or prostatic disease mentioned as differentials on radiographs.

Renal findings indicate normal renal function with physiologic crystalline excretion, not renal pathology.

The mild proximal dilation of the common bile duct is likely incidental in the absence of clinical signs, hepatic biochemical abnormalities, or structural liver changes.



PATIENT

Mister Dorian Humenski

SPECIES

Lagomorpha

BREED

Lionhead

SEX

Neutered Male

AGE

6 Years 6 Months

WEIGHT

2.21 kg

INTERPRETED BY

Alicia Angosto Guerrero, DMV, PgDip, MSc.

IMAGING PERFORMED BY

Dallas Reynolds, LVT

HOSPITAL NAME

Lone Mountain Animal Hospital

REFERRING VET

Dr. Lindsay Geiger

INVOICE

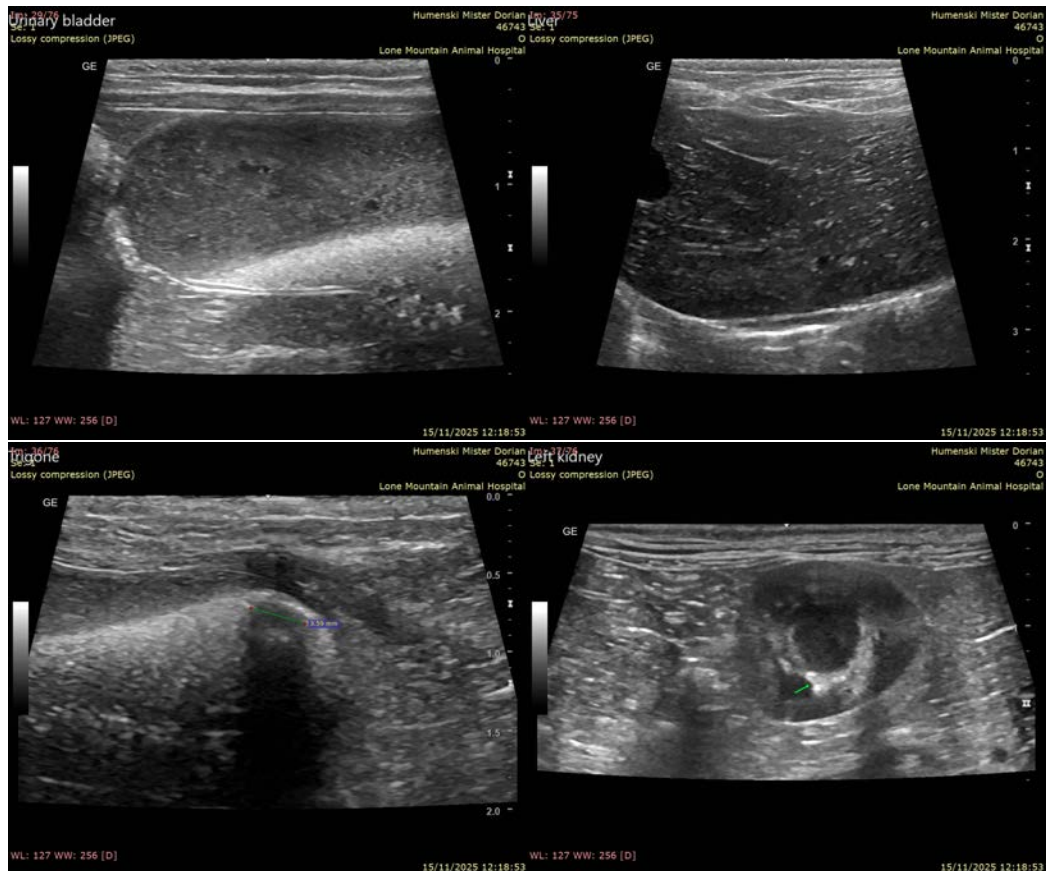
71858

DATE

11/15/25

Recommendations:

- Urinalysis to confirm that the bladder sediment and concretion are composed of calcium carbonate (which is by far the most common mineral type in rabbits and aligns with the ultrasound findings). This would also help exclude or confirm rarer crystal types (struvite, calcium oxalate) and identify any occult infection—although infection is unlikely given the current normal bladder wall appearance and lack of symptoms.
- Consider a urine culture only if clinical signs of a UTI develop (currently absent).
- Perform again a detailed dietary review, from the specific hay being fed (not alfalfa) to every component of the rabbit's intake.
- Review the diet and increase hydration. Encourage mobility and reduce stress, as low water intake, a sedentary lifestyle, and stress are recognized risk factors for sludge accumulation and urolith formation.





PATIENT

Mister Dorian
Humenski

SPECIES

Lagomorpha

BREED

Lionhead

SEX

Neutered Male

AGE

6 Years 6 Months

WEIGHT

2.21 kg

INTERPRETED BY

Alicia Angosto
Guerrero, DMV,
PgDip, MSc.

IMAGING PERFORMED BY

Dallas Reynolds, LVT

HOSPITAL NAME

Lone Mountain Animal
Hospital

REFERRING VET

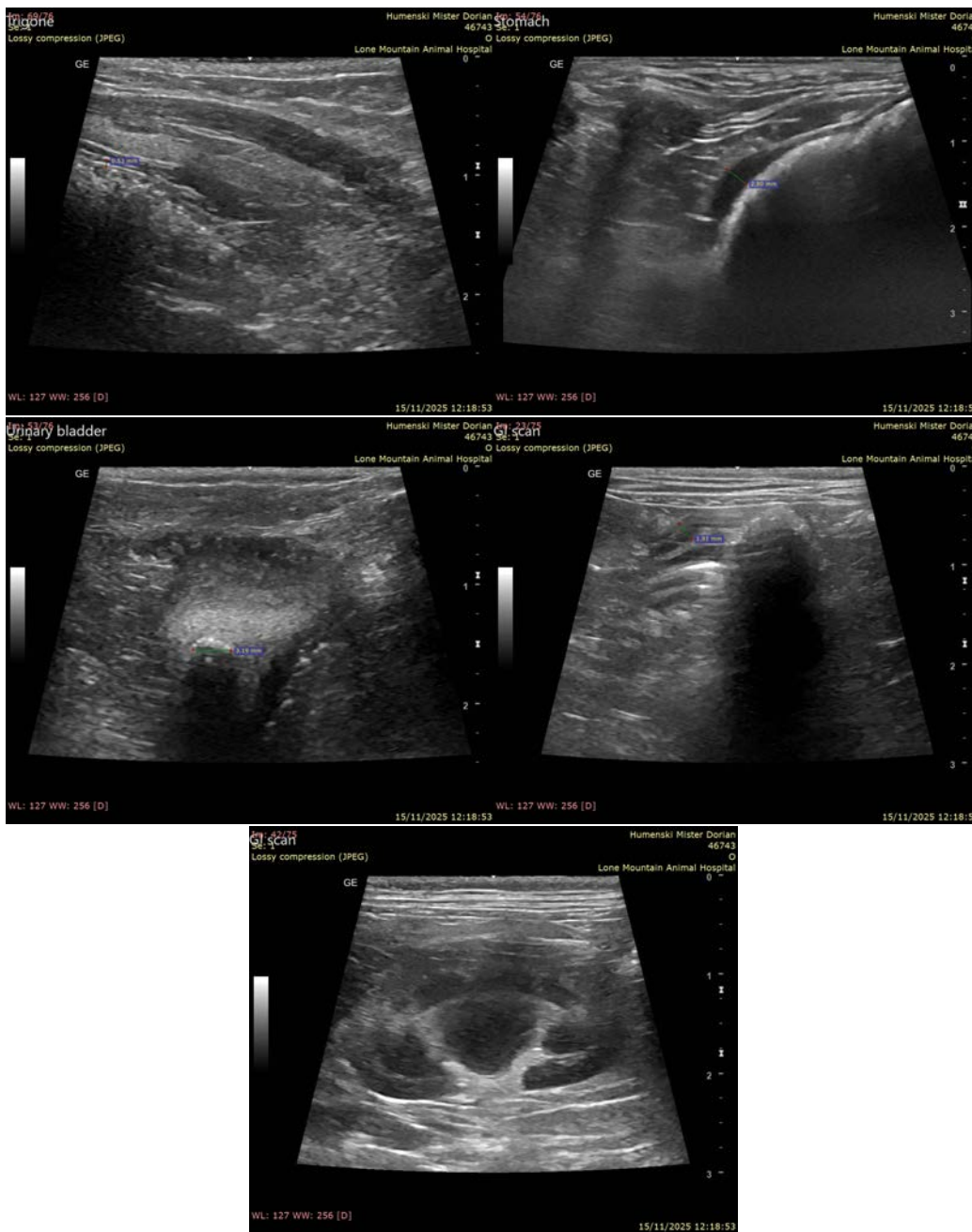
Dr. Lindsay Geiger

INVOICE

71858

DATE

11/15/25



The information and recommendations provided are based on the images presented by the referring veterinarian/sonographer. No evaluation can be communicated regarding pathology that was not visible in the image/video clips provided.

Thank you for this referral. If the clinical or image interpretation does not parallel your findings or if I can be of any further assistance please contact me.

Alicia Angosto Guerrero, DMV, PgDip, MSc. info@SonoPath.com