



PATIENT

Pippin Mysak

SPECIES

Feline

BREED

Domestic Shorthair

SEX

Neutered male

AGE

6 years

WEIGHT

4.1 kg

INTERPRETED BY

Dr. Alicia Angosto
Guerrero

IMAGING PERFORMED BY

Danielle RVT

HOSPITAL NAME

Orchard VC

REFERRING VET

Dr. Antonopoulos

INVOICE

69932

DATE

1/7/26

PRESENTING CLINICAL SIGNS

History: Vomiting and diarrhea for the last few months Vomiting (GI disease-IBD, food intolerance/sensitivity, chronic enteritis, pancreatitis other vs metabolic disease although less likely given recent BW findings) - has changed to hypo food

ULTRASONOGRAPHIC EXAMINATION OF THE ABDOMEN

Urinary System

The urinary bladder lumen is normally distended, and the urinary bladder wall appears thin and smooth. The urine is anechoic. The bladder neck and proximal urethra appear normal. No uroliths are identified, and there is no evidence of inflammatory or neoplastic changes.

The left kidney is normal in shape and size, measuring 3.50×1.78 cm, with a cortical thickness of 0.31 cm in the sagittal plane. The right kidney is normal in shape and size, measuring 3.81 2.18 cm, with a cortical thickness of 0.39 cm in the sagittal plane. Bilaterally, the renal cortex is mildly increased in echogenicity, resulting in increased corticomedullary distinction. There is no evidence of pyelectasia, nephrolithiasis, or hydronephrosis. Color Doppler demonstrates a normal perfusion pattern.

Adrenal Glands

Both adrenal glands show normal shape and echogenicity. The left adrenal gland measures 0.19 cm at the cranial pole and 0.23 cm at the caudal pole. The right adrenal gland measures 0.23 cm at the cranial pole and 0.25 cm at the caudal pole.

Spleen

Splenic thickness measures 0.78 cm. The splenic parenchyma demonstrates normal echogenicity and a fine, homogeneous echotexture without focal parenchymal abnormalities. The splenic capsule is smooth and regular.

Liver

The liver is subjectively normal in size, with sharp margins and a regular contour. The hepatic parenchyma is homogeneous and isoechoic relative to the falciform fat, with a normal echotexture. No hepatic lymphadenopathy is observed.

The gallbladder lumen is moderately distended. The gallbladder wall is thin, and the contents are predominantly anechoic. The common bile duct measures 2.26–2.79 mm.

Gastrointestinal

The stomach is empty and folded, with a small amount of intraluminal fluid. Gastric wall thickness measures 1.51 mm, with preserved wall layering. The pyloric wall measures 2.62 mm.



PATIENT

Pippin Mysak

SPECIES

Feline

BREED

Domestic Shorthair

SEX

Neutered male

AGE

6 years

WEIGHT

4.1 kg

INTERPRETED BY

Dr. Alicia Angosto
Guerrero

IMAGING PERFORMED BY

Danielle RVT

HOSPITAL NAME

Orchard VC

REFERRING VET

Dr. Antonopoulos

INVOICE

69932

DATE

1/7/26

Duodenal wall thickness measures 1.75 mm. The major duodenal papilla measures 1.96×2.62 mm. Jejunal wall thickness measures 2.21 mm, with the following layer measurements: mucosa 1.32 mm, submucosa 0.59 mm, and muscularis propria 0.54 mm. Ileal wall thickness measures 1.81 mm, with the following layer measurements: mucosa 0.56 mm, submucosa 0.75 mm, and muscularis propria 0.30 mm. Wall layering is preserved. The ileocecal junction measures 2.31 mm, with muscularis thickness of 0.68 mm. No sonographic signs of obstruction, ileus, or foreign material are identified.

The colonic wall measures 0.69 mm in the ascending colon (largely empty), 0.97 mm in the transverse colon (semiliquid contents), and 1.08 mm in the descending colon, which contains a small amount of soft fecal material.

Pancreas

The right limb, body, and left limb of the pancreas appear normal, measuring up to 4.44 mm in thickness. The pancreatic parenchyma is isoechoic relative to the adjacent omental fat. The pancreatic duct measures 0.42 mm in diameter. No sonographic evidence of active inflammation or neoplastic disease is identified.

Peritoneal Cavity

No abdominal effusion or sonographic signs of peritonitis are observed. The ileocecal lymph nodes measure 1.93–2.56 mm in thickness and maintain normal shape and echogenicity. Cranial mesenteric lymph nodes are unremarkable. The iliac trifurcation appears normal.

ULTRASONOGRAPHIC FINDINGS

- Mild diffuse small intestinal wall thickening (duodenum, jejunum, ileum) with preserved layering.
- Mild muscularis hypertrophy at the ileocecal junction.
- Mild enlargement of ileocecal lymph nodes, with preserved morphology, consistent with reactive change.
- Small volume of gastric fluid, without associated structural abnormality.

SECONDARY FINDINGS

- Mild bilateral renal cortical hyperechogenicity, nonspecific and likely incidental.

INTERPRETATION OF THE FINDINGS & FURTHER RECOMMENDATIONS

The abdominal ultrasound examination demonstrates normal duodenal wall thickness with preserved layering. Jejunal wall thickness is at the upper limits of published reference ranges, with a relative prominence of the muscularis layer. At the ileocecal junction, muscularis thickness is mildly increased while overall wall stratification remains preserved. This distribution and pattern of findings are most consistent with a mild chronic inflammatory enteropathy.



PATIENT

Pippin Mysak

SPECIES

Feline

BREED

Domestic Shorthair

SEX

Neutered male

AGE

6 years

WEIGHT

4.1 kg

INTERPRETED BY

Dr. Alicia Angosto
Guerrero

IMAGING PERFORMED BY

Danielle RVT

HOSPITAL NAME

Orchard VC

REFERRING VET

Dr. Antonopoulos

INVOICE

69932

DATE

1/7/26

Ileocecal lymph nodes are mildly enlarged but maintain normal shape and echogenicity, consistent with reactive lymphadenopathy.

The stomach contains a small amount of fluid but is otherwise unremarkable.

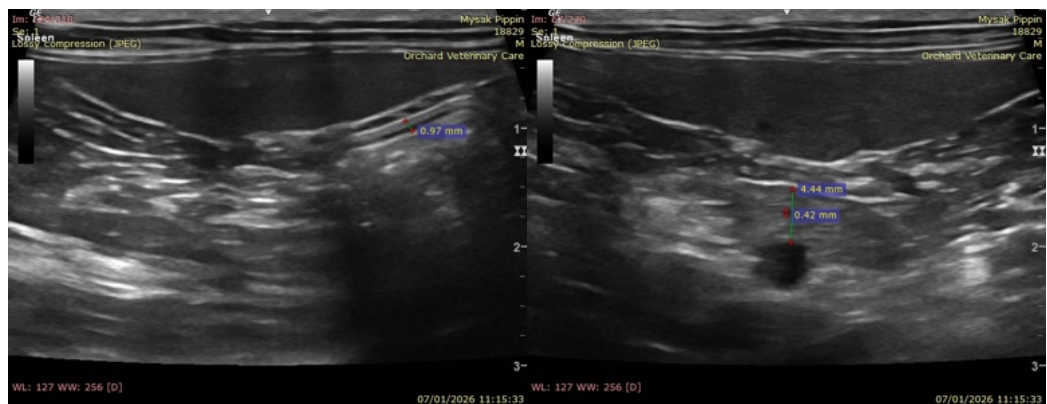
The pancreas appears normal in size and echogenicity, with no sonographic evidence of pancreatitis or pancreatic neoplasia.

Mild bilateral renal cortical hyperechogenicity is a common, nonspecific finding in cats and may be incidental in the absence of supportive clinical or biochemical abnormalities.

Overall, the imaging findings support mild chronic inflammatory gastrointestinal disease. Although early small-cell intestinal lymphoma cannot be entirely excluded based on ultrasonographic findings alone due to overlap in imaging appearance, it is not considered the primary diagnosis.

Recommendations

- Clinical correlation with chronic enteropathy workup is recommended, including dietary response, gastrointestinal panel (cobalamin, folate, TLI, fPLI), and response to medical management.
- Follow-up abdominal ultrasonography may be considered to monitor intestinal wall thickness and lymph node size if clinically indicated.
- Correlation with renal function parameters is recommended to assess the clinical significance of mild renal cortical echogenicity.
- Ongoing dietary management and medical therapy as directed by the primary clinician.
- Endoscopic or full-thickness intestinal biopsies may be considered if clinical signs persist or worsen, or if new ultrasonographic abnormalities develop, in order to obtain a definitive diagnosis.





PATIENT

Pippin Mysak

SPECIES

Feline

BREED

Domestic Shorthair

SEX

Neutered male

AGE

6 years

WEIGHT

4.1 kg

INTERPRETED BY

Dr. Alicia Angosto Guerrero

IMAGING PERFORMED BY

Danielle RVT

HOSPITAL NAME

Orchard VC

REFERRING VET

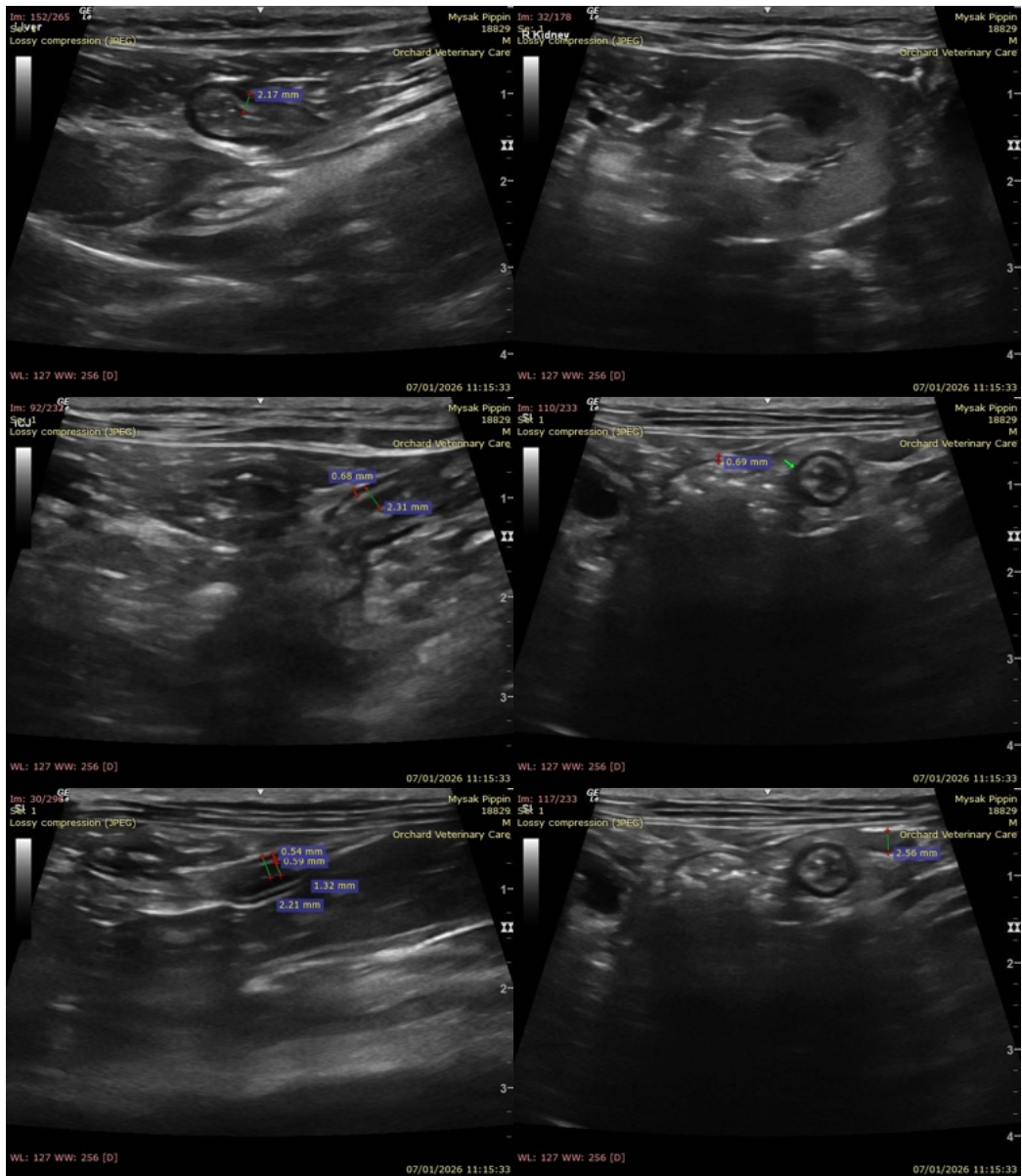
Dr. Antonopoulos

INVOICE

69932

DATE

1/7/26



The information and recommendations provided are based on the images presented by the referring veterinarian/sonographer. No evaluation can be communicated regarding pathology that was not visible in the image/video clips provided.

Thank you for this referral. If the clinical or image interpretation does not parallel your findings or if I can be of any further assistance please contact me.

Alicia Angosto Guerrero, DMV, PgDip, MSc.

MV Esp Ultrasound in Domestic and Wild Animals

info@SonoPath.com