



PATIENT

Peter Luongo

SPECIES

Feline

BREED

Tabby

SEX

Neutered Male

AGE

10 years 9 months

WEIGHT

18.06 lbs

INTERPRETED BY

Alicia Angosto
Guerrero, DMV,
PgDip, MSc.

IMAGING PERFORMED BY

Dr. Adrienne Hou

HOSPITAL NAME

Marina Village
Veterinary &
Integrative Care

REFERRING VET

Dr. Adrienne Hou

INVOICE

11216

DATE

1/30/2026

PRESENTING CLINICAL SIGNS

- vomiting- every other day for months, intermittently for years. Improved after switching to canned-only diet a few years ago. Currently on hydrolyzed protein diet. No weight loss.

Abnormal PE/Chem/CBC/UA Results: CBC/chem/urinalysis in November 2025: mild elevation in triglyceride (non-fasted sample), blood glucose=61, remainder unremarkable. TLI, Cobalamin levels are pending.

ULTRASONOGRAPHIC EXAMINATION OF THE ABDOMEN

Urinary System

The urinary bladder is normally distended. The bladder wall is thin and smooth. Urine is anechoic. The bladder neck and proximal urethra appear normal. No uroliths or ultrasonographic evidence of inflammatory or neoplastic disease are identified.

The left kidney is normal in shape and size, measuring 4.20×2.26 cm, with a cortical thickness of 0.33 cm in the sagittal plane. The renal cortex appears isoechoic relative to the liver parenchyma, although overall image contrast is somewhat increased. The corticomedullary ratio and corticomedullary distinction are preserved. No pyelectasia, nephrolithiasis, or hydronephrosis is observed. Color Doppler demonstrates a normal vascular pattern.

The right kidney is normal in shape and size, measuring 4.30×1.96 cm, with a cortical thickness of 0.35 cm in the sagittal plane. Cortical echogenicity relative to the liver parenchyma is considered within normal limits. The corticomedullary ratio and corticomedullary distinction are preserved. No pyelectasia, nephrolithiasis, or hydronephrosis is observed. Color Doppler demonstrates a normal vascular pattern.

Adrenal Glands

The left adrenal gland is not clearly visualized. The right adrenal gland measures 0.33 cm.

Spleen

Splenic thickness is 0.94 cm. The splenic parenchyma demonstrates normal echogenicity and a fine, homogeneous echotexture without focal abnormalities. The splenic capsule is smooth and regular.

Liver

The liver is subjectively normal in size, with sharp margins and a regular contour. The hepatic parenchyma is homogeneous and isoechoic relative to the falciform fat, with normal echotexture. No hepatic lymphadenopathy is observed.

The gallbladder is normally distended. The wall is thin. The lumen is primarily anechoic. No dilation of the cystic duct or common bile duct is identified.

Gastrointestinal

The stomach is empty and folded. Gastric wall thickness measures 1.83 mm, with preserved wall layering. The pyloric wall measures 2.95 mm and contains a small amount of luminal fluid.



PATIENT

Peter Luongo

SPECIES

Feline

BREED

Tabby

SEX

Neutered Male

AGE

10 years 9 months

WEIGHT

18.06 lbs

INTERPRETED BY

Alicia Angosto
Guerrero, DMV,
PgDip, MSc.

IMAGING PERFORMED BY

Dr. Adrienne Hou

HOSPITAL NAME

Marina Village
Veterinary &
Integrative Care

REFERRING VET

Dr. Adrienne Hou

INVOICE

11216

DATE

1/30/2026

The duodenum measures 2.18 mm in wall thickness.

The jejunum measures 3.04 mm, with mural layers as follows:

- Mucosa: 1.84 mm
- Submucosa: 0.45 mm
- Muscularis propria: 0.76 mm

The ileum measures 3.20 mm, with mural layers as follows:

- Mucosa: 1.08 mm
- Submucosa: 1.08 mm
- Muscularis propria: 1.88 mm

Overall wall layering is preserved. The ileocecal junction is not visualized. No focal masses, obstructive changes, ileus, or foreign material are identified.

The colon wall measures 0.54 mm and contains formed fecal material within the descending colon.

Pancreas

The pancreas measures 6.34 mm in thickness. The pancreatic parenchyma is isoechoic relative to adjacent omental fat. The pancreatic duct measures 0.84 mm in diameter. No hyperechogenicity of the peripancreatic fat or other ultrasonographic signs of active pancreatitis are identified.

Free Abdomen

No abdominal effusion or ultrasonographic evidence of peritonitis is observed. Cranial mesenteric and ileocecal lymph nodes are not visualized, and the surrounding regions appear unremarkable. The iliac trifurcation appears normal.

PRIMARY FINDINGS

- Segmental thickening of the small intestine, with disproportionate muscularis propria thickening, most pronounced in the ileum.
- Mild prominence of the pancreas with mild pancreatic duct dilation.

INTERPRETATION OF THE FINDINGS & FURTHER RECOMMENDATIONS

This abdominal ultrasound demonstrates segmental thickening of the small intestinal wall, most notably affecting the muscularis propria, particularly within the ileum, where the muscular layer is disproportionately thickened relative to the mucosa and submucosa. Despite this, overall wall layering is preserved, and no discrete mass lesions or associated abdominal lymphadenopathy are identified.

This pattern is not specific but is most commonly associated with chronic enteropathy, including inflammatory bowel disease and small cell (low-grade) intestinal lymphoma. Given the long-standing history of chronic vomiting, partial dietary responsiveness, and absence of weight loss, an inflammatory enteropathy remains a strong consideration. However, the degree and distribution of



PATIENT

Peter Luongo

SPECIES

Feline

BREED

Tabby

SEX

Neutered Male

AGE

10 years 9 months

WEIGHT

18.06 lbs

INTERPRETED BY

Alicia Angosto
Guerrero, DMV,
PgDip, MSc.

IMAGING PERFORMED BY

Dr. Adrienne Hou

HOSPITAL NAME

Marina Village
Veterinary &
Integrative Care

REFERRING VET

Dr. Adrienne Hou

INVOICE

11216

DATE

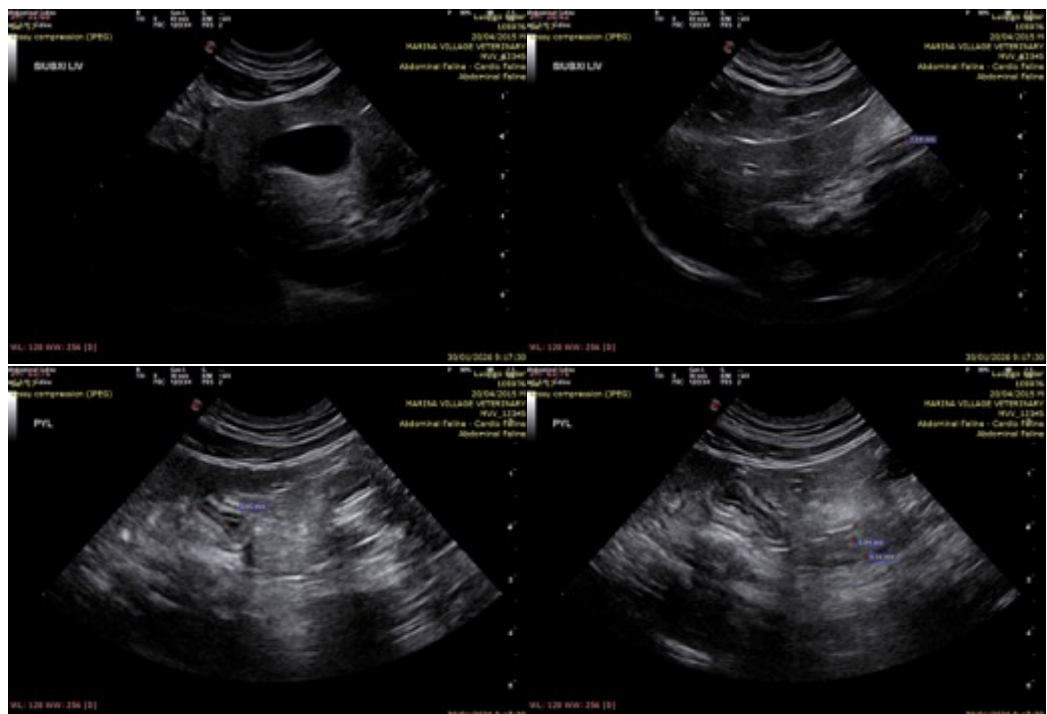
1/30/2026

muscularis thickening—especially within the ileum—introduce overlap with early or indolent small cell lymphoma, which cannot be reliably excluded based on ultrasonography alone.

The pancreas appears mildly prominent with a mildly dilated pancreatic duct, without peripancreatic fat changes or other features of active pancreatitis. This finding may be age-related or reflect chronic or low-grade pancreatic change and should be interpreted cautiously in the absence of supportive clinical or laboratory evidence.

Recommendations

- Correlate ultrasonographic findings with pending TLI and cobalamin results, as hypocobalaminemia may support clinically significant chronic enteropathy.
- Monitor pancreatic values (Spec fPL), recognizing that mild pancreatic duct dilation may be incidental.
- Given the chronicity of clinical signs and muscularis-predominant thickening, further characterization of intestinal disease is recommended, with consideration of gastrointestinal panel results, response to medical therapy, and overall clinical trajectory.
- If clinical signs persist or progress despite appropriate medical management, intestinal biopsy should be considered to differentiate inflammatory bowel disease from small cell lymphoma.





PATIENT

Peter Luongo

SPECIES

Feline

BREED

Tabby

SEX

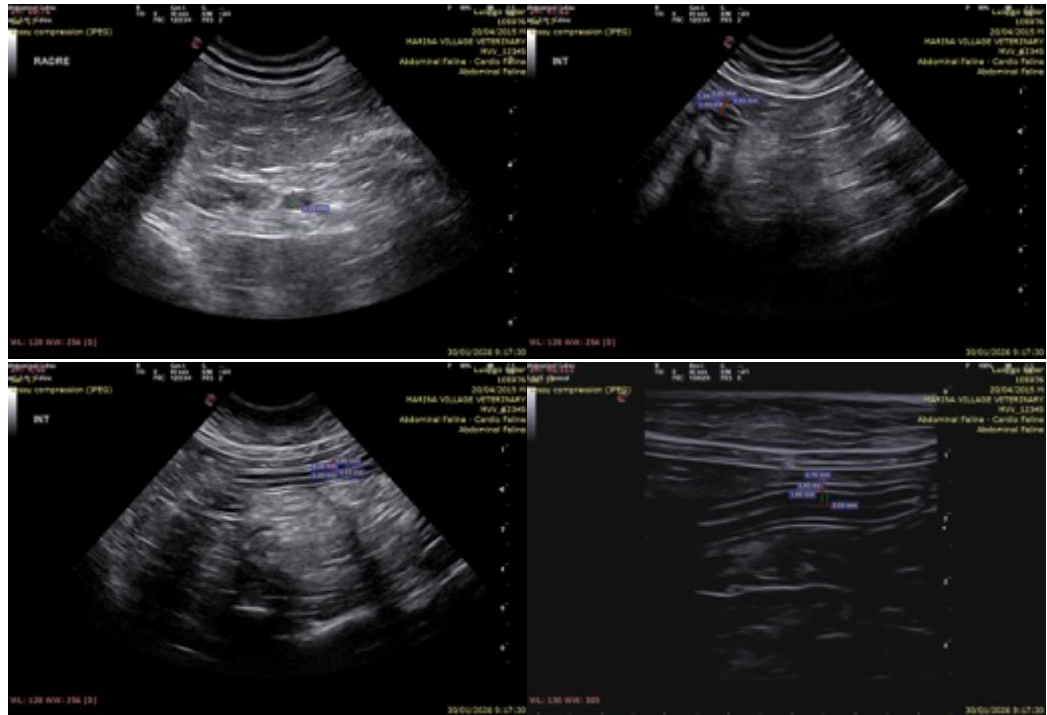
Neutered Male

AGE

10 years 9 months

WEIGHT

18.06 lbs



INTERPRETED BY

Alicia Angosto
Guerrero, DMV,
PgDip, MSc.

IMAGING PERFORMED BY

Dr. Adrienne Hou

HOSPITAL NAME

Marina Village
Veterinary &
Integrative Care

REFERRING VET

Dr. Adrienne Hou

INVOICE

11216

DATE

1/30/2026

The information and recommendations provided are based on the images presented by the referring veterinarian/sonographer. No evaluation can be communicated regarding pathology that was not visible in the image/video clips provided.

Thank you for this referral. If the clinical or image interpretation does not parallel your findings or if I can be of any further assistance please contact me.

Alicia Angosto Guerrero, DMV, PgDip, MSc.

info@SonoPath.com