



## PATIENT

Remi Kaufmann

## SPECIES

Feline

## BREED

DSH

## SEX

Neutered Male

## AGE

14 Years

## WEIGHT

10 lbs

## INTERPRETED BY

Alicia Angosto  
Guerrero, DMV,  
PgDip, MSc.

## IMAGING PERFORMED BY

Dr. Beth Coe

## HOSPITAL NAME

Riverside Animal Clinic

## REFERRING VET

Dr. Beth Coe

## INVOICE

72417

## DATE

1/23/26

## PRESENTING CLINICAL SIGNS

Weight loss noted in 6/2025. Bloodwork then all WRI, including TT4. Fecal exam negative. In 1/2026, owner felt still losing weight, and recently decreased appetite. Indoor only. Offering variety of canned flavors and dry kibble. Began vomiting bile/phlegm daily reported 1/14/26. Not as active/vocal per owner. Patient's littermate was euthanized in 2022 with presumed lymphoma.

Abnormal PE/Chem/CBC/UA Results: PE 1/9/26: Severe periodontal disease, neck lesions noted 300 arcade. Thin BCS 3/9. Otherwise NSF. Weight: 16.5lbs 6/7/2024; 12.7lbs 6/2/2025; 10.06lbs 1/9/2026. CBC: mild neutrophilia (13K). Rest WRI Chem: SDMA 21, BUN 38, Crea 1.7. No urinalysis done. Hypochloremia (69). Rest WRI. TT4: WRI

## ULTRASONOGRAPHIC EXAMINATION OF THE ABDOMEN

### *Urinary System*

The urinary bladder lumen is normally distended. The bladder wall appears thin and smooth. The urine is anechoic. The bladder neck and proximal urethra have a normal ultrasonographic appearance. No uroliths are identified, and there is no ultrasonographic evidence of inflammatory or neoplastic changes.

The left kidney is normal in shape and size, measuring 3.73×1.99 cm. Cortical thickness measures 0.28 cm in the sagittal plane.

The right kidney is normal in shape and size, measuring 3.80×2.24 cm. Cortical thickness measures 0.33 cm in the sagittal plane.

The renal cortex is hyperechoic relative to the liver parenchyma. The corticomedullary ratio is within normal limits, and corticomedullary definition is preserved. A medullary rim sign is present. There is no evidence of pyelectasia, nephrolithiasis, or hydronephrosis. Color Doppler evaluation demonstrates a normal vascular pattern.

### *Adrenal Glands*

Both adrenal glands have normal shape and echogenicity. The left adrenal gland measures 0.28 cm at the cranial pole and 0.29 cm at the caudal pole. The right adrenal gland measures 0.33 cm at both the cranial and caudal poles.

### *Spleen*

Splenic thickness measures 0.82 cm. The splenic parenchyma demonstrates normal echogenicity with a fine, homogeneous echotexture and no focal parenchymal abnormalities. The splenic capsule is smooth and regular. Splenic vasculature appears normal.

### *Liver*

The liver is subjectively normal in size, with sharp margins and a smooth, regular contour. The hepatic parenchyma is uniform and isoechoic relative to the falciform fat, with a normal echotexture. No hepatic lymphadenopathy is identified.

The gallbladder lumen is normally distended. The gallbladder wall is thin. The contents are predominantly anechoic. The common bile duct measures 1.88 mm proximally and 1.44 mm distally.



## PATIENT

Remi Kaufmann

## SPECIES

Feline

## BREED

DSH

## SEX

Neutered Male

## AGE

14 Years

## WEIGHT

10 lbs

## INTERPRETED BY

Alicia Angosto  
Guerrero, DMV,  
PgDip, MSc.

## IMAGING PERFORMED BY

Dr. Beth Coe

## HOSPITAL NAME

Riverside Animal Clinic

## REFERRING VET

Dr. Beth Coe

## INVOICE

72417

## DATE

1/23/26

## *Gastrointestinal*

The stomach is empty and folded, with preserved wall layering and a mural thickness of 1.31 mm. The pylorus measures 3.58 mm and contains a small amount of luminal fluid.

Duodenum: mural thickness 1.90 mm.

Jejunum: mural thickness 2.30 mm; mucosa 1.29 mm; submucosa 0.51 mm; muscularis propria 0.51 mm.  
Ileum: mural thickness 2.75 mm; mucosa 0.68 mm; submucosa 0.84 mm; muscularis propria 0.96 mm, with preserved wall layering.

The ileocecal junction is not visualized. No ultrasonographic evidence of gastrointestinal obstruction, ileus, or foreign material is identified.

Colon: the transverse colon wall measures 0.65 mm and contains formed fecal material with mild distal acoustic shadowing. An additional colonic segment measures 0.99 mm, with soft fecal material in the lumen.

## *Pancreas*

The evaluated portions of the pancreas do not show ultrasonographic evidence of overt inflammation.

## *Free Abdomen*

No abdominal effusion or sonographic evidence of peritonitis is identified. Cranial mesenteric lymph nodes measure up to 3.75 mm in thickness. Ileocecal lymph nodes are not visualized. The iliac trifurcation has a normal appearance.

## PRIMARY FINDINGS

- Bilateral renal cortical hyperechogenicity and medullary rim sign.
- Mild enlargement of cranial mesenteric lymph nodes (3.75 mm).
- Mild relative thickening of the ileal muscularis propria.

## INTERPRETATION OF THE FINDINGS & FURTHER RECOMMENDATIONS

The kidneys are normal in size and shape, with preserved corticomedullary definition; however, the bilateral cortical hyperechogenicity and presence of a medullary rim sign are changes commonly associated with chronic renal disease in cats and are compatible with the mild azotemia and increased SDMA previously identified.

The gastrointestinal tract demonstrates preserved wall layering throughout, with mural thicknesses that are largely within or near reference limits. The ileum shows relative prominence of the muscularis propria, resulting in a mildly increased total wall thickness; while this pattern can be seen in inflammatory bowel disease and small-cell lymphoma, it is not specific and may overlap between these entities. The lack of focal masses, transmural loss of layering, or marked lymphadenopathy argues against high-grade alimentary lymphoma.

Cranial mesenteric lymph nodes measure up to 3.75 mm, which is at the upper limit of normal. In the absence of architectural abnormalities, this finding is considered nonspecific and most compatible with reactive change in the context of chronic gastrointestinal disease.



## PATIENT

Remi Kaufmann

## SPECIES

Feline

## BREED

DSH

## SEX

Neutered Male

## AGE

14 Years

## WEIGHT

10 lbs

## INTERPRETED BY

Alicia Angosto  
Guerrero, DMV,  
PgDip, MSc.

## IMAGING PERFORMED BY

Dr. Beth Coe

## HOSPITAL NAME

Riverside Animal Clinic

## REFERRING VET

Dr. Beth Coe

## INVOICE

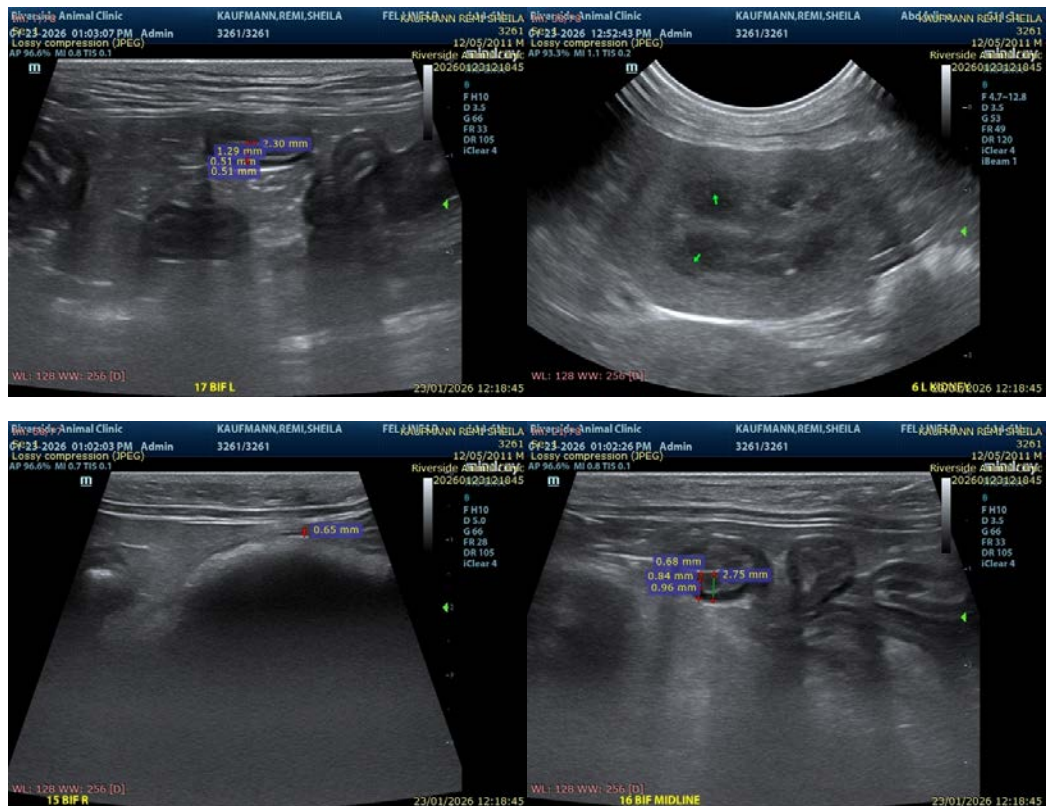
72417

## DATE

1/23/26

## Recommendations:

- Initiate a strict dietary trial as the first-line approach, using a novel protein or hydrolyzed diet, with strict avoidance of all other foods and treats.
- Consider a comprehensive gastrointestinal panel to further assess for malabsorptive, inflammatory, or concurrent pancreatic disease that may not be apparent on ultrasonography.
- Cobalamin supplementation is recommended if deficiency is identified.
- Close clinical and weight monitoring is recommended during dietary and medical management, with particular attention to appetite, vomiting frequency, and body condition.
- Intestinal biopsies may be considered if clinical signs persist or progress despite appropriate dietary and medical trials, recognizing that current ultrasonographic findings do not demonstrate definitive features of intestinal lymphoma. Biopsy would then be indicated to differentiate inflammatory bowel disease from small-cell alimentary lymphoma.
- Monitor renal parameters.





## PATIENT

Remi Kaufmann

## SPECIES

Feline

## BREED

DSH

## SEX

Neutered Male

## AGE

14 Years

## WEIGHT

10 lbs

## INTERPRETED BY

Alicia Angosto Guerrero, DMV,  
PgDip, MSc.

## IMAGING PERFORMED BY

Dr. Beth Coe

## HOSPITAL NAME

Riverside Animal Clinic

## REFERRING VET

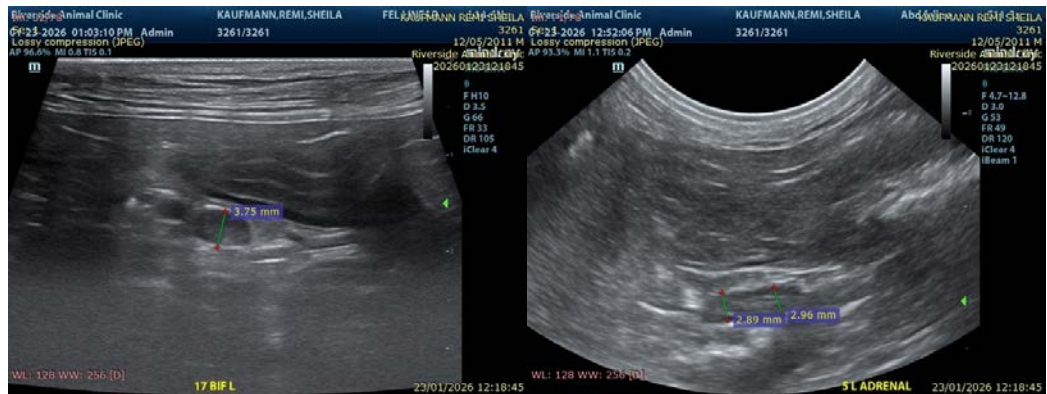
Dr. Beth Coe

## INVOICE

72417

## DATE

1/23/26



The information and recommendations provided are based on the images presented by the referring veterinarian/sonographer. No evaluation can be communicated regarding pathology that was not visible in the image/video clips provided.

Thank you for this referral. If the clinical or image interpretation does not parallel your findings or if I can be of any further assistance please contact me.

Alicia Angosto Guerrero, DMV, PgDip, MSc.

[info@SonoPath.com](mailto:info@SonoPath.com)