



PATIENT

Oreo Ascencio

SPECIES

Ferret

BREED

Ferret

SEX

Neutered male

AGE

6 ½ years

WEIGHT

2.9 lbs

INTERPRETED BY

Dr. Alicia Angosto
Guerrero

IMAGING PERFORMED BY

Heidi Putnam, LVT

HOSPITAL NAME

Northwest Exotic Pet
Vet

REFERRING VET

Dr. Ramsell

INVOICE

70351

DATE

1/20/26

PRESENTING CLINICAL SIGNS

- Exam on 1/6/26 - Fairly BAR, 3+ dental calculus, Heart slightly muffled with one skipped beat, slightly thin over ribs, but heavy abdomen, stools variable in smell and chronic gas, mild splenomegaly; possible gastric trichobezoar?
- Chems: WNL CBC: * Slightly elevated WBC ct (8,800/ul) * Lymphocytes somewhat increased (66%; 5,808/ul) Fecal Results: Negative UA: Fairly uneventful

ULTRASONOGRAPHIC EXAMINATION OF THE ABDOMEN

Urinary System

The urinary bladder is poorly distended, which precludes reliable assessment of bladder wall thickness. The urine is anechoic. The bladder neck and proximal urethra have a normal ultrasonographic appearance. No uroliths are identified.

Left kidney: Normal in shape and size, measuring 2.90×1.27 cm. Cortical thickness is 0.22 cm in the sagittal plane. The renal cortex is isoechogenic relative to the liver parenchyma. A well-defined renal cortical cyst measuring 1.08×1.39 mm is present at the cranial pole. The corticomedullary ratio and corticomedullary definition are preserved. No pyelectasia, nephroliths, or hydronephrosis are identified.

Right kidney: Normal in shape and size, measuring 2.93×1.19 cm. Cortical thickness is 0.19 cm in the sagittal plane. The renal cortex is isoechogenic relative to the liver parenchyma. Multiple small renal cortical cysts are present, including a 1×1.78 mm cyst and a 2.24×2.98 mm cyst, as well as a minute focal mineralization measuring 0.54 mm, all located at the caudal pole. The corticomedullary ratio and corticomedullary definition are preserved. The renal pelvis measures 0.83 mm. No hydronephrosis is identified.

Adrenal Glands

Both adrenal glands have normal shape and echogenicity.

Left adrenal gland measures 0.23 cm at both cranial and caudal poles.

Right adrenal gland measures 0.20 cm at the cranial pole and 0.18 cm at the caudal pole. A focal mineralization measuring 1.29×2.67 mm is present within the central-lateral region of one adrenal gland.

Spleen

Splenic thickness ranges from 0.8–1.25 cm, with rounded margins. The splenic parenchyma has normal echogenicity with mildly heterogeneous echotexture and a small number of hypoechoic foci, all measuring <0.5 cm. The splenic capsule is smooth and regular.



PATIENT

Oreo Ascencio

SPECIES

Ferret

BREED

Ferret

SEX

Neutered male

AGE

6 ½ years

WEIGHT

2.9 lbs

INTERPRETED BY

Dr. Alicia Angosto
Guerrero

IMAGING PERFORMED BY

Heidi Putnam, LVT

HOSPITAL NAME

Northwest Exotic Pet
Vet

REFERRING VET

Dr. Ramsell

INVOICE

70351

DATE

1/20/26

Liver

The liver is subjectively normal in size, with sharp margins and a regular contour. The hepatic parenchyma is uniform and isoechoic relative to surrounding fat, with a normal echotexture. No hepatic lymphadenopathy is observed.

The gallbladder is normally distended. The gallbladder wall measures 0.50 mm. The contents are predominantly anechoic, with a very small amount of mineral sediment present. No dilation of the cystic duct or common bile duct is observed.

Gastrointestinal

Stomach: Empty and folded, with a fluid pattern. Gastric mural thickness measures 1.22 mm, with preserved wall layering. A strongly hyperechoic intraluminal structure measuring 6.30 mm with intense distal acoustic shadowing is identified. Pylorus: Wall thickness 1.09 mm.

Duodenum: Wall thickness 1.16 mm.

Jejunum: Wall thickness 0.88 mm, with preserved wall layering.

Ileum: Not reliably measured.

The ileocecal junction is not visualized. No ultrasonographic evidence of intestinal obstruction or ileus is identified.

Colon: Wall thickness 0.48 mm, with a small amount of very soft fecal material present.

Pancreas

The right pancreatic limb measures 4.38 mm. The body and left limb measure 3.37 mm and appear normal. The pancreatic parenchyma is isoechoic relative to adjacent omental fat. The pancreatic duct measures 0.58 mm. No ultrasonographic evidence of pancreatitis or pancreatic mass lesions is identified.

Peritoneal Cavity

A very small volume of abdominal effusion is present within the splenic recess.

Several abdominal lymph nodes are identified:

- Pancreaticoduodenal lymph node measuring 4.53×7.12 mm
 - Gastric lymph nodes measuring 4.85×8.96 mm and 5.57×5.61 mm
 - Jejunal (cranial mesenteric lymph node) measuring approximately 4 mm in thickness.
- These lymph nodes are mildly heterogeneous, with small areas that appear cystic.
- Caudal mesenteric lymph node: 5.87×6.56 mm, cystic.



PATIENT

The iliac trifurcation has a normal appearance.

Oreo Ascencio

SPECIES

Thorax

Ferret

A superficial cranial mediastinal structure is identified adjacent to the thoracic wall, with parenchymal echogenicity and a trabecular pattern, most consistent with residual thymic tissue. Due to limited imaging planes and available clips, definitive characterization is limited. Differential considerations include a mediastinal mass; however, this is considered less likely given the superficial location and echotexture.

BREED

Ferret

SEX

Neutered male

ULTRASONOGRAPHIC FINDINGS

PRIMARY FINDINGS

- Mild splenomegaly with rounded margins and heterogeneous echotexture.
- Very mild abdominal effusion at the splenic recess.
- Multiple mildly enlarged, cystic lymph nodes.

SECONDARY FINDINGS

- Multiple small renal cortical cysts and minimal renal mineralization.
- Focal adrenal mineralization (incidental).
- Hyperechoic, shadowing intragastric structure.
- Superficial cranial mediastinal structure.

AGE

6 ½ years

WEIGHT

2.9 lbs

INTERPRETED BY

Dr. Alicia Angosto
Guerrero

IMAGING PERFORMED BY

Heidi Putnam, LVT

HOSPITAL NAME

Northwest Exotic Pet
Vet

REFERRING VET

Dr. Ramsell

INVOICE

70351

DATE

1/20/26

INTERPRETATION OF THE FINDINGS & FURTHER RECOMMENDATIONS

The spleen is enlarged with rounded margins and mildly heterogeneous echotexture, containing small hypoechoic nodules. In the absence of a diffuse multinodular or “honeycomb” pattern, this appearance is most consistent with benign splenic change in ferrets, such as extramedullary hematopoiesis and/or nodular hyperplasia, both of which are frequently encountered in this species.

Some abdominal lymph nodes are mild to moderately enlarged and mildly heterogeneous, with small cystic-appearing areas. Cystic-appearing changes within abdominal lymph nodes are frequently observed in ferrets and have been described as a nonspecific finding. Although their pathogenesis is not fully understood, lymphatic sinus ectasia, chronic lymphatic congestion, and prolonged antigenic stimulation through a compromised intestinal mucosa have been proposed as contributing factors. These changes may reflect functional exhaustion or remodeling of lymphoid tissue rather than primary lymphoid neoplasia, particularly when nodal enlargement is mild and overall nodal architecture is preserved.

Measured small intestinal wall thickness (duodenum 1.16 mm; jejunum 0.88 mm) falls within the expected range for ferrets in the absence of published, universally adopted reference intervals, and



PATIENT

Oreo Ascencio

SPECIES

Ferret

BREED

Ferret

SEX

Neutered male

AGE

6 ½ years

WEIGHT

2.9 lbs

INTERPRETED BY

Dr. Alicia Angosto
Guerrero

IMAGING PERFORMED BY

Heidi Putnam, LVT

HOSPITAL NAME

Northwest Exotic Pet
Vet

REFERRING VET

Dr. Ramsell

INVOICE

70351

DATE

1/20/26

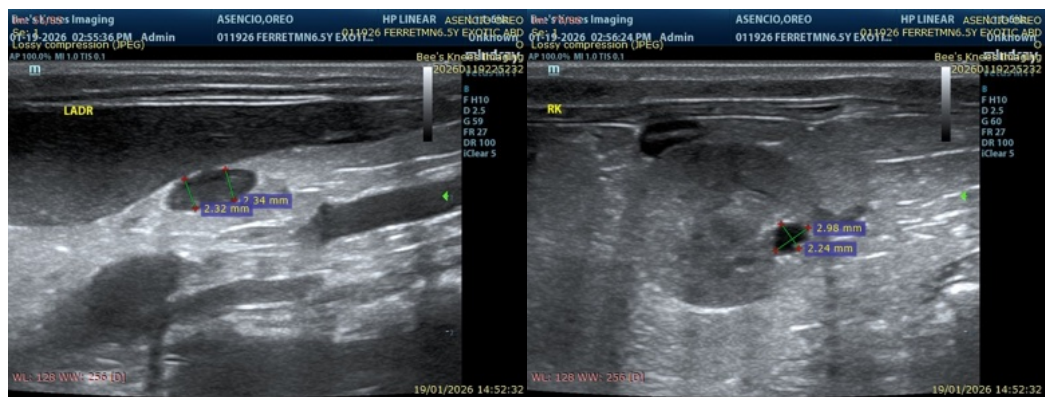
there is no ultrasonographic evidence of diffuse moderate small intestinal thickening of the magnitude often described with inflammatory bowel disease in this species. Wall layering is preserved, noting that in ferrets the small intestinal wall is typically assessed with less conspicuous layer distinction than in dogs and cats. The stomach contains a strongly hyperechoic intraluminal structure with intense distal acoustic shadowing, compatible with intragastric foreign material, and a trichobezoar is a recognized possibility. Ingesta/compacted food material or other ingested debris may create a similar appearance, and ultrasound cannot always distinguish among these.

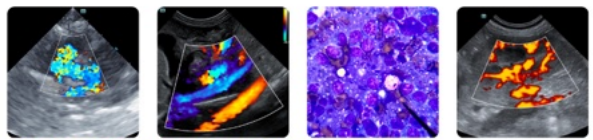
The superficial cranial mediastinal structure may represent residual thymic tissue based on location and trabecular parenchymal echotexture. However, a definitive exclusion of early mediastinal pathology is limited by the available imaging planes.

Overall, the ultrasonographic findings are most consistent with a benign, reactive process involving the spleen and abdominal lymph nodes, likely related to chronic gastrointestinal antigenic stimulation and lymphoid hyperplasia. While these findings may overlap with early or low-grade lymphoid neoplasia in ferrets, there are no features to support aggressive disease at this time, and ultrasonography alone cannot definitively differentiate between these entities.

Recommendations

- Dietary management aimed at minimizing gastrointestinal antigenic stimulation is recommended, favoring a highly digestible, animal-protein-based diet with limited ingredient variability. Supportive gastrointestinal care may be considered to reduce mucosal irritation and chronic antigenic exposure.
- Short-term clinical reassessment is advised to monitor response and progression, with repeat abdominal ultrasound considered if clinical signs worsen or new systemic signs develop.
- Further diagnostic testing is indicated if there is a progression of lymph node enlargement, development of systemic illness, or lack of response to conservative management. Histologic sampling (excisional lymph node biopsy and/or splenic biopsy) would be preferred for definitive diagnosis, as cytology of splenic or lymphoid tissue in ferrets is often of limited diagnostic value for distinguishing reactive change from lymphoma.





PATIENT

Oreo Ascencio

SPECIES

Ferret

BREED

Ferret

SEX

Neutered male

AGE

6 ½ years

WEIGHT

2.9 lbs

INTERPRETED BY

Dr. Alicia Angosto Guerrero

IMAGING PERFORMED BY

Heidi Putnam, LVT

HOSPITAL NAME

Northwest Exotic Pet Vet

REFERRING VET

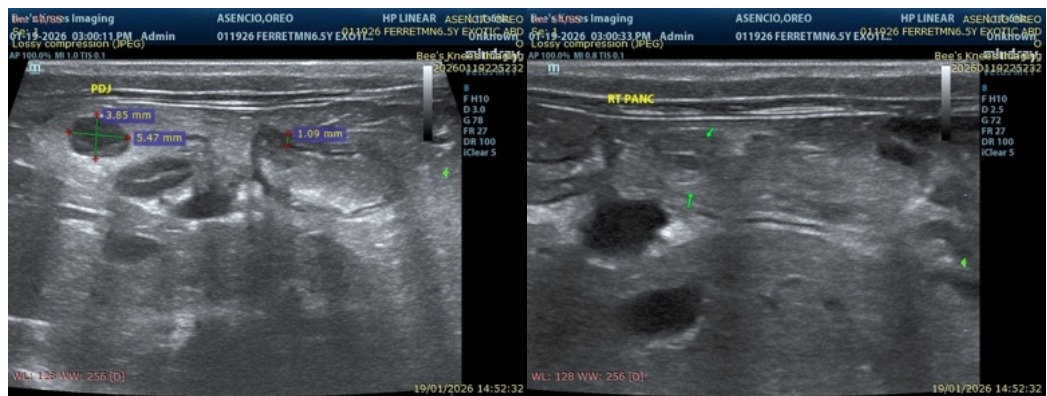
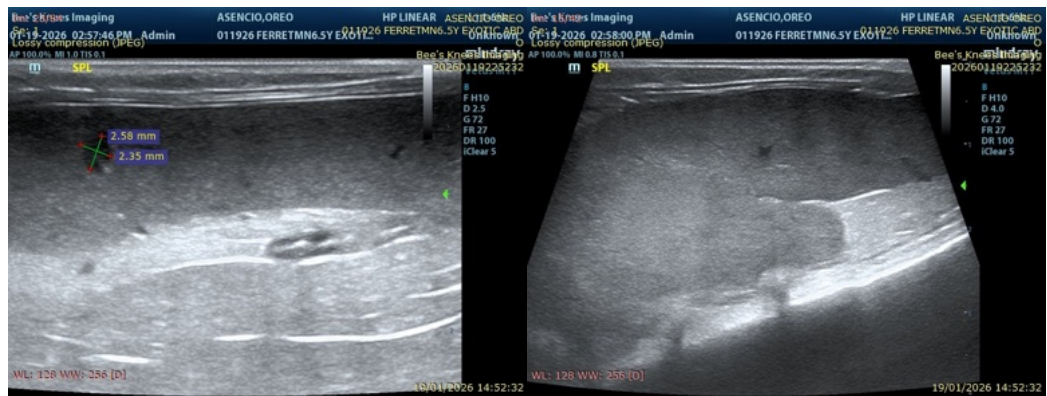
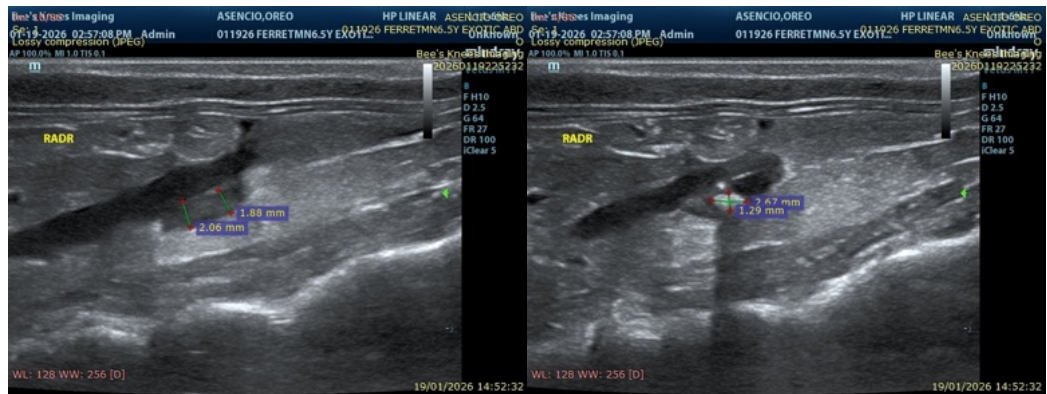
Dr. Ramsell

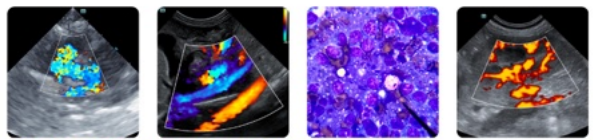
INVOICE

70351

DATE

1/20/26





PATIENT

Oreo Ascencio

SPECIES

Ferret

BREED

Ferret

SEX

Neutered male

AGE

6 ½ years

WEIGHT

2.9 lbs

INTERPRETED BY

Dr. Alicia Angosto Guerrero

IMAGING PERFORMED BY

Heidi Putnam, LVT

HOSPITAL NAME

Northwest Exotic Pet Vet

REFERRING VET

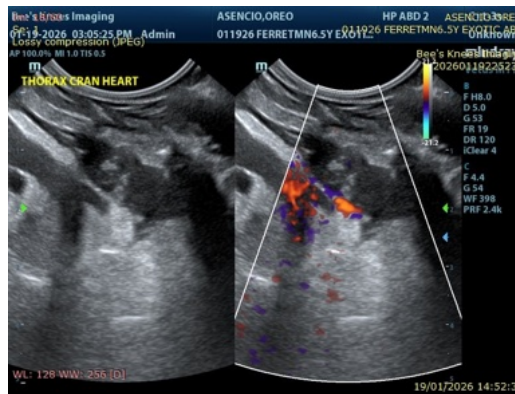
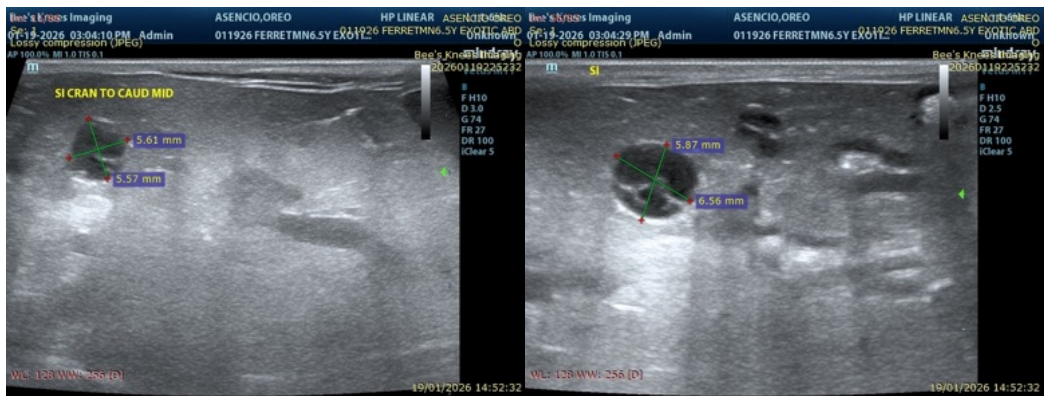
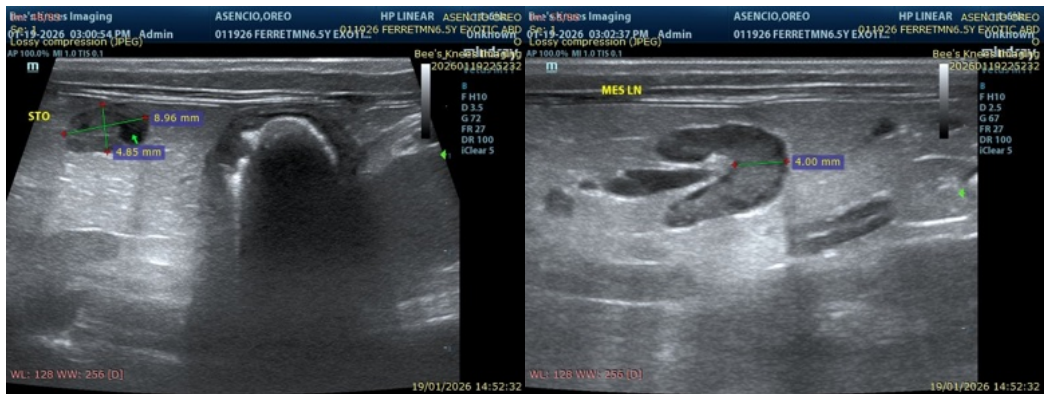
Dr. Ramsell

INVOICE

70351

DATE

1/20/26



The information and recommendations provided are based on the images presented by the referring veterinarian/sonographer. No evaluation can be communicated regarding pathology that was not visible in the image/video clips provided.

Thank you for this referral. If the clinical or image interpretation does not parallel your findings or if I can be of any further assistance please contact me.

Alicia Angosto Guerrero, DMV, PgDip, MSc.

MV Esp Ultrasound in Domestic and Wild Animals

info@SonoPath.com