



PATIENT

Ottis Rusnak

SPECIES

Canine

BREED

Puggle

SEX

Neutered male

AGE

15 years

WEIGHT

34.6 lbs

INTERPRETED BY

Dr. Alicia Angosto
Guerrero

IMAGING PERFORMED BY

Brandon Holmes

HOSPITAL NAME

West Newton AC

REFERRING VET

Dr. Holmes

INVOICE

70174

DATE

1/15/26

PRESENTING CLINICAL SIGNS

History: 2.2 lb weight loss over the last year despite no diet change and good appetite. Showing some signs of cognitive decline.

ALP = 475, lipase = 383, monocytes = 928

ULTRASONOGRAPHIC EXAMINATION OF THE ABDOMEN

Urinary System

The urinary bladder is normally distended. The urinary bladder wall appears thin, smooth, and regular. The bladder lumen contains anechoic urine. The bladder neck and proximal urethra are unremarkable. There is no evidence of urolithiasis or sonographic features suggestive of inflammatory or neoplastic disease.

The left kidney is normal in shape and size, measuring 5.58×3.71 cm, with a cortical thickness of 0.52 cm in the sagittal plane. The renal cortex is isoechoic relative to the liver parenchyma. Corticomedullary ratio and corticomedullary definition are preserved. A small, well-defined cortical cyst measuring approximately 3.90 × 3.94 mm is identified. There is no evidence of pyelectasia, nephrolithiasis, or hydronephrosis. Color Doppler evaluation demonstrates normal renal perfusion.

The right kidney is normal in shape and size, measuring 5.87×3.26 cm, with a cortical thickness of 0.57 cm in the sagittal plane. The renal cortex is isoechoic relative to the liver parenchyma. Corticomedullary ratio and corticomedullary definition are preserved. There is no evidence of pyelectasia, nephrolithiasis, or hydronephrosis.

Adrenal Glands

Both adrenal glands demonstrate normal shape and echogenicity. The left adrenal gland measures approximately 0.85 cm at the cranial pole and 0.71 cm at the caudal pole. The right adrenal gland measures approximately 0.94 cm at the cranial pole and 0.89 cm at the caudal pole.

Spleen

The spleen measures approximately 1.46 cm in thickness. The splenic parenchyma demonstrates normal echogenicity and a fine, homogeneous echotexture. Multiple small, well-defined hyperechoic foci consistent with splenic myelolipomas are identified, the largest measuring approximately 3.86 × 8.38 mm.

Additionally, at the distal aspect of the spleen (splenic tail), a heterogeneous nodular lesion is identified, measuring approximately 1.29×1.97 cm (maximum dimension from three measurements). This lesion does not distort the splenic capsule and does not protrude beyond the splenic margin. Splenic vasculature appears normal.



PATIENT

Ottis Rusnak

SPECIES

Canine

BREED

Puggle

SEX

Neutered male

AGE

15 years

WEIGHT

34.6 lbs

INTERPRETED BY

Dr. Alicia Angosto
Guerrero

IMAGING PERFORMED BY

Brandon Holmes

HOSPITAL NAME

West Newton AC

REFERRING VET

Dr. Holmes

INVOICE

70174

DATE

1/15/26

Liver

The liver is subjectively normal in size, with sharp margins and a smooth contour. The hepatic parenchyma is largely uniform and isoechoic relative to the falciform fat, with a normal echotexture.

Within the dorsal aspect of what appears to be the left medial hepatic lobe, there is a cystic structure with a markedly thick and irregular wall, measuring approximately 3.43 × 2.99 cm (maximum dimensions, including the wall). The contents of this structure are completely anechoic. No hepatic lymphadenopathy is identified.

The gallbladder is normally distended. The gallbladder wall demonstrates changes consistent with mucous gland hyperplasia, with a few small, isolated polypoid-appearing structures. The gallbladder lumen contains a moderate amount of biliary sludge. There is no sonographic evidence of dilation of the cystic duct or common bile duct.

Gastrointestinal

The stomach contains ingesta. Gastric wall thickness measures approximately 3.37 mm, with preserved wall layering.

The pylorus measures approximately 4.11 mm. The distal duodenum measures approximately 3.51 mm. The jejunum measures approximately 3.35–3.55 mm. The ileum measures approximately 2.26 mm. Wall layering is preserved throughout the evaluated intestinal segments. No sonographic evidence of inflammation, ileus, or foreign material is identified.

The colon measures approximately 1.25 mm (transverse colon) and 1.04 mm (descending colon), with formed fecal material present in the descending segment.

Pancreas

The pancreatic regions evaluated do not demonstrate sonographic evidence of overt inflammation.

Peritoneal Cavity

No abdominal effusion or sonographic evidence of peritonitis is observed. Cranial mesenteric and ileocecal lymph nodes are not visualized; the surrounding regions appear unremarkable. The iliac trifurcation is normal.

ULTRASONOGRAPHIC FINDINGS

PRIMARY FINDINGS

- Complex cystic lesion with thick, irregular wall within the left medial hepatic lobe (≈ 3.4 × 3.0 cm).
- Solitary heterogeneous splenic nodular lesion at the distal aspect of the spleen (≈ 1.3 × 2.0 cm), without capsular distortion.



PATIENT

Ottis Rusnak

SPECIES

Canine

BREED

Puggle

SEX

Neutered male

AGE

15 years

WEIGHT

34.6 lbs

INTERPRETED BY

Dr. Alicia Angosto
Guerrero

IMAGING PERFORMED BY

Brandon Holmes

HOSPITAL NAME

West Newton AC

REFERRING VET

Dr. Holmes

INVOICE

70174

DATE

1/15/26

- Gallbladder wall changes consistent with mucous gland hyperplasia, with moderate biliary sludge.

SECONDARY FINDINGS

- Small left renal cortical cyst.
- Multiple small hyperechoic splenic foci consistent with splenic myelolipomas.

INTERPRETATION OF THE FINDINGS & FURTHER RECOMMENDATIONS

The most notable hepatic abnormality is a large cystic lesion with a thickened and irregular wall within the left medial hepatic lobe. While the anechoic contents suggest a fluid-filled structure, the marked wall thickness and irregularity are atypical for a simple hepatic cyst and raise concern for a complex cystic lesion, such as a biliary cyst, abscess, or less likely a cystic degeneration of a mass. Ultrasound alone cannot reliably distinguish between these possibilities, and this lesion warrants further characterization given the patient's age and unexplained weight loss.

Splenic findings include multiple small hyperechoic foci consistent with benign splenic myelolipomas, which are considered incidental. In addition, a solitary heterogeneous nodular lesion is identified at the distal aspect of the spleen, without capsular distortion or significant mass effect. In a geriatric dog, differential considerations for this lesion include nodular hyperplasia, hematoma, or less likely early neoplasia. Based on its size, imaging characteristics, and lack of associated abnormalities, nodular hyperplasia is considered the most likely diagnosis at this time, although definitive characterization cannot be achieved with ultrasonography alone.

There is no ultrasonographic evidence to suggest a direct pathophysiologic relationship between these findings. Each lesion warrants further diagnostic investigation based on its individual characteristics and the patient's clinical presentation.

Mild gallbladder changes, including mucous gland hyperplasia, polyp, and biliary sludge, may correlate with the elevated alkaline phosphatase activity and suggest chronic biliary disease; however, no biliary obstruction is identified. Both adrenal glands are within the upper limits of expected size for this patient, and in the absence of supportive clinical or additional imaging findings, do not support a diagnosis of hyperadrenocorticism.

Recommendations

- Given the deep dorsal location of the hepatic lesion, ultrasound-guided sampling may be technically challenging and of limited diagnostic yield. Advanced imaging or surgical exploration should therefore be considered for definitive characterization.
- If advanced diagnostics are declined, conservative management with serial ultrasonographic monitoring is a reasonable alternative, provided the patient remains clinically stable. Follow-up ultrasound is recommended to assess for changes in lesion size, wall thickness, internal architecture, or the development of additional abnormalities.
- Cytologic sampling or short-term monitoring of the splenic nodular lesion may be considered, with prioritization guided by clinical progression and staging results.



PATIENT

Ottis Rusnak

SPECIES

Canine

BREED

Puggle

SEX

Neutered male

AGE

15 years

WEIGHT

34.6 lbs

INTERPRETED BY

Dr. Alicia Angosto
Guerrero

IMAGING PERFORMED BY

Brandon Holmes

HOSPITAL NAME

West Newton AC

REFERRING VET

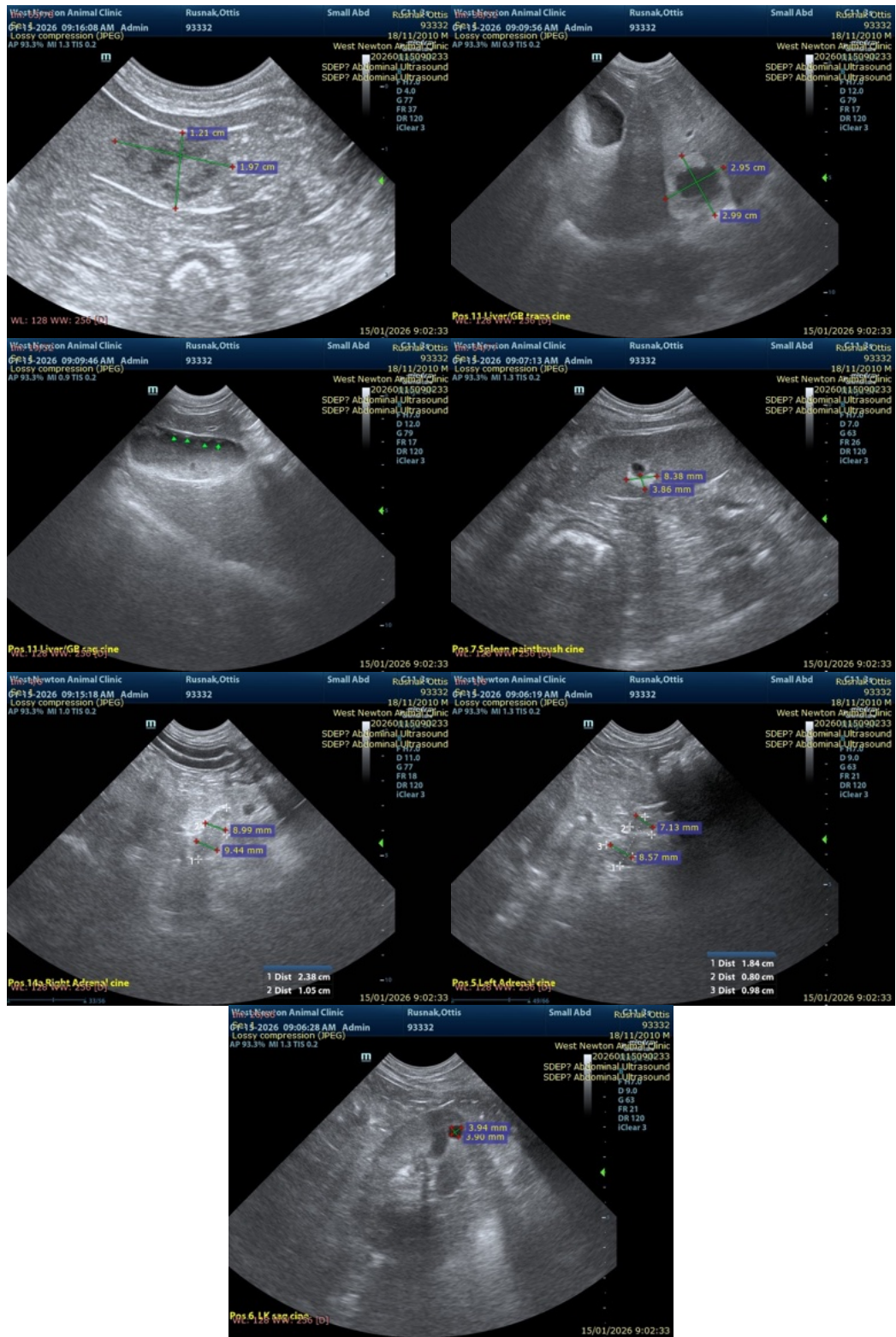
Dr. Holmes

INVOICE

70174

DATE

1/15/26





PATIENT

Ottis Rusnak

SPECIES

Canine

BREED

Puggle

SEX

Neutered male

AGE

15 years

WEIGHT

34.6 lbs

INTERPRETED BY

Dr. Alicia Angosto
Guerrero

IMAGING PERFORMED BY

Brandon Holmes

HOSPITAL NAME

West Newton AC

REFERRING VET

Dr. Holmes

INVOICE

70174

DATE

1/15/26

The information and recommendations provided are based on the images presented by the referring veterinarian/sonographer. No evaluation can be communicated regarding pathology that was not visible in the image/video clips provided.

Thank you for this referral. If the clinical or image interpretation does not parallel your findings or if I can be of any further assistance please contact me.

Alicia Angosto Guerrero, DMV, PgDip, MSc.

MV Esp Ultrasound in Domestic and Wild Animals

info@SonoPath.com