



PATIENT

Obi Kowalski

SPECIES

Feline

BREED

Exotic Shorthair

SEX

Neutered male

AGE

8 years

WEIGHT

2.6 kg

INTERPRETED BY

Dr. Alicia Angosto
Guerrero

IMAGING PERFORMED BY

Danielle RVT

HOSPITAL NAME

Orchard VC

REFERRING VET

Dr. Gudelot

INVOICE

70135

DATE

1/14/26

PRESENTING CLINICAL SIGNS

History: Over the last 2-3 year Obi started to vomit 1x/week. Owners tried hypo diet for 2 years with little success to stop vomiting. Obi has been on Cerenia, omeprazole and sucralfate with no changes to clinical signs. Over the last 6 months clinical signs have gotten more severe where he is vomiting several times a day. He has had on/off diarrhea for 2 weeks. He is QAR/lethargic at home.

Abnormal PE/Chem/CBC/UA Results: Blood work ran Dec 5/25 Mild anemia that is regenerative, borderline insufficiently regenerative. Mild leukocytosis characterize by neutrophilia. Low TP, otherwise Chem NAF

ULTRASONOGRAPHIC EXAMINATION OF THE ABDOMEN

Urinary System

The urinary bladder is normally distended. The urinary bladder wall appears thin, smooth, and regular. The bladder lumen contains anechoic urine. The bladder neck and proximal urethra are unremarkable. There is no evidence of urolithiasis or sonographic features suggestive of inflammatory or neoplastic disease.

The left kidney is normal in shape and size, measuring 4.05×2.73 cm, with a cortical thickness of 0.38 cm in the sagittal plane. The right kidney is normal in shape and size, measuring 4.12×2.51 cm, with a cortical thickness of 0.42 cm in the sagittal plane. In both kidneys, the renal cortex is hyperechoic relative to the liver parenchyma. Corticomedullary ratio and corticomedullary definition are preserved. A medullary rim sign is noted bilaterally. There is no evidence of pyelectasia, nephrolithiasis, or hydronephrosis. Color Doppler evaluation demonstrates normal renal perfusion patterns.

Adrenal Glands

The left adrenal gland measures approximately 0.46 cm at the cranial pole and 0.38 cm at the caudal pole. The right adrenal gland measures approximately 0.35 cm at both the cranial and caudal poles. Both adrenal glands are within normal size limits.

Spleen

The spleen measures approximately 0.74 cm in thickness. The splenic parenchyma demonstrates normal echogenicity and a fine, homogeneous echotexture without focal lesions. The splenic capsule is smooth and regular.

Liver

The liver is subjectively normal in size, with sharp margins and a smooth contour. The hepatic parenchyma is uniform and isoechoic relative to the falciform fat, with normal echotexture. No hepatic lymphadenopathy is identified.



PATIENT

Obi Kowalski

The gallbladder is normally distended. The wall is thin, and the luminal contents are predominantly anechoic. The common bile duct measures approximately 1.80 mm, which is within normal limits. No biliary dilation is observed.

SPECIES

Feline

Gastrointestinal

BREED

Exotic Shorthair

The stomach is predominantly empty and folded, with a baseline mural thickness of approximately 2.40 mm and preserved wall layering in most regions. However, at the transition from the gastric body to the pyloric region, there is a focal, markedly thickened segment measuring approximately 1.27–1.93 cm, with loss of normal wall stratification. This region forms a heterogeneous mass-like lesion measuring approximately 4.78×3.16 cm, which extends into the pyloric region and results in partial luminal obstruction.

SEX

Neutered male

The duodenum is not fully visualized, and its involvement cannot be definitively assessed. Portions of the duodenum that are visualized appear normal; however, infiltration of the proximal duodenum cannot be ruled out.

AGE

8 years

The jejunum measures approximately 1.90 mm in total wall thickness, with preserved wall layering:

- Mucosa: 0.86 mm, Submucosa: 0.59 mm, Muscularis propria: 0.20 mm

WEIGHT

2.6 kg

The ileum measures approximately 2.56 mm, with preserved wall layering:

- Mucosa: 0.80 mm, Submucosa: 0.81 mm, Muscularis propria: 0.90 mm

INTERPRETED BY

Dr. Alicia Angosto
Guerrero

The ileocecal junction measures approximately 2.43 mm, with a muscularis layer of 1.13 mm. The intestinal segments visualized in the provided video clips demonstrate normal wall layering.

IMAGING PERFORMED BY

Danielle RVT

The colon demonstrates normal wall thickness: Ascending colon: 0.68 mm. Transverse colon: 0.67 mm. Descending colon: 1.02 mm. Formed fecal material is present.

HOSPITAL NAME

Orchard VC

Pancreas

The portions of the pancreas that were evaluated appear unremarkable, with no sonographic evidence of active inflammation.

REFERRING VET

Dr. Gudelot

Peritoneal Cavity

No abdominal effusion or sonographic evidence of peritonitis is observed.

INVOICE

70135

A right gastric lymph node is identified, measuring at least 1.22×0.61 cm.

Cranial mesenteric lymph nodes are not visualized.

DATE

1/14/26

The ileocecal lymph nodes measure approximately 2.88–3.08 mm and are normal in shape and echogenicity.

A splenic lymph node measuring approximately 2.78 mm is identified and appears normal. The iliac trifurcation is unremarkable.



PATIENT

Obi Kowalski

SPECIES

Feline

BREED

Exotic Shorthair

SEX

Neutered male

AGE

8 years

WEIGHT

2.6 kg

INTERPRETED BY

Dr. Alicia Angosto
Guerrero

IMAGING PERFORMED BY

Danielle RVT

HOSPITAL NAME

Orchard VC

REFERRING VET

Dr. Gudelot

INVOICE

70135

DATE

1/14/26

ULTRASONOGRAPHIC FINDINGS

- Large focal gastric mass at the body-pyloric junction with loss of wall layering.
- Enlarged right gastric lymph node.
- Mild ileal wall thickening with a relatively prominent muscularis layer.
- Bilateral cortical hyperechogenicity and a medullary rim.

INTERPRETATION OF THE FINDINGS & FURTHER RECOMMENDATIONS

The abdominal ultrasound reveals a focal, large, mass-like gastric lesion centered at the gastric body-pyloric junction, characterized by severe mural thickening, loss of normal wall stratification, and partial luminal obstruction, with associated enlargement of a right gastric lymph node.

The ultrasonographic appearance of this lesion is highly suspicious for primary gastric neoplasia. The focal nature, mass effect, loss of wall layering, and obstructive behavior are not typical of inflammatory gastritis or functional hypertrophy and instead strongly support a neoplastic process. Differential considerations include gastric lymphoma (high-grade more likely than low-grade given the mass-forming behavior), adenocarcinoma, or less commonly other round cell or mesenchymal tumors. Among these, lymphoma remains a leading consideration in cats, particularly in the setting of chronic gastrointestinal disease with recent rapid progression.

Although portions of the duodenum appear normal, incomplete visualization precludes definitive exclusion of proximal duodenal involvement, which may be present by direct extension or contiguous infiltration.

The identified right gastric lymphadenopathy may represent regional metastatic involvement.

The remainder of the small and large intestines largely demonstrate preserved wall layering and measurements within or near accepted limits; however, mild ileal wall thickening with a relatively prominent muscularis layer is noted. While there is no ultrasonographic evidence of a severe diffuse enteropathy, concurrent low-grade intestinal disease cannot be excluded.

Bilateral cortical hyperechogenicity and a medullary rim sign are noted; these findings are nonspecific and may represent incidental or early chronic renal changes.

Recommendations

Ultrasound-guided fine-needle aspiration of the gastric mass may be considered as an initial, minimally invasive diagnostic step, particularly if high-grade lymphoma or another round cell neoplasm is suspected. However, given the location, mass-forming behavior, and partial gastric outflow obstruction, cytology may be nondiagnostic and cannot reliably exclude epithelial neoplasia or low-grade lymphoma. Definitive diagnosis will most likely require full-thickness gastric biopsy.



PATIENT

Obi Kowalski

SPECIES

Feline

BREED

Exotic Shorthair

SEX

Neutered male

AGE

8 years

WEIGHT

2.6 kg

INTERPRETED BY

Dr. Alicia Angosto
Guerrero

IMAGING PERFORMED BY

Danielle RVT

HOSPITAL NAME

Orchard VC

REFERRING VET

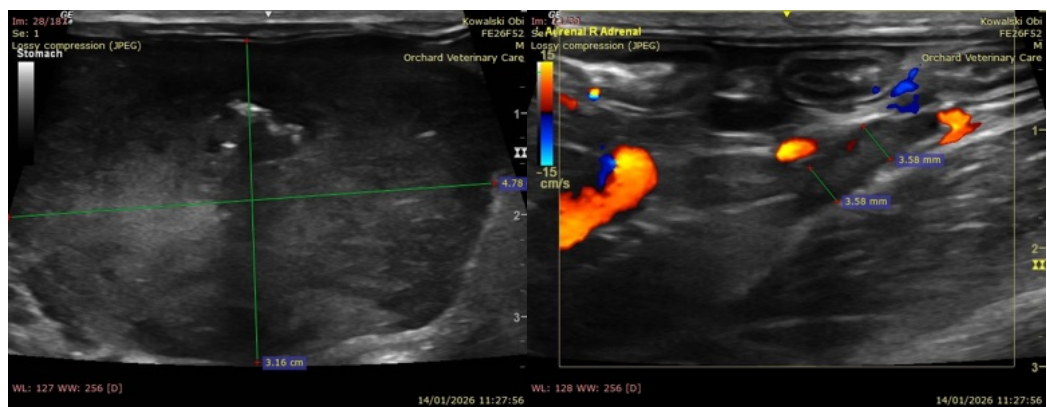
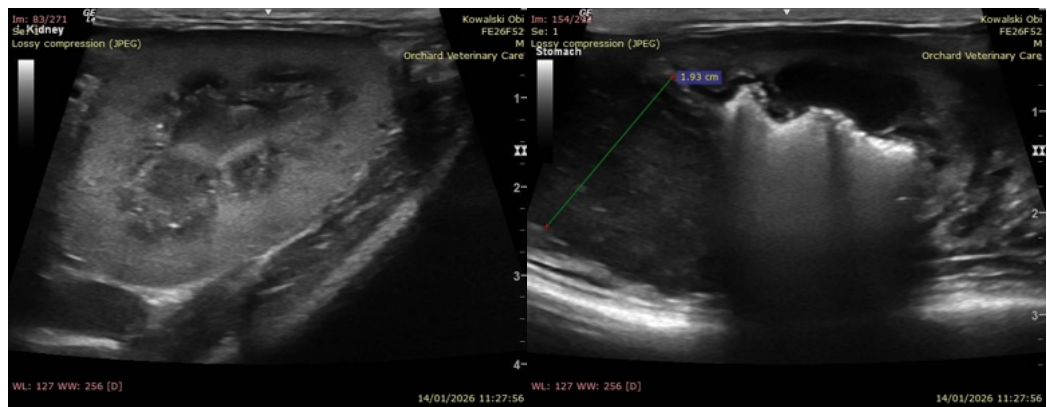
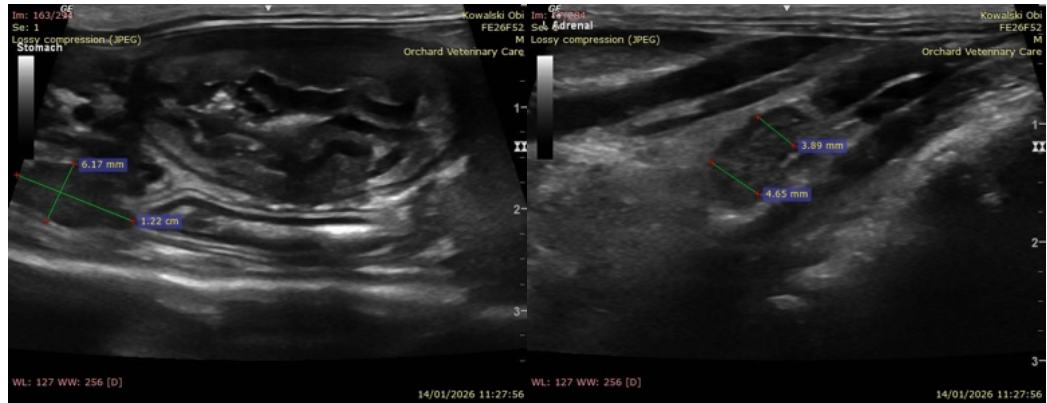
Dr. Gudelot

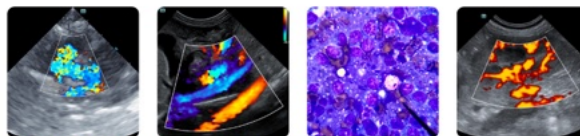
INVOICE

70135

DATE

1/14/26





PATIENT

Obi Kowalski

SPECIES

Feline

BREED

Exotic Shorthair

SEX

Neutered male

AGE

8 years

WEIGHT

2.6 kg

INTERPRETED BY

Dr. Alicia Angosto
Guerrero

IMAGING PERFORMED BY

Danielle RVT

HOSPITAL NAME

Orchard VC

REFERRING VET

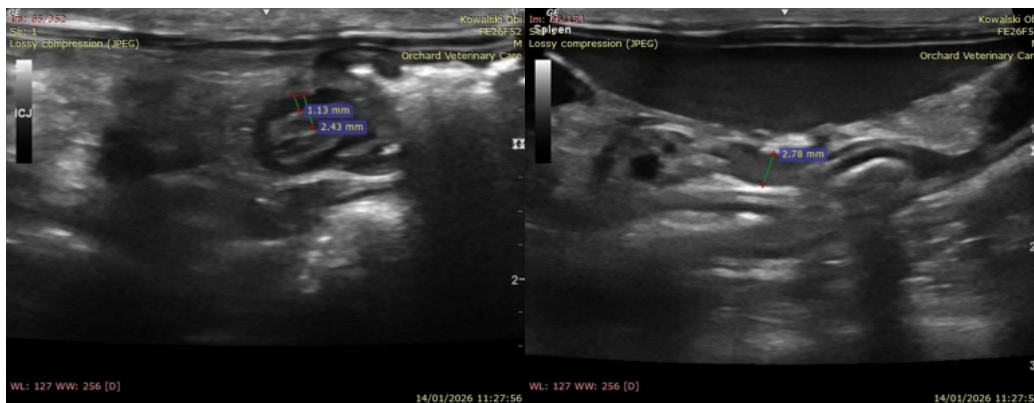
Dr. Gudelot

INVOICE

70135

DATE

1/14/26



The information and recommendations provided are based on the images presented by the referring veterinarian/sonographer. No evaluation can be communicated regarding pathology that was not visible in the image/video clips provided.

Thank you for this referral. If the clinical or image interpretation does not parallel your findings or if I can be of any further assistance please contact me.

Alicia Angosto Guerrero, DMV, PgDip, MSc.

MV Esp Ultrasound in Domestic and Wild Animals

info@SonoPath.com