



PATIENT

Lulu Darcy

SPECIES

Feline

BREED

Domestic Longhair

SEX

Spayed Female

AGE

12 years

WEIGHT

6.94 lbs

INTERPRETED BY

Alicia Angosto
Guerrero, DMV,
PgDip, MSc.

IMAGING PERFORMED BY

Dr. Jazmin Munoz
Gonzalez

HOSPITAL NAME

Oakridge Veterinary
Clinic

REFERRING VET

Dr. Jazmin Munoz
Gonzalez

INVOICE

11101

DATE

1/13/2026

PRESENTING CLINICAL SIGNS

Chronic weight loss and diarrhea (that has now resolved). Hx of seizures and on Zonisamide 25 mg PO BID. On PE- BCS 3/9 and 10% dehydrated. Matts on coat, and long nails. Previous BW revealed: ALT of 732. Remainder of liver values wnl.

ULTRASONOGRAPHIC EXAMINATION OF THE ABDOMEN

Urinary System

The urinary bladder lumen is normally distended, and the bladder wall appears thin and smooth. The urine is mildly turbid with suspended echogenic echoes. The bladder neck and proximal urethra appear normal. No uroliths or sonographic evidence of inflammatory or neoplastic changes are identified.

Both kidneys are normal in shape and size.

- Left kidney: 3.10×2.25 cm, cortical thickness 0.34 cm (sagittal plane).
- Right kidney: 4.27×2.28 cm, cortical thickness 0.37 cm (sagittal plane).

The renal cortices are mildly and diffusely hyperechoic relative to the liver parenchyma. Corticomedullary ratio and corticomedullary definition are preserved. No evidence of pyelectasia, nephrolithiasis, or hydronephrosis is observed. Color Doppler demonstrates normal renal perfusion.

Adrenal Glands

Both adrenal glands are visualized and demonstrate normal shape and echogenicity.

- Left adrenal gland: 0.36 cm (cranial pole), 0.30 cm (caudal pole).
- Right adrenal gland: 0.33 cm (cranial pole), 0.35 cm (caudal pole).

Spleen

Splenic thickness measures 1.02 cm. The parenchyma shows normal echogenicity and fine, homogeneous echotexture without focal lesions. The splenic capsule is smooth and regular.

Liver

The liver is subjectively normal in size, with sharp edges and a regular contour. Hepatic parenchyma is uniform and isoechoic relative to the falciform fat, with a normal echotexture. No hepatic lymphadenopathy is identified.

The gallbladder lumen is normally distended. The wall is thin, and the contents are primarily anechoic with a small amount of biliary sludge. The common bile duct measures approximately 0.91–1.45 mm and is not dilated.

Gastrointestinal

The stomach is empty and mildly folded, containing a small amount of fluid. Gastric wall thickness measures approximately 1.65 mm, with preserved wall layering. The pylorus measures 3.71 mm.

- Duodenum: approximately 2.0 mm.



PATIENT

Lulu Darcy

SPECIES

Feline

BREED

Domestic Longhair

SEX

Spayed Female

AGE

12 years

WEIGHT

6.94 lbs

INTERPRETED BY

Alicia Angosto
Guerrero, DMV,
PgDip, MSc.

IMAGING PERFORMED BY

Dr. Jazmin Munoz
Gonzalez

HOSPITAL NAME

Oakridge Veterinary
Clinic

REFERRING VET

Dr. Jazmin Munoz
Gonzalez

INVOICE

11101

DATE

1/13/2026

- Jejunum: 2.20 mm (mucosa 1.04 mm, submucosa 0.73 mm, muscularis propria 0.43 mm).
- Ileum: 2.31 mm (mucosa 0.43 mm, submucosa 0.93 mm, muscularis propria 0.75 mm), with preserved wall layering.
- Ileocecal junction: wall thickness up to 4.56 mm, with relative muscularis prominence (muscularis up to 1.36 mm).
- Colon: wall thickness within normal limits (ascending colon 1.01 mm, transverse colon 1.04 mm, descending colon 0.90 mm), with formed fecal material in the descending segment.

Pancreas

The pancreas measures approximately 6.66–8.21 mm in thickness. The right limb, body, and left limb appear normal. The pancreatic parenchyma is isoechoic relative to adjacent omental fat. The pancreatic duct measures up to 1.29 mm. No sonographic evidence of active pancreatitis or pancreatic neoplasia is observed.

Free Abdomen

A small volume of anechoic abdominal effusion is present, localized to the splenorenal recess.

- Cranial mesenteric lymph nodes: mildly enlarged, measuring approximately 8.14–8.17 mm in thickness.
- Ileocecal lymph nodes: measure approximately 3.14–5.13 mm.

No peritoneal thickening, free gas, or signs of peritonitis are observed. The iliac trifurcation appears normal.

PRIMARY FINDINGS

- Mild ileal and ileocecal junction wall thickening with preserved layering and relative muscularis prominence.
- Mild enlargement of cranial mesenteric and ileocecal lymph nodes.
- Small volume anechoic abdominal effusion localized to the splenorenal recess.

SECONDARY FINDINGS

- Mild diffuse renal cortical hyperechogenicity with preserved corticomedullary definition.
- Turbid urine with suspended echoes, without evidence of cystitis or urolithiasis.

INTERPRETATION OF THE FINDINGS & FURTHER RECOMMENDATIONS

The ileum and ileocecal junction demonstrate mild wall thickening with preserved layering and relative prominence of the muscularis layer, most pronounced at the ileocecal junction. This pattern is commonly associated with chronic inflammatory enteropathy in cats, particularly lymphoplasmacytic inflammation, and likely reflects chronic muscularis hypertrophy secondary to longstanding intestinal inflammation. However, similar muscularis-predominant changes may also be observed in early or low-



PATIENT

Lulu Darcy

SPECIES

Feline

BREED

Domestic Longhair

SEX

Spayed Female

AGE

12 years

WEIGHT

6.94 lbs

INTERPRETED BY

Alicia Angosto
Guerrero, DMV,
PgDip, MSc.

IMAGING PERFORMED BY

Dr. Jazmin Munoz
Gonzalez

HOSPITAL NAME

Oakridge Veterinary
Clinic

REFERRING VET

Dr. Jazmin Munoz
Gonzalez

INVOICE

11101

DATE

1/13/2026

grade small-cell intestinal lymphoma, and definitive differentiation between these entities cannot be achieved based on ultrasonography alone due to significant overlap in imaging appearance.

The cranial mesenteric and ileocecal lymph nodes are mildly enlarged, maintaining relatively smooth margins and without marked heterogeneity. This nodal appearance is nonspecific and may be encountered in both reactive/inflammatory conditions and early lymphomatous involvement, further reinforcing the overlap between inflammatory and neoplastic processes in this case.

The abdominal effusion may be reactive or inflammatory in nature, potentially related to underlying gastrointestinal or hepatobiliary disease.

The liver appears subjectively normal in size and echotexture, without focal lesions or biliary obstruction. Given the markedly elevated ALT reported previously, the absence of significant ultrasonographic hepatic changes suggests a primarily hepatocellular process that may be metabolic, inflammatory, toxic, or secondary (related to chronic disease, weight loss, or medication), rather than structural or obstructive in nature.

The pancreas, where visualized, appears within normal limits, without peripancreatic inflammatory changes. However, as is common in cats, a normal or near-normal pancreatic appearance does not exclude chronic or intermittent pancreatitis.

The urinary bladder contains mildly turbid urine with suspended echoes, which may represent sediment or crystalluria; however, there is no sonographic evidence of cystitis. The kidneys show mild diffuse cortical hyperechogenicity with preserved corticomedullary definition, a finding that may be incidental or reflect early or chronic medical renal changes, particularly in older cats, and should be interpreted in conjunction with renal function parameters.

Recommendations

- Consider a complete feline gastrointestinal panel (including cobalamin, folate, fPLI, and TLI) if not already performed
- Intestinal biopsies would definitively differentiate chronic inflammatory enteropathy from early small-cell intestinal lymphoma.
- Medical management for chronic enteropathy (dietary modification ± anti-inflammatory therapy) may be appropriate, particularly given current resolution of diarrhea.
- Continued monitoring of liver enzymes and consideration of hepatoprotective therapy may be warranted, given the markedly elevated ALT in the absence of structural hepatic disease



PATIENT

Lulu Darcy

SPECIES

Feline

BREED

Domestic Longhair

SEX

Spayed Female

AGE

12 years

WEIGHT

6.94 lbs

INTERPRETED BY

Alicia Angosto
Guerrero, DMV,
PgDip, MSc.

**IMAGING
PERFORMED BY**

Dr. Jazmin Munoz
Gonzalez

HOSPITAL NAME

Oakridge Veterinary
Clinic

REFERRING VET

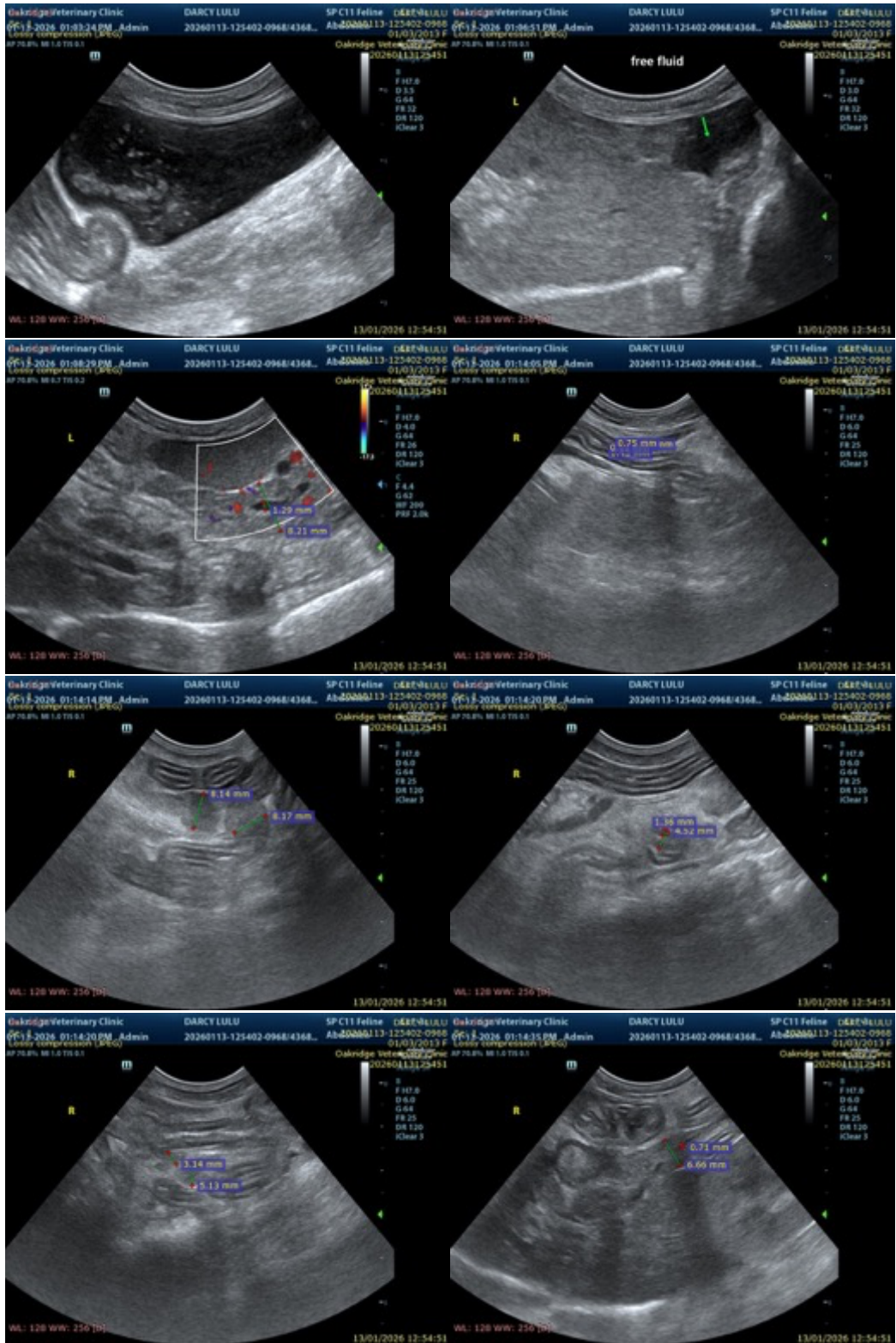
Dr. Jazmin Munoz
Gonzalez

INVOICE

11101

DATE

1/13/2026





PATIENT

Lulu Darcy

SPECIES

Feline

BREED

Domestic Longhair

SEX

Spayed Female

AGE

12 years

WEIGHT

6.94 lbs

INTERPRETED BY

Alicia Angosto
Guerrero, DMV,
PgDip, MSc.

IMAGING PERFORMED BY

Dr. Jazmin Munoz
Gonzalez

HOSPITAL NAME

Oakridge Veterinary
Clinic

REFERRING VET

Dr. Jazmin Munoz
Gonzalez

INVOICE

11101

DATE

1/13/2026

The information and recommendations provided are based on the images presented by the referring veterinarian/sonographer. No evaluation can be communicated regarding pathology that was not visible in the image/video clips provided.

Thank you for this referral. If the clinical or image interpretation does not parallel your findings or if I can be of any further assistance please contact me.

Alicia Angosto Guerrero, DMV, PgDip, MSc.

info@SonoPath.com