



PATIENT

Stella Goff

SPECIES

Feline

BREED

SEX

Spayed female

AGE

13 years

WEIGHT

10.9 lbs

INTERPRETED BY

Dr. Alicia Angosto
Guerrero

IMAGING PERFORMED BY

Amy Isaac

HOSPITAL NAME

Valley West & Elk
Valley VH

REFERRING VET

Dr. Isaac

INVOICE

70027

DATE

1/12/26

PRESENTING CLINICAL SIGNS

History: History of diabetes, on lantus 3 units BID. Presented to the emergency clinic over the weekend ADR with decreased appetite. HCT was 9% at that time and anemia was regenerative per E. Clinic labs. Transfusion performed at the emergency hospital. Pet was azotemic over the weekend as well but that appears to have resolved with hospitalization.

Abnormal PE/Chem/CBC/UA Results: Today Stella is still anorexic and her ALT is now 2100. Bacteruria. Mild hypokalemia. Appears tender on abdominal palpation. Currently on IV fluids with insulin administration per BG checks. On doxycycline from the emergency hospital. Starting other antibiotics due to bacteria in the urine and urine culture pending. Housemate is at another veterinary clinic with pleural effusion, unsure if the cases are related at all. Owner first said hemothorax, but unsure if the effusion was blood or not.

ULTRASONOGRAPHIC EXAMINATION OF THE ABDOMEN

Urinary System

The urinary bladder lumen is normally distended, and the urinary bladder wall appears thin and smooth. The urine is anechoic. The bladder neck and proximal urethra appear normal. No uroliths are identified, and there is no sonographic evidence of inflammatory or neoplastic changes.

The left kidney is normal in shape and size, measuring 3.46×2.57 cm, with a cortical thickness of 0.43 cm in the sagittal plane. The renal cortex is isoechoic relative to the liver parenchyma. The corticomedullary ratio is normal, and corticomedullary definition is preserved. Mild pyelectasia is noted (renal pelvic diameter approximately 2.61 mm), without evidence of nephrolithiasis or hydronephrosis.

The right kidney is normal in shape and size, measuring 3.84×2.36 cm, with a cortical thickness of 0.41 cm in the sagittal plane. The renal cortex is isoechoic relative to the liver parenchyma. The corticomedullary ratio is normal, and corticomedullary definition is preserved. Mild pyelectasia is noted (renal pelvic diameter 1.95 mm), without evidence of nephrolithiasis or hydronephrosis.

Adrenal Glands

The right adrenal gland measures approximately 0.35 cm at the cranial pole and 0.38 cm at the caudal pole. The left adrenal gland could not be reliably measured in the provided images.

Spleen

Splenic thickness measures 0.59 cm. The splenic parenchyma demonstrates normal echogenicity and a fine, homogeneous echotexture without focal parenchymal abnormalities. The splenic capsule is smooth and regular.



PATIENT

Stella Goff

SPECIES

Feline

BREED

SEX

Spayed female

AGE

13 years

WEIGHT

10.9 lbs

INTERPRETED BY

Dr. Alicia Angosto
Guerrero

IMAGING PERFORMED BY

Amy Isaac

HOSPITAL NAME

Valley West & Elk
Valley VH

REFERRING VET

Dr. Isaac

INVOICE

70027

DATE

1/12/26

Liver

The liver is subjectively enlarged, with rounded margins. The hepatic parenchyma appears homogeneous and markedly hyperechoic relative to the falciform fat, with preserved echotexture. No hepatic lymphadenopathy is observed.

The gallbladder lumen is normally distended. The gallbladder wall is thin, and the contents are anechoic with a mild to moderate amount of biliary sludge. No dilation of the cystic duct or common bile duct is observed.

Gastrointestinal

The stomach is empty and folded, with a mural thickness of approximately 1.33 mm and preserved wall layering. The pyloric wall measures approximately 3.16 mm.

Jejunal wall thickness ranges from approximately 2.30 to 2.73 mm, with preserved wall layering. Ileal wall thickness measures approximately 1.01 mm, with preserved layering. The ileocecal junction is not visualized. No sonographic signs of obstruction, ileus, or foreign material are identified.

The colonic wall measures approximately 0.66 mm in the transverse colon, with minimal content, and approximately 1.07 mm in the descending colon, which contains formed fecal material.

Pancreas

The right pancreatic limb measures approximately 6.40 mm, the pancreatic body 6.91 mm, and the left pancreatic limb 6.73 mm. The pancreatic contour appears irregular. The pancreatic parenchyma is hypoechoic relative to the adjacent omental fat. The pancreatic duct measures approximately 0.85 mm in diameter. No sonographic evidence of active peripancreatic fat inflammation is identified.

Peritoneal Cavity

No abdominal effusion or sonographic signs of peritonitis are observed. Cranial mesenteric and ileocecal lymph nodes are not visualized; however, the surrounding regions appear unremarkable. The iliac trifurcation appears normal.

ULTRASONOGRAPHIC FINDINGS

- Marked hepatomegaly with diffuse, homogeneous, markedly increased hepatic echogenicity.
- Pancreatic enlargement involving the right limb, body, and left limb, with irregular pancreatic contours. Diffuse pancreatic hypoechogenicity relative to adjacent omental fat.
- Mild bilateral renal pyelectasia without evidence of obstruction.
- Mild to moderated amount of biliary sludge in the gallbladder.



PATIENT

Stella Goff

SPECIES

Feline

BREED

SEX

Spayed female

AGE

13 years

WEIGHT

10.9 lbs

INTERPRETED BY

Dr. Alicia Angosto
Guerrero

IMAGING PERFORMED BY

Amy Isaac

HOSPITAL NAME

Valley West & Elk
Valley VH

REFERRING VET

Dr. Isaac

INVOICE

70027

DATE

1/12/26

INTERPRETATION OF THE FINDINGS & FURTHER RECOMMENDATIONS

Abdominal ultrasonography demonstrates marked hepatomegaly with rounded margins and diffuse, homogeneous, markedly increased hepatic echogenicity. In the context of extreme ALT elevation, anorexia, abdominal pain, diabetes mellitus, and recent severe regenerative anemia, these findings are most consistent with severe acute hepatocellular injury. Differential considerations include hepatocellular necrosis, metabolic or vacuolar hepatopathy, and hepatocellular injury secondary to systemic inflammatory or hypoxic events.

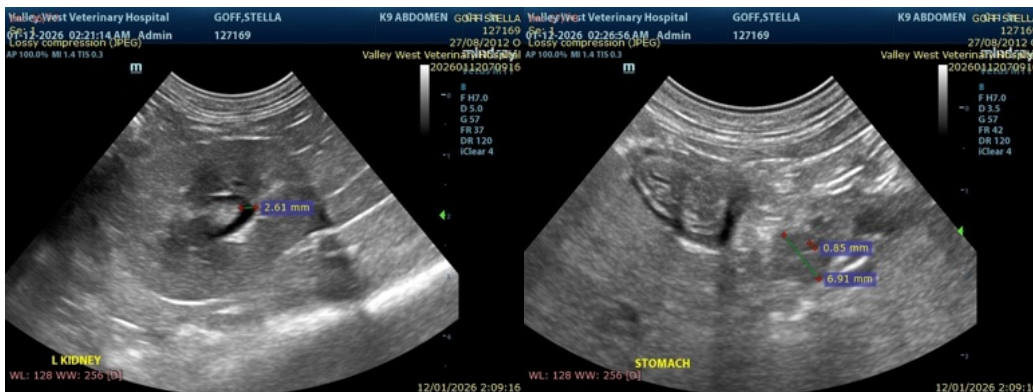The pancreas is diffusely enlarged with irregular margins and hypoechoic parenchyma, findings concerning for pancreatitis. In cats, pancreatitis may occur without marked peripancreatic fat reaction, and pancreatic disease may represent a primary process or a significant contributing factor to the hepatic changes observed.

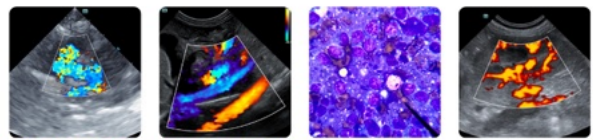
Mild bilateral renal pyelectasia is noted and is considered nonspecific, potentially related to fluid therapy, systemic illness, or lower urinary tract infection. No evidence of obstructive uropathy is identified.

Although no lymphadenopathy is present, diffuse infiltrative hepatic disease, including neoplasia, cannot be entirely excluded based on ultrasonographic findings alone; however, given the acute clinical presentation, marked biochemical derangements, homogeneous hepatic appearance, and concurrent pancreatic involvement, a primary infiltrative or neoplastic process is considered less likely at this time.

Recommendations

- Continued intensive supportive care is strongly recommended.
- Supportive management for suspected pancreatitis, including analgesia and antiemetics, is advised.
- Early nutritional support is strongly recommended to prevent secondary hepatic lipidosis.
- Coagulation parameters should be assessed given the severity of hepatic injury and recent anemia.
- Hepatic biopsy may not be advisable at this time given the patient's clinical instability.





PATIENT

Stella Goff

SPECIES

Feline

BREED

SEX

Spayed female

AGE

13 years

WEIGHT

10.9 lbs

INTERPRETED BY

Dr. Alicia Angosto Guerrero

IMAGING PERFORMED BY

Amy Isaac

HOSPITAL NAME

Valley West & Elk Valley VH

REFERRING VET

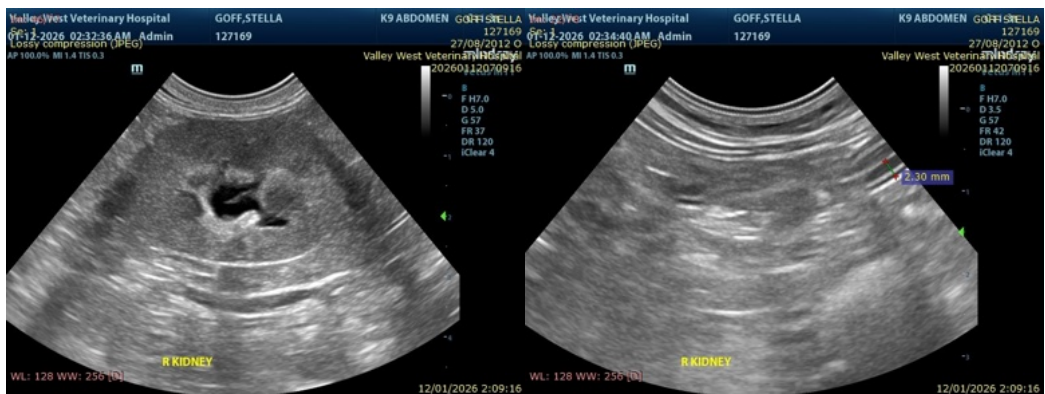
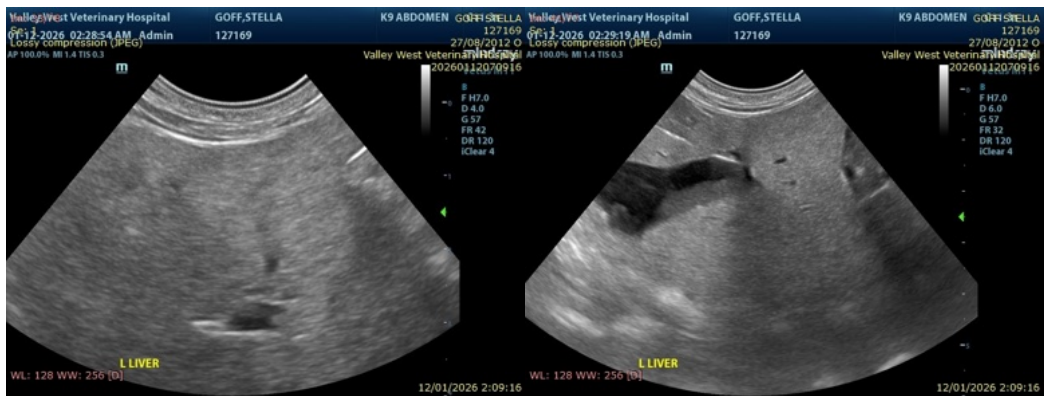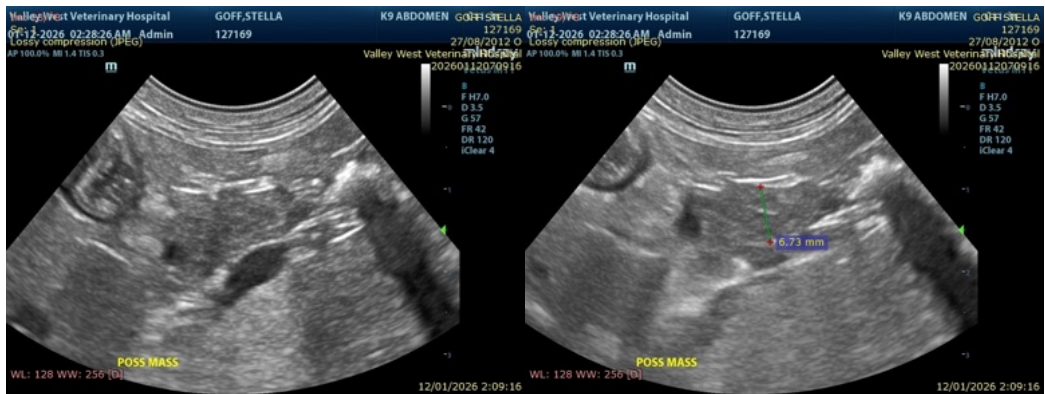
Dr. Isaac

INVOICE

70027

DATE

1/12/26



The information and recommendations provided are based on the images presented by the referring veterinarian/sonographer. No evaluation can be communicated regarding pathology that was not visible in the image/video clips provided.

Thank you for this referral. If the clinical or image interpretation does not parallel your findings or if I can be of any further assistance please contact me.

Alicia Angosto Guerrero, DMV, PgDip, MSc.

MV Esp Ultrasound in Domestic and Wild Animals

info@SonoPath.com