



DATE PRESENTING CLINICAL SIGNS

9/9/22

Presented for mass evaluation. Mass proximal, caudomedial thigh - approx 2 cm from prescrotal region. Owner interested in stelfonta

INTERPRETED BY

L.D. McGill, DVM,
Ph.D, DACVP

CYTOLOGY SUBMISSION

Skin mass

OBSERVATIONS

Skin mass: Submitted are large numbers of images of excellent collections of cells from the skin mass on Rascal. The cellularity is a characteristic proliferation of granulated cells. Granules are metachromatic to purple. These are mast cells and most of the cells are well granulated. A few cells are minimally granulated. There are few inflammatory cells.

PATIENT

Rascal Adair

INTERPRETATION OF THE FINDINGS & FURTHER RECOMMENDATIONS

Skin mass - Mast cell tumor (see comments)

SPECIES

Canine

COMMENTS

The cellularity is classical for a mast cell tumor. The cells are well granulated suggesting a low grade mast cell tumor. This easily could be low-grade to intermediate. If the mass is to be excised, then the margins do not have to be more than 1-2 cm wide. A guarded prognosis is warranted with all mast cell tumors. Aspiration of regional lymph nodes and even distal lymph nodes for metastatic sites. Evaluation of the liver and spleen for evidence of metastasis is encouraged.

BREED

Pit Mix

SEX

Male Neutered

AGE

5y

WEIGHT

53

HOSPITAL NAME

Torch Lake Veterinary
Clinic

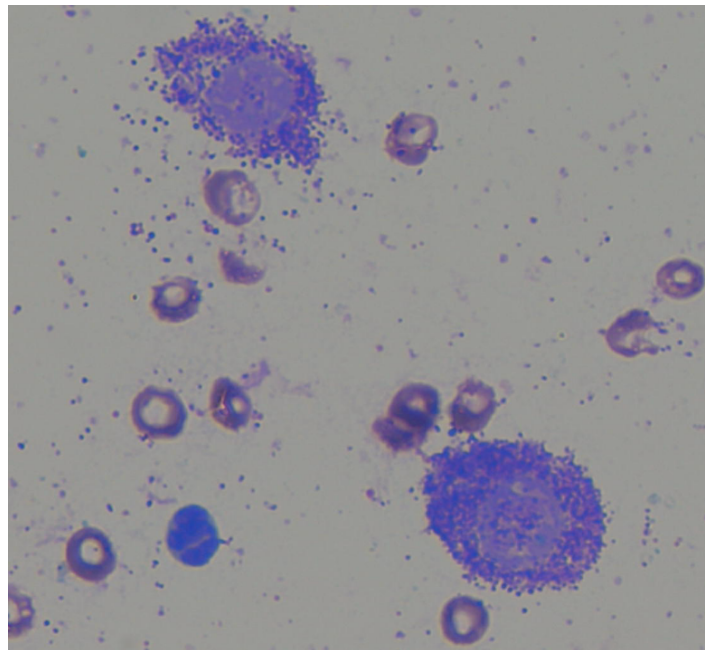


Image shows a couple of mast cells with inflammation collected from Rascal. The mast cells are well granulated.

REFERRING VET

Dr. Waffle

The information and recommendations provided are based on the images presented by the referring veterinarian. No evaluation can be communicated regarding pathology that was not visible in the image/video clips provided.

INVOICE NUMBER

790



DATE

9/9/22

Thank you for this referral. If the clinical or image interpretation does not parallel your findings or if I can be of any further assistance please contact me.

INTERPRETED BY

L.D. McGill, DVM,
Ph.D, DACVP

L.D. McGill, DVM, Ph.D., DACVP
8288 Top of the World Drive
Cottonwood Heights, UT 84121
ldmcgill.vetpath@gmail.com
cell: 801-865-1220

PATIENT

Rascal Adair

SPECIES

Canine

BREED

Pit Mix

SEX

Male Neutered

AGE

5y

WEIGHT

53

HOSPITAL NAME

Torch Lake Veterinary
Clinic

REFERRING VET

Dr. Waffle

INVOICE NUMBER

790